Neurological Surgery and Anatomy 2024, 1(1): 29-33, e-ISSN: 2966-0696
DOI: 10.37085/nsa.2024.7

Case Report

Incidental discovery of an azygos-type anterior cerebral artery in a cluster headache patient: a case report

Marcelo Moraes Valença[1], Martina Falcão Valença[2], Júlia dos Santos Monteiro[3], Carolina Martins[1], Laécio Leitão Batista[1]

[1]Federal University of Pernambuco, Recife, Pernambuco, Brazil
[2]Städtisches Klinikum Dresden, Dresden, Germany
[3]University of Pernambuco, Recife, Pernambuco, Brazil

Introduction
Intracranial arterial variations are prevalent and do not necessarily compromise cerebral blood flow. These variations, including the persistence of embryonic features like the fetal posterior cerebral artery pattern from the internal carotid artery, are commonly found during neuroradiological evaluation and noted in neurological assessments for symptoms like headaches and dizziness. Primary headaches such as cluster headache require differential diagnosis to exclude organic causes like parasellar lesions, which mimic their presentation. In this article, we aim to report a case of an adult patient who experienced a typical episode of cluster headache, and during the radiological investigation, we identified the presence of an azygos-type anterior cerebral artery (possibly unrelated to the trigeminal autonomic cephalalgia).
Case report
This article presents a case of a 73-year-old male experiencing severe, right-sided orbital-fronto-parietal headaches at age 45, diagnosed as cluster headaches. Accompanied by tearing and redness of the right eye, episodes lasted 30-60 minutes, and agitation. Despite the pain's intensity, oxygen therapy provided relief. Recent MRI scans, prompted by two months of dizziness, revealed an azygos anterior cerebral artery without other abnormalities, highlighting a rare anatomical variant.
Conclusion
In conclusion, we have presented a case involving a patient with a history of cluster headaches who, upon undergoing MRI evaluation, was discovered to have an azygos-type anterior cerebral artery. Considering the uncommon nature of this anatomical variation, we believe it is crucial to report and document this finding.

Keywords
Azygos ACA, Anterior cerebral artery, Cluster headache, MRI, Angiography, Pain.

Marcelo M. Valença
mmvalenca@yahoo.com.br

Submitted: March 22, 2024
Accepted: March 27, 2024
Published online: March 28, 2024

© Copyright 2024

Neurological Surgery and Anatomy

Introduction

Anatomical variations in intracranial arterial vessels are common, yet they do not necessarily lead to insufficient cerebral blood supply (1, 2). Several arterial variants are often encountered when investigating patients with neurological complaints (e.g., headache, dizziness, or focal neurological symptoms) (3-7). Many of these anatomical variations occur due to the persistence of embryonic vascular arrangements. The most common among these is the persistence of the fetal pattern of the posterior cerebral artery, which originates from the internal carotid artery (2, 4).

An intracranial arterial anatomical variation, first described in 1885 by Professor Wilder as the "arteria termatica," is very likely what is known today as the azygos anterior cerebral artery (ACA) (8). The literature indicates that an azygos ACA is found in 0.2-11.6% of individuals in large series of consecutive individual evaluations (3, 9, 10).

Besides, cluster headache is classified among primary headaches, but physicians are tasked with ruling out potential organic causes (e.g., parasellar lesions) that could present with a neurological picture identical to primary cluster headaches (11). We have previously published cases of cluster headaches secondary to the presence of internal carotid aneurysms in the proximity of the sella turcica (11).

The increased use of neuroimaging assessment in patients with neurological complaints has significantly raised the frequency of incidental findings of intracranial anomalies unrelated to the evaluated patient's symptoms. Establishing a causal relationship between the anomaly and the presented symptom is sometimes challenging (12, 13).

In this article, we aim to report a case of an adult patient who experienced a typical episode of cluster headache, and during the radiological investigation, we identified the presence of an azygos-type ACA (possibly unrelated to the trigeminal autonomic cephalalgia).

Case Report

A 73-year-old man with complaints of dizziness for the past two months and a history of experiencing a severe headache at the age of 45 was attended to in our outpatient unit. The headache, localized to the right orbito-fronto-parietal area, was associated with tearing and redness of the right eye during the episodes, which lasted 30-60 minutes. During these episodes, he became agitated and angry, with an urge to run and bang his head against a wall; these symptoms persisted for approximately ten weeks. He reported the pain as unbearable and the worst he had ever experienced in his life. He mentioned relief from the pain with oxygen therapy. At that time, he was diagnosed with cluster headache by a neurologist. A brain MRI was performed, which showed no abnormalities except for the presence of an azygos-type ACA (Figure 1). An MR angiography more clearly depicted the azygos-type ACA (Figure 2).

Discussion

The literature indicates that encountering an azygos ACA is rare (3, 5, 9, 10, 14). In this instance, the two A1 segments join near where the anterior communicating artery would be located, forming a single artery that ascends in the interhemispheric fissure. This type of anatomical variation is termed 'azygos,' meaning it occurs as a single unit rather than one of a pair, highlighting a biological structure without



Figure 1. The MRI of the brain reveals an azygos anterior cerebral artery. Left panel, coronal T2W. Observe that the azygos anterior cerebral artery (yellow arrow) bifurcates into distal pericallosal branches, as the arrowheads indicate. Right panel, axial T1W with intravenous Gd-contrast MRI of the brain reveals an azygos anterior cerebral artery, as indicated by the arrowhead.

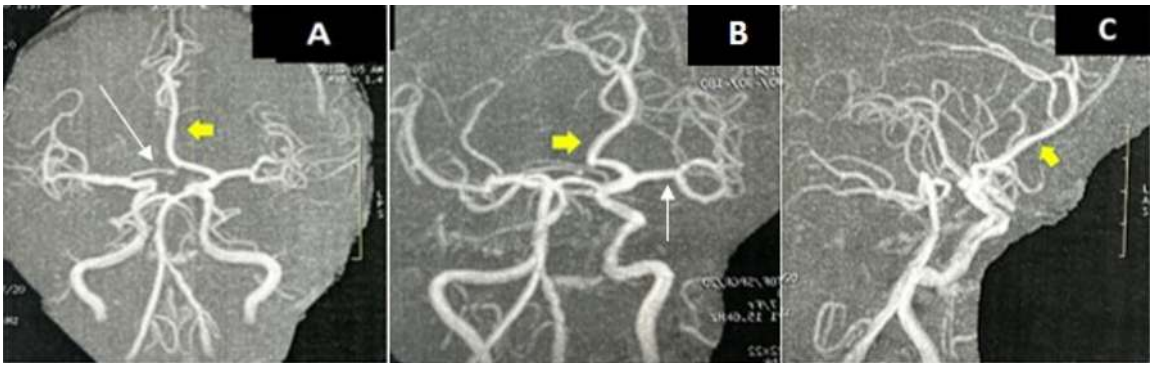

Figure 2. MR angiography more distinctly displays the azygos-type anterior cerebral artery, marked by short yellow arrows. The images are showcased from three angles: A, frontal; B, oblique; and C, lateral view. Pay attention to the hypoplastic right A1 segment (A) and an early bifurcation of the left middle cerebral artery (B), highlighted by white arrows.

a counterpart. The term 'azygos' is derived from Greek, meaning 'without a pair,' which aptly describes its uniqueness by not having a similar anatomical structure on the other side (15).

Paraskevas and colleagues (15), after reviewing medical literature spanning the last two millennia, stated that Galen, in his work titled "Hippocrates De acutorum morborum victu liber et Galeni commentarius," was the first to use the term "ἄζυγος φλέψ" (azygos vein) in the literature. However, he did not employ it as an official anatomical term but rather as an adjective describing a vein, indicating the absence of a similar paired vein on the left side.

The formation of the azygos artery is thought to occur during embryonic development through the fusion of the A2 segments (16). This process may originate from the medial branch of the olfactory artery around the embryonic stage of 16 mm (about 40 days into gestation) or the expansion of the median artery within the corpus callosum at the 20–24 mm stage. According to Baptista's classification (17), three types of modified courses for the A2 segment of the ACA have been identified: Type 1, unpaired; Type 2, bihemispheric; and Type 3, triplicated. Type 1 when there is a single, unpaired ACA. In this scenario, the unilateral ACA tends to be enlarged, and the contralateral A1 segment is hypoplastic, as observed in our patient. The bihemispheric pattern initially demonstrates a typical bilateral ACA configuration, where from the A2 segment, one side furnishes the medial portions of both hemispheres with pericallosal branches. The unpaired arrangement represents the azygos-type ACA and is categorized as a single, unpaired ACA, being a rare occurrence (1-4%). Conversely, the opposite ACA-A2 segment solely serves the callosomarginal group of arteries, and its pericallosal branch is absent. Type 2 is defined by the presence of ACAs serving both hemispheres, with one dominating and supplying both sides. The occurrence of type 2 is estimated to be between 2% and 7%, and it is differentiated from the azygos ACA by a less developed A2 segment. Type 3 is characterized by an additional ACA (e.g., median artery) originating from the anterior communicating artery. This variation is distinguished by three A2 segments branching out from the anterior communicating artery, and its occurrence is estimated to range from 2% to 13%. Such anatomical variations may be attributed to the retention or enlargement of the median callosal artery (17). This triplicated ACA features an additional medial branch originating from the anterior communicating artery that variably supplies the callosal territory. This variant is sometimes called the median callosal artery or accessory ACA. Such anatomical variations are likely due to the partial or complete fusion of pericallosal arteries during the embryonic period. This triplicated ACA can range in length; it may be short, confined to the lamina terminalis, chiasm, and paraolfactory area, or it may extend further to the splenium of the corpus callosum or even more expansively to cover both hemispheres up to the parietal lobes medially. In its most extended form, it is known as the median artery of the corpus callosum (17, 18).

In cases featuring an azygos-type ACA, an actual anterior communicating artery is absent, which is a common site for developing saccular aneurysms in individuals without this variation. Instead, the distal portion of the azygos ACA becomes a novel potential site for aneurysm formation. This predisposition towards aneurysm development can be attributed to the increased shear stress and hemodynamic pressure exerted on the artery's bifurcation beneath the level of the cerebral falx, where it divides into distal cerebral branches (19). Clinically, occlusion (via embolism) and narrowing (due to atherosclerosis or vasospasm) of this solitary artery could lead to more severe ischemia in both frontal lobes than typically anticipated.

Gunnal and coworkers (10) examined 112 formalin-preserved brains and found 13 (11.6%) azygos ACAs, classifying the azygos ACAs into five distinct types based on their anatomical characteristics and branching patterns:

Type I—The Classical Azygos ACA: Observed in the anterior median cerebral fissure, this type nourishes both cerebral hemispheres through its bilateral branches. It was identified in 3/112 cases (2.7%).

Type II—The Short Median Stem Variant: This variant features a brief median stem that bifurcates into branches supplying both hemispheres independently. It was found in 2/112 cases (1.8%).

Type III—The Asymmetric Branching Variant: This variant is characterized by two A2 segments, one markedly shorter and with minimal branching, while the counterpart is larger, dominant, and extends an azygos course with branches to both hemispheres. This variant was present in 4/112 cases (3.6%).

Type IV—The Azygos Pericallosal Artery Variant: This variant exhibits normal anterior circulation with the exception of the pericallosal arteries. Here, both pericallosal arteries are terminal branches of a single A2, with the opposite A2 terminating as the callosomarginal artery.

Type V—The Third Azygos Median A2 Artery Variant: This variant demonstrates a third median azygos A2 artery, documented in 1/112 cases (0.9%).

Gunnal and coworkers (10) have offered a thorough classification of ACA variations, enriching our understanding significantly. Their categorization, where Types I and II correspond to Baptista's definition of azygos ACA (17), and Types III and IV encapsulate bihemispheric ACA configurations, is meticulously detailed. Additionally, Type V is identified as either an accessory ACA or a triple ACA, broadening the spectrum of recognized variations. This systematic classification deepens our comprehension of cerebral vascular anatomy and serves as an essential reference for guiding clinical interventions and surgical planning.

In 2020, Beyhan and colleagues (16) introduced a new classification for the azygos ACA into four distinct types (A, B, C, and D), focusing on the anatomical localization of its branching:

- Type A: Branching occurs at the roof of the A2 segment.
- Type B: Branching takes place at the level of the corpus callosum.
- Type C: Branching is situated between the corpus callosum's genu and the body's middle level.
- Type D: Branching occurs beyond the middle level of the corpus callosum body.

It is well-documented that an azygos artery frequently occurs alongside other central nervous system malformations. These include but are not limited to, porencephalic cysts, agenesis of the corpus callosum, hydranencephaly, saccular aneurysms, and arteriovenous malformations (20). Notably, individuals with an azygos ACA tend to have a higher incidence of aneurysms within the intracranial arteries—at a rate of 12.28%—significantly above that observed in the more general population (16).

Interestingly, the incidental discovery of an azygos ACA bears similarity to anatomical features observed in lower primates (8, 21).

In conclusion, we presented a case of a patient with a history of cluster headache who, during an MRI evaluation, was found to have an azygos-type of ACA. Given the relative rarity of this anatomical variation, we deemed it important to document this finding.

References

1. Gunnal SA, Farooqui MS, Wabale RN. Study of Middle Cerebral Artery in Human Cadaveric Brain. Ann Indian Acad Neurol. 2019;22(2):187-94. Doi 10.4103/0972-2327.144289
2. Gunnal SA, Farooqui MS, Wabale RN. Study of Posterior Cerebral Artery in Human Cadaveric Brain. *Anat Res Int.* 2015;2015:681903. Doi 10.1155/2015/681903
3. Niederberger E, Gauvrit JY, Morandi X, Carsin-Nicol B, Gauthier T, Ferre JC. Anatomic variants of the anterior part of the cerebral arterial circle at multidetector computed tomography angiography. *J Neuroradiol*. 2010;37(3):139-47. Doi 10.1016/j.neurad.2009.12.004
4. Silva Neto AR, Camara RL, Valenca MM. Carotid siphon geometry and variants of the circle of Willis in the origin of carotid aneurysms. *Arq Neuropsiquiatr*. 2012;70(12):917-21. Doi 10.1590/s0004-282x2012001200003
5. Yokus A, Toprak N, Gunduz AM, Akdeniz H, Akdemir Z, Dundar I, et al. Anterior Cerebral Artery and Anterior Communicating Artery Variations: Assessment with Magnetic Resonance Angiography. *World Neurosurg*. 2021;155:e203-e9. Doi 10.1016/j.wneu.2021.08.027
6. Medrano-Martorell S, Pumar-Perez M, Gonzalez-Ortiz S, Capellades-Font J. A review of the anatomy of the middle cerebral artery for the era of thrombectomy: A radiologic tool based on CT angiography and perfusion CT. *Radiologia (Engl Ed)*. 2021;63(6):505-11. Doi 10.1016/j.rxeng.2021.10.004
7. Grand W. Microsurgical anatomy of the proximal middle cerebral artery and the internal carotid artery bifurcation. *Neurosurgery*. 1980;7(3):215-8. Doi 10.1227/00006123-198009000-00002
8. Blackburn IW. On the median anterior cerebral artery as found among the insane. *Journal of Comparative Neurology and Psychology.* 1910;20(3):185-94.
9. The Azygos Anterior Cerebral Artery [Radiology Key]. Available from: https://radiologykey.com/12-the-azygos-anterior-cerebral-artery/#:~:text=Embryologically%2C%20the%20azygos%20vessel%20appears,20%E2%80%9324%2Dmm%20stage.
10. Gunnal SA, Wabale RN, Farooqui MS. Variations of anterior cerebral artery in human cadavers. *Neurolology Asia.* 2013;18(3):249 – 59.
11. Valenca MM, Andrade-Valenca LP, Martins C, de Fatima Vasco Aragao M, Batista LL, Peres MF, et al. Cluster headache and intracranial aneurysm. *J Headache Pain*. 2007;8(5):277-82. Doi 10.1007/s10194-007-0412-9
12. Valença MM, Silva AHTTd, Mendes RFdA, Andrade PHPd, Silva UAVd, Carvalho DEd, et al. Incidental intracranial saccular aneurysm in a patient with post-Covid-19 headache:

What to do with the incidentaloma? *Headache Medicine.* 2021;12(1):64-8. Doi 10.48208/HeadacheMed.2021.13

13. Mesquita Sousa Santos PE, Gabriela Figueiredo P, Juliana A. Vertebral artery hypoplasia and chronic migraine: is there an association or just an incidental finding? *Headache Medicine.* 2021;12(2):148-51. Doi 10.48208/HeadacheMed.2021.27
14. Sibiya G, Omotoso BR, Harrichandparsad R, Lazarus L. Exploring the anatomical configurations of the cerebral arteries in a cohort of South African patients. *Sci Rep.* 2024;14(1):6060. Doi 10.1038/s41598-024-56767-y
15. Paraskevas GK, Koutsouflianiotis KN, Patsikas M, Noussios G. What is the history of the term "azygos vein" in the anatomical terminology? *Surg Radiol Anat.* 2019;41(10):1155-62. Doi 10.1007/s00276-019-02238-3
16. Beyhan M, Gokce E, Karakus K. Radiological classification of azygos anterior cerebral artery and evaluation of the accompanying vascular anomalies. *Surg Radiol Anat.* 2020;42(11):1345-54. Doi 10.1007/s00276-020-02509-4
17. Baptista AG. Studies on the Arteries of the Brain. Ii. The Anterior Cerebral Artery: Some Anatomic Features and Their Clinical Implications. *Neurology*. 1963;13:825-35. Doi 10.1212/wnl.13.10.825
18. Perlmutter D, Rhoton AL, Jr. Microsurgical anatomy of the distal anterior cerebral artery. *J Neurosurg*. 1978;49(2):204-28. Doi 10.3171/jns.1978.49.2.0204
19. Binatli O, Ozer F, Aydin M, Cicek E, Binatli Y. Azygos anterior cerebral artery aneurysm with concomittant vascular anomaly: case report. *World J Neurosci* 2013;3:49-51. Doi 10.4236/wjns.2013.31006
20. Singh H, Dhandapani S, Mathuriya SN. Types of Azygos Distal Anterior Cerebral Artery Branching Patterns: Relevance in Aneurysmal Surgery. *Cureus*. 2016;8(7):e681. Doi 10.7759/cureus.681
21. Watts JW. A Comparative Study of the Anterior Cerebral Artery and the Circle of Willis in Primates. *J Anat*. 1934;68(Pt 4):534-50.

The patient has granted permission to publish his case along with the images.

Marcelo Moraes Valença
https://orcid.org/0000-0003-0678-3782
Martina Falcão Valença
https://orcid.org/0000-0002-4085-3118
Júlia dos Santos Monteiro
http://orcid.org/0009-0003-7187-8267
Carolina Martins
https://orcid.org/0000-0002-0197-3520
Laécio Leitão Batista
https://orcid.org/0000-0001-5081-2689

Author's contribution: The authors contributed in the same way.

Conflict of interest: None of the authors have any conflict of interest for this article.

Funding: None.