Neurological Surgery and Anatomy 2026, 3(1): 24-32, e-ISSN: 2966-0696
DOI: 10.37085/nsa.2026.5

Review

Cornucopia: a mythological landmark in the posterior fossa

Carolina Martins[1,2], Guilherme Cristiano Garcia[3], Florisvaldo José Morais Vasconcelos Junior[1], Isaías Henrique Martins de Vasconcelos Norte Bezerra[3], Marcelo Moraes Valença[1], Antonio Cavalcanti de Albuquerque Martins[2,4]

[1]Federal University of Pernambuco, Recife, Pernambuco, Brazil
[2]Pernambuco School of Health, Recife, Pernambuco, Brazil
[3]University of Pernambuco, Recife, Pernambuco, Brazil
[4]Prof. Fernando Figueira Institute of Integrative Medicine, Recife, Pernambuco, Brazil

Edited by:
Wen Hung Tzu

Abstract

Introduction
The term cornucopia has been used anatomically to describe the area around the lateral recess of the fourth ventricle. First proposed by Vincent Bochdalek in 1849, the name reflects the resemblance of the rhomboid lip to a horn and the choroid plexus protruding through the foramen of Luschka to its contents. While widely adopted in Central European anatomical tradition, the term remains little known elsewhere. This study revisits the mythological and anatomical origins of the term and explores its relevance in microneurosurgical anatomy.

Objective
To investigate the historical, mythological, and anatomical foundations of the term cornucopia and assess its applicability as a microsurgical landmark in the posterior fossa.

Methods
A review of classical mythology, historical anatomical literature, and modern microsurgical dissections was performed. Comparative analysis of cadaveric specimens and microsurgical and endoscopic views of the cerebellopontine angle was undertaken to correlate the dual components of the cornucopia — the rhomboid lip ("horn") and extraventricular choroid plexus ("fruit") —, with surgical perspectives.

Results
The cornucopia represents a compound landmark that results from the combination of two anatomical structures recognizable in their own right. Because its appearance varies with surgical angle: antero-lateral views highlight the choroid plexus (fruit), while postero-lateral approaches reveal the rhomboid lip (horn) this combination provides for enhanced orientation that might be meaningful during retrosigmoid, telovelar, and endoscopic-assisted approaches to the cerebellopontine angle.

Conclusion
The cornucopia, rooted in mythology and introduced by Bochdalek, remains a useful anatomical landmark. Its dual composition offers abundant guidance in posterior fossa surgery.

Keywords: Human anatomy, Choroid plexus, Fourth ventricle, Infratentorial cisterns

Carolina Martins
cmrecife@hotmail.com

Received: April 13, 2026
Revised: June 1st, 2026
Accepted: June 6, 2026

© Copyright 2025

Introduction

Anatomically, the term cornucopia has been used to refer to the area around the lateral recess of the fourth ventricle (1). Bochdalek, in 1849 (2), was the first to propose this name because of the resemblance of the rhomboid lip to the horn, and the choroid plexus — protruding from the foramen of Luschka —, to the contents of the mythological cornucopia or horn of plenty. The term was later adopted in comparative anatomical studies to refer to the choroid plexus protruding from the lateral recess in the cat's fetal and adult brain (3), and has since been used to the human equivalent structure (4,5), being well-known in some fields (i.e. Imagiology) (6) and is routinely used in anatomy schools following the Central European tradition (7). However, the term is virtually unknown in other contexts (8–10), and its suitability and relevance have been called into question (11). This study investigates the origin of the term "cornucopia", its relationships with the anatomical structures in question and its applications in microneurosurgical anatomy.

Mythological origins of the term "cornucopia"

The term "cornucopia"— also known as "Füllhorn" or "horn of plenty"—, is ancient and appears, in one form or another, across many civilizations and traditions. While it can be clearly traced to the Hellenistic tradition, from which it spread widely, it may also have been absorbed from older, syncretic influences.

According to some sources (12,13), the origin of the horn of plenty is linked to the birth of Zeus (Jupiter) (Figure 1). Zeus's mother, Rhea (Ops), to protect him from his father Chronos (Saturn), hid the divine baby into a cave in Crete (12). The child was nursed by local nymphs (14) among them, Melissa and Amalthea. Melissa fed him with honey, while Amalthea, Amalthea gave him goat milk in a horn.



Figure 1. The myth of the cornucopia as related to the baby Zeus. A. A mural painted by Schinkel at the Throne Room, in Berlin, in 1781 (15), illustrates the myth of Rhea (Ops) and Chronos (Saturn). According to the myth, Chronos is terrified of his descendance, which — a prophecy has —, will dethrone him. Because of that he has ordered his wife Rhea (note Rhea's right feet being stepped over by Chronos) to hand him all his newborns. By this point, Chronos has already swollen five of his sons and daughters. But, this time, Rhea hands him instead, a wrapped stone and hides her newborn son Zeus (Jupiter) on the isle of Crete. B. Poussin's (1636) depiction of the myth of the baby Zeus (16). Hidden in Crete, the child was nursed by nymphs among them, Melissa (a), and Amalthea (b). Melissa (whose name's means "bee" and can be seen collecting honey from a beehive in the nearby tree) fed him with honey, while Amalthea, not only gave him goat milk, but also - in order to protect the baby, hung his cradle in a branch of a tree, so that Chronos could not find Zeus on earth, in the sky or in the sea. Besides, to prevent Chronos from hearing the baby crying, Amalthea gave bronze spears and shields to the boys, sons of the nymphs, the Kouretes (Curetes) (c), and ordered them to dance noisily around the cradle. The Minoan Crete is associated with the worship of Velchano, the god of fire, possibly later mistakenly confused by the romans with Vulcano. C. Frieze. Goat Amalthea nursing infant Zeus (17) Amalthea is depicted as a nymph or as a goat. In one version (13) for the origin of the horn of plenty or cornucopia, Zeus broke Amalthea's horn. To compensate his nurses, the divine baby attributed to Amalthea's horn the power to fill itself endlessly with whichever its holder desired — therefore —, horn of plenty. D. The Kouretes (meaning "youth or young boys") are sometimes depicted as young armed man dancing around the baby Zeus, but this is possibly another fusion with the Velchano's legend, who is not only the god of fire, but also of the initiation of the young. Legend most frequently has that the Crete's nymphs had ten children, five boys and five girls, also called "dactilos" (18) — from which the anatomical term for the hand fingers arise. Besides, the "Kouretes" —, or curetes, have long been introduced as surgical instruments (long and thin, well-resembling spears) and the microsurgical curetes, for this matter, are a well-known Rhotonian contribution to the neurosurgical armamentarium (see Insert) (19). Insert: Rhoton microneurosurgical set of curetes (19).

In one version (13) for the origin of the horn of plenty, Zeus broke Amalthea's horn (Figure 1B-C). To compensate his nurses, the divine baby attributed to Amalthea's horn the power to fill itself endlessly with whichever its holder desired.

According to other sources (12,13,20), cornucopia is linked to the hero, Herakles (Hercules) (Figure 2). During his fight with the shapeshifting, river-god, Acheeloo (Achelous) for the hand of Deianeira, Herakles broke Acheeloo´s horn (20), at the exact moment the river-god shifted to the form of a bull (13).



Figure 2. The cornucopia and its relation to the myth of Herakles (Hercules). A. A Greek hydria. Circa 500-510BC (21). Insert shows the hydria's colors. Yellow rectangle is the area enlarged in B. B. Enlarged view of the hydria's body: Contest of Herakles (Hercules) with the shape-shifting, river god Acheeloo (Achelous): In the center, to the right, is Herakles, with lion's skin over short embroidered chiton, quiver and sword; he seizes Acheeloo by the horn and plants the left foot on his right flank. Acheeloo is represented with human head and body united at the waist to a bull's body, with bull's horns and ears, long beard and tresses. Before him are Deianeira to left and Hermes (Mercury) to right, side by side; the former has long hair, and her right hand is raised to her mouth; the latter is bearded, with long tresses and caduceus. Behind Deianeira is her father Oineus (Oeneus). Behind Herakles stands Athene (Minerva) to right, with left hand raised, long tresses, high-crested helmet with cheek-pieces, aegis, and spear; by her side her shield, on which is a pellet. Behind her stands Iolaos (Iolaus), bearded, in visored helmet, holding a spear. C. A 1589 paper print from an engraving by Goltzius H. (22) “The Great Hercules” or “Knollenman” (bulbous man) is excessively muscled and wears a lion's pelt; he holds a massive club over his shoulder and a bull's horn in his right hand. To his right, in the landscape beyond, scenes related to him defeating Acheeloo and to the subsequent exchange of the Acheeloo horn by the cornucopia. The yellow rectangle shows the area enlarged in D. D. Enlarged view of the area signaled in C. Hercules overwhelms Acheeloo — in the form of a bull, using his both hands (on Acheeloo's horns) and feet (like in the Greek hydria shown in A). Further beyond, three naiads (daughters of Acheeloo) fill a cornucopia (22).

According to Bulfinch (13), the naiads, nymphs of fountains and rivers — probably here the daughters of Acheeloo (12) —, recovered the river-god's horn and filled it with flowers, while Tyche (Fortuna — for the Romans (23), one of the river-god´s numerous sisters), named it cornucopia. This legend may in fact be figurative to reflect the abundance resulting from crops following the "taming" of a large river (13), and in this sense have parallels with the Sumerian iconography of the "flowing vessel" (23), as well as the divine favor required for success in any human endeavor.

Still, to others (14,20), the two versions are linked, because to recover his horn, the river-god presented to Herakles, in exchange, Amalthea's horn (12), being this, is in fact, the one horn represented with the hero in many works of art (Figure 2E-G).



Figure 2 (Continuation). E. Enlarged view of a tiny bronze figure of Herakles (Hercules) with horn and club (24). The consistent representation of particular body features and accompanying objects is what allows for recognition of the mythological figure being represented (this tradition survives and is easily recognized contemporarily in the catholic saints and martyrs). F. Tyche (Fortuna) is the goddess of fate (25). She is possibly the link between the myth of the Zeus and Hercules, regarding the cornucopia, as she is the sister of Acheeloo (Achelous). As the legend goes, once Herakles defeated Acheeloo (Achelous) and took his horn, he was offered to exchange it for the cornucopia. If one thinks this was not a reasonable exchange — the iconology is clear: when threatened for life or limb (in this case — horn) —, one surrenders all prospects of riches. G. Enlarged view of F. Tyche (Fortuna) is usually represented with her mural crown (symbolizing her role the guardian of a city's destiny — this crown survived as a well-known heraldic symbol in Europe). She holds a ship's rudder on one side (possibly broken here (check and compare with insert) — symbolizing her role is steering the individual's life) and the cornucopia and/or the baby Dis (Plutus), god of wealth, on the other (25). Insert: Bronze figurine of Tyche (Fortuna) (26).

The symbolism of the horn, its relationships with gods, heroes and kings, its meanings associated with abundancy of crops, riches, resources (Figure 3) can be found in the iconology of several civilizations (27), and can be the result of cross-over and syncretism (23). Amalthea's horn might be the prototype for a rhyton, a vessel which the drinker was expected to empty at once but was never able to do (20), being therefore linked to abundancy. The rhyton can be traced back to the Persian Achaemenid court as symbols of luxury, power and vast resources (28) and are known to have — again —, crossed over to Greece. It was during the 5th century that rhyta gradually incorporated an opening to allow the flow of wine, due to their progressively ritualistic uses and purity concerns (23). Rhyton and horns of plenty can be traced to the bronze age Etruscans, in accordance with Herodotus, who claims that these peoples came to the Italian peninsula from Asia Minor (27), and — as the clay livers crafted for divination (29,30), also represent an object with extensive East to West links.



Figure 3. The cornucopia as a universal symbol of abundance. It can be related by meaning or shape with several other objects. A. A "rhyton" or pourer was a typically Persian vessel. Conical, it was adorned with an animal-headed "protome" (a), with a pouring hole in its anterior end (b). Animal-shaped rhyta were common in Hittite and Assyrian cultures, in which vessels depicting fearsome animals bestowed power and strength to its user. Rhyton with forepart of a winged griffin, 500-400 BCE. Achaemenid, found at Altintepe, Türkiye (28,31). B. Marble frieze from the Nereid Monument depicting the Persian Prince Erbinna in festive mood. Circa 390-380 BCE. Lycian from Xantos, modern Türkiye (28). The rhyton was held in one hand (a) and paired with a bowl (b) on the other, which held the amount to the be drank at each time. Reclined on a "kline" (c) or posted bed (thus the origin of the anatomical term "clinoid"), noblemen were expected to dazzle their partisans by lifting the rhyton above their heads while making the wine flow from one to the other in an apparent endless flow. The shape of the rhyton and the abundance of wine that they entail recalls the horn of plenty or cornucopia. C. The Greeks assimilated – and adapted - many Persian symbols and traditions. The animal-shaped rhyton, receives a handle and is used at the rim, becoming an animal-faced mug. When brought to the lips, it transformed the partisan (or "symposiast") in a ram (or a donkey, a pig, or a bird — certainly for comic effect —, and in clear contrast to the aristocratic Persian display of "prowess") (28). D. Enlarged view of C. The use of this vessel is now for a more democratic, communal drinking-gathering, or "symposium," as depicted around its rim (D) (28). The cornucopia, if a cross-seed between these cultures might have followed other paths. E. Ptolemaic coin depicting the cornucopia, puts this iconology and its meaning in Egypt as early as the late second century BCE. It was minted during the reign of Arsinoe II, who was first queen of Thrace and Macedonia and later Queen of Egypt (277-270 BCE) alongside her brother-husband (32) E. The Jadeite Cabbage (33) resembles in shape the cornucopia, an as part of the dowry of Emperor Guangxu's consort, it is considered a symbol of fertility, which literally means "abundant, fruitful, or productive". In shape and meaning this might be considered a close example of a cornucopia's related iconology in Asia. F. Enlarged view of the leafy end of the Jadeite Cabbage. The grasshoppers (a locust and a katydid) and the many leaves are the main symbols of fertility and abundance. Jadeite Cabbage. Qing Dynasty. 19th C. National Museum of Taiwan (33).

H. In Europe — and subsequently the Americas —, the cornucopia symbolism spread following the Hellenistic revival that started during Renaissance. It became associated with fall and harvest festivals; and the use of baskets (in lieu of the mythological horn) to expose the abundant results of the crops during this time of the year is the link between the cornucopia and the flower basket so commonly gifted nowadays (34). A poster dated 12 October 1876, for the American Land Company, compares California to the "cornucopia of the world" with "room for millions" and "a climate for health and wealth" (35).

Anatomical origins of the term "cornucopia"

It was in an 1849 article (2) — not in his extensive manual on cerebellar anatomy published 16 years earlier (36) —, that Vincent Bochdalek described the cornucopia. In that article, he compared the rhomboid lip and the tuft of choroid plexus protruding from the lateral aperture of the fourth ventricle to a "basket of flowers" or a "cornucopia," possibly unaware that the former had, in meaning, become the modern equivalent of the mythological latter:

"Since this medullary lamina, together with the part of the Plexus choroideus quartus contained within it and projecting from its free anterior margin, resembles, viewed from below, a small, rounded basket of flowers or a cornucopia, would like to propose for this part of the brain the name "Blumenkörbchen" (basket of flowers) or "Füllhorn" (cornucopia)" (2).

Therefore, "cornucopia" is a combined landmark, formed by two parts which also have received different names. While the "fruit" of the Bochdalek's cornucopia (2) is the extraventricular choroid plexus of Duvernoy (5) and Rhoton (19), the anterior lingula with its free edge of Duvernoy is the rhomboid lip of Rhoton (19) and the "horn" of the cornucopia of Bochdalek (2,5). Barany (37) has emphasized this dual composition in his seminal study of this area. Grasping the dual composition of the cornucopia seems important to understand the angle in which it is seen. When seeing from an anterior or antero-lateral perspective, it is the "fruit" part – the extraventricular choroid plexus which is best seen. However, when looking from a postero-lateral perspective it is the "horn" – the rhomboid lip the part seen initially (Figure 5).

The cornucopia — as other anatomical landmarks in the cerebellopontine (CP) angle — may be hidden from view when treating large lesions in this region (38), but it may be a useful guide to neighboring structures within the area of the supraolivary fossette (39) whenever an exploration of the Obersteiner-Redlich zone of the cranial nerves (40) is required or an intraxial lesion is to be reached via the so-called "safe entry zones" to the lower brainstem (41–44).

Conclusion

Although "cornucopia" exists as an anatomical term, and therefore part of the broad anatomical terminology, it is not agreed upon as nomenclature. Therefore, "fruticulus" (or small bush) has been proposed as an alternate, more descriptive term and upheld as a candidate for this region (11). Contrarily to "cornucopia" — which uses a single term to refer to a compound landmark —, this designation encompasses primarily one component, thereby limiting the comprehension of the predominant component seen by various surgical perspectives. Moreover, the universality of the concept of cornucopia as proven in this paper is favorable to its broad use. As for its meaning, it is also kept in the domain of applied microneuroanatomy, as it might provide abundance of guidance during posterior fossa procedures in and around the CP angle.

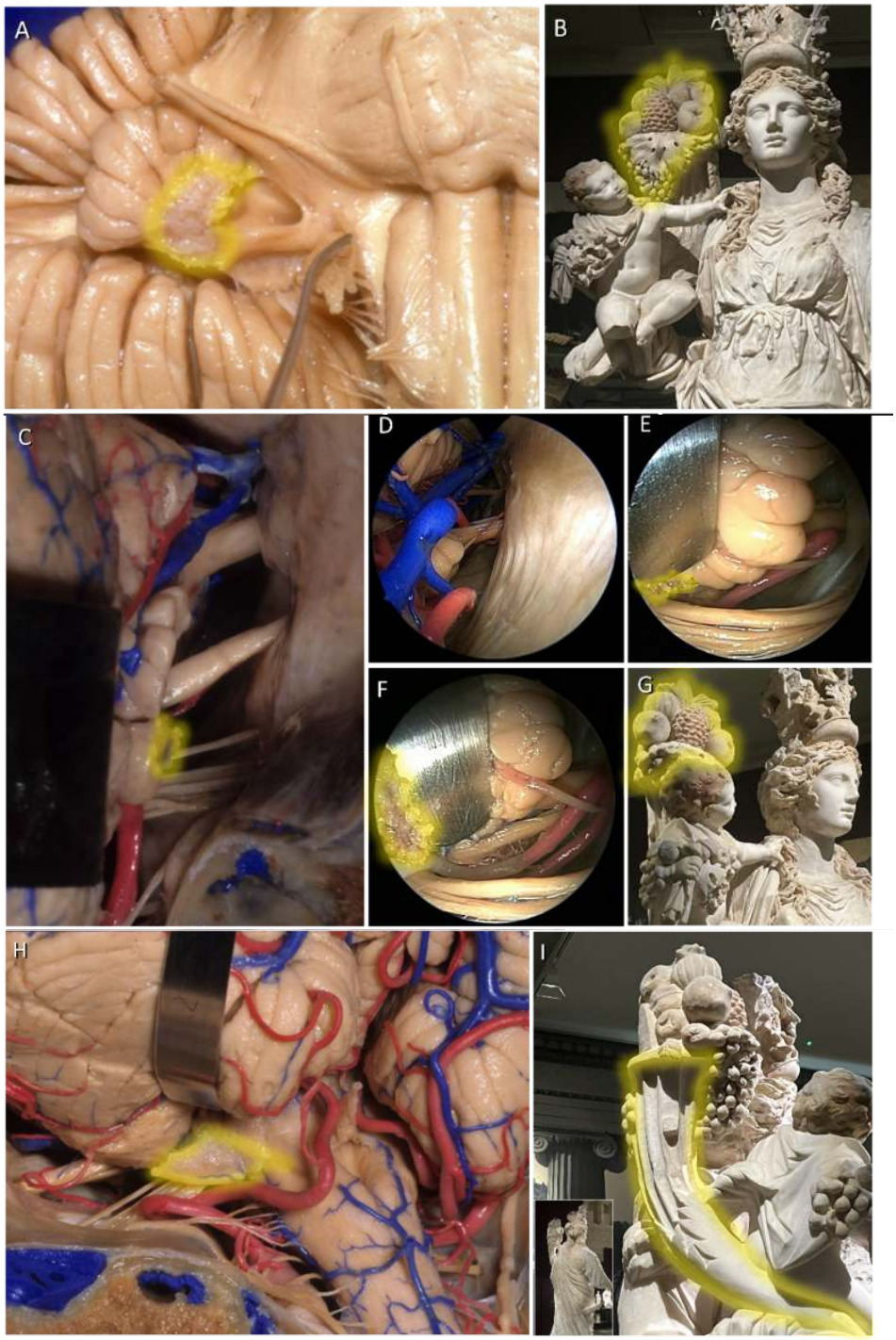

Figure 5. Cornucopia is a single term used to address two structures within the area of the opening of the lateral foramen of the IV ventricle, namely the choroid plexus (the "cornucopia's fruit") and the rhomboid lip or anterior lingula (the "cornucopia's horn"). The amount of each component seen depends on the perspective and angle in which this area is reached. The area around the lateral opening of the IV ventricle is seen from different perspectives in cadaveric specimens (A, C, D-F, H). Different perspectives of the cornucopia are seen around the marble Tyche statue (B, E, I). In all, the part of the cornucopia seen is outlined in yellow. A. Anterior, anatomical, view of the area of the right cerebello-pontine (CP) angle. The cornucopia is seen between the flocculus and the supraolivary fossette (also called lateral medullary fossa). B. Frontal view of the marble statue of Tyche. In A and B it is the "cornucopia's fruit" — the extraventricular choroid plexus (yellow outline) —, which is best seen from this view angle. C. The right CP angle is reached in an injected cadaveric human specimen with the help of the surgical microscope as in a retrosigmoid approach. D. The right CP angle is now explored with the help of the endoscope. E. The flocculus is located and elevated, simulating an infrafloccular endoscopic assisted approach to the CP angle. F. Through this route, elevating the "cornucopia's fruit" or extraventricular choroid plexus (outlined in yellow), allows the initial segment of VII and VIII complex to be exposed as well as the origin of the IX and X cranial nerves at the borders of the supraolivary fossette. G. Lateral view of Tyche´s statue, with the cornucopia´s fruit outlined in yellow. Like in a retrosigmoid approach, using the micro or endoscope, the tip of the extraventricular choroid plexus is the first part of the anatomical cornucopia to be seen, from a lateral perspective. H. Inferior view of the area of the lateral recess of the IV ventricle, obtained during simulation of a subtonsillar route in a telovelar approach. Now it is the rhomboid lip – the "cornucopia´s horn" (yellow outline), the part first seen; much like (I.) the view obtained of the cornucopia's horn (yellow outline) when the Tyche statue is seen from behind.

References

1. Mollison WM. Brain of a Patient Shown to the Section Last Year; The Patient Having Died Some Weeks after Operation. Proc R Soc Med 1915;8:5–7. Doi:10.1177/003591571500801102.
2. Bochdalek V. New Observations in the Field of Physiological Anatomy. Quarterly Journal for Practical Medicine 1849.
3. Thompson P. Description of a Model of the Brain of a Foetal Cat 20 mm. in Length. J Anat Physiol 1909;43:134–45.
4. Young A. The Cerebro-Spinal Circulation: With Particular Reference to the Rôle of Increased Cerebro-Spinal Pressure, in the Pathology and Symptomatology of Tumours and Certain Other Conditions of the Brain and Spinal Cord: Also a Description of Certain Special Methods of Investigation. Glasgow Med J 1929;112:121–43.
5. Duvernoy HM. The Human Brain Stem and Cerebellum. Vienna: Springer Vienna; 1995. Doi:10.1007/978-3-7091-3078-0.
6. Horsburgh A, Kirollos RW, Massoud TF. Bochdalek's flower basket: applied neuroimaging morphometry and variants of choroid plexus in the cerebellopontine angles. Neuroradiology 2012;54:1341–6. Doi:10.1007/s00234-012-1065-1.
7. Schunke M, Schulte E, Schumacher U. Prometeus, atlas de anatomia: cabeça e pescoço. Rio de Janeiro: Guanabara Koogan; 2007.
8. Susan Stranding, editor. Gray's anatomy: The Anatomical Basis of Clinical Practice. 39th ed. Elsevier Churchill Livingstone; 2005.
9. Gardner E, Gray DJ, O´Rahilly R. Anatomia: Estudo Regional do Corpo Humano. 4th ed. Rio de Janeiro: Guanabara Koogan; 1978.
10. Gray H. Anatomy: descriptive and surgical. London: Jonh W Parker and Son, West Strand; 1858.
11. Kachlík D, Musil V, Baca V. A plea for extension of the anatomical nomenclature. Part 1: Nervous system and senses. Folia Morphol (Warsz) 2017;76:168–77. Doi:10.5603/FM.a2016.0064.
12. Kerényi K. A mitologia dos gregos: A história dos deuses e dos homens. vol. 1. Editora Vozes; 2015.
13. Bulfinch T. Bulfinch's mythology. Canterbury Classics; 2014.
14. March JR. The Penguin book of classical myths. Penguin; 2009.
15. Schinkel KF. Throne Room, Cronos and Rhea 1827.
16. Poussin N. The Nurture of Jupiter. London: Dulwich Picture Gallery; 1636.
17. Unknown. The goat Amalthea nursing the infant Zeus. Turkey: Archeological Museum; n.d.
18. Harrison JE. Themis: A study of social origins of Greek religion. Cambridge: University Press; 1912.
19. Rhoton Junior AL. Rhoton cranial anatomy and surgical approaches. Philadelphia: Lippincott William & Wilkins; 2003.
20. Kerényi K. A mitologia dos gregos: A história dos heróis. vol. 2. Editora Vozes; 2015.
21. Unknown. Hydria, Attica. London: The British Museum; 520AD.
22. Goltzius H. The Great Hercules [engraving]. London: The British Museum; 1589.
23. Manassero N. Meanings of rhyta and meanings of Old Nisa. Traces of Empires: Ancient and Medieval culture of Central Asia, Moscow: n.d.
24. Unknown. Hercules Statuette [statuette]. London: The British Museum; 500AD.
25. Unknown. Marble Statue of Tyche (Fortuna) [sculpture]. Istanbul: Istanbul Archaeological Museums; 200AD.
26. Unknown. Bronze Figurine of Tyche (Fortuna) [sculpture]. Istanbul: Istanbul Archaeological Museums; 200AD.
27. Barelli A, Siggia E, editors. Etruschi in Europa. Roma: HISTORIA; 2010. 191p.
28. Fraser JA., Llewellyn-Jones Lloyd, Bishop-Wright HCosmo. Luxury and power: Persia to Greece. The British Museum Press; 2023.
29. Martins AC de A, Martins C. History of liver anatomy: Mesopotamian liver clay models. HPB 2013;15:322–3. Doi:10.1111/j.1477-2574.2012.00555.x.
30. Martins AC de A. Divination Through Hepatoscopy: The Apogee and Downfall of the Liver. Porto Alegre: Simplíssimo; 2024.
31. Unknown. Rhyton with Forepart of a Winged Griffin, Altintepe. London: The British Museum; 500AD.
32. Unknown. Ptolemy II [coin]. Istanbul: Istanbul Archaeological Museums; 277AD.
33. Unknown. Jadeite Cabbage [sculpture]. Taipei: National Palace Museum; 1887.
34. Impelluso L. Nature and its symbols. Los Angeles: J.P. Getty Museum; 2004.
35. Unknown. California Cornucopia of the World [poster]. New York: Granger Historical Picture Archive; 1876.
36. Bochdalek V. Anleitung zur praktischen Zergliederung des menschlichen Gehirnes. Prag: Gottlieb Haase Söhne; 1833.
37. Barany L, Baksa G, Patonay L, Ganslandt O, Buchfelder M, Kurucz P. Morphometry and microsurgical anatomy of Bochdalek's flower basket and the related structures of the cerebellopontine angle. Acta Neurochir (Wien) 2017;159:1539–45. Doi:10.1007/s00701-017-3234-9.
38. Campero A, Martins C, Rhoton A, Tatagiba M. Dural Landmark to Locate the Internal Auditory Canal in Large and Giant Vestibular Schwannomas: The Tübingen Line. Operative Neurosurgery 2011;69:99–102. Doi:10.1227/NEU.0b013e31821664c6.
39. Wen HT, Rhoton Junior AL, Mussi ACM. Surgical Anatomy of the Brain. Youmans & Winn Neurosurgery. 7th ed., Philadelphia: Elsevier; 2017, p. 49–75.
40. Alfieri A, Fleischhammer J, Strauss C, Peschke E. The central myelin–peripheral myelin transitional zone of the nervus intermedius and its implications for microsurgery in the cerebellopontine angle. Clinical Anatomy 2012;25:882–8. Doi:10.1002/ca.22025.
41. Cavalheiro S, Yagmurlu K, da Costa MDS, Nicácio JM, Rodrigues TP, Chaddad-Neto F, et al. Surgical approaches for brainstem tumors in pediatric patients. Child's Nervous System 2015;31:1815–40. Doi:10.1007/s00381-015-2799-y.
42. Cavalcanti DD, Preul MC, Kalani MYS, Spetzler RF. Microsurgical anatomy of safe entry zones to the brainstem. J Neurosurg 2016;124:1359–76. Doi:10.3171/2015.4.JNS141945.

43. Recalde RJ, Figueiredo EG, de Oliveira E. Microsurgical anatomy of the safe entry zones on the anterolateral brainstem related to surgical approaches to cavernous malformations. Operative Neurosurgery 2008;62:9–17. Doi:10.1227/01.neu.0000317368.69523.40.

44. Yagmurlu K, Rhoton AL, Tanriover N, Bennett JA. Three-Dimensional Microsurgical Anatomy and the Safe Entry Zones of the Brainstem. Operative Neurosurgery 2014;10:602–20. Doi:10.1227/NEU.0000000000000466.

Carolina Martins
https://orcid.org/0000-0002-0197-3520
Guilherme Cristiano Garcia
https://orcid.org/0000-0002-7647-3408
Florisvaldo José Morais Vasconcelos Junior
https://orcid.org/0009-0003-0605-1044
Isaías Henrique Martins de Vasconcelos Norte Bezerra
https://orcid.org/0009-0002-0102-0022
Antonio Cavalcanti de Albuquerque Martins
https://orcid.org/0000-0002-1249-8622
Marcelo Moraes Valença
https://orcid.org/0000-0003-0678-3782

Authors Contributions: CM: Conception, Figures; CM, GCC, FJVJr, IHMVNB: Data collection, Organization, Writing original draft; CM, ACAM, MMV: Reviewing material; ACAM, MMV: Supervised.
Conflict of interest: There are no conflicts of interest.
Funding: There was no funding.
Acknowledgments: We are grateful to the British Museum team, represented by Mr. Timothy Simon and Ms Claudia Pereira, for their guidance with archival research for this study.