Neurological Surgery and Anatomy 2026, 3(1): 6-9, e-ISSN: 2966-0696
DOI: 10.37085/nsa.2026.2

Neurological Surgery and Anatomy

History of medicine

Platinum jubilee of Klingler's *Atlas Cerebri Humani*

Antonio Cavalcanti de Albuquerque Martins[1,2], Carolina Martins[1,3]

[1]Medical School of Pernambuco, Recife, Pernambuco, Brazil
[2]Prof. Fernando Institute of Integrative Medicine, Recife, Pernambuco, Brazil
[3]Federal University of Pernambuco, Recife, Pernambuco, Brazil

Abstract

Introduction
Seventy years after its publication, Klingler's *Atlas Cerebri Humani* remains a landmark in neuroanatomy, transforming the study of white matter from schematic drawings into vivid, three-dimensional dissections.
Objective
To revisit the 1956 *Atlas Cerebri Humani* and describe its publication features and methodological innovations that established it as an enduring scientific and educational reference in neuroanatomy and neurosurgery.
Methods
Klingler pioneered the freezing dissection technique, fixing brains in formalin and freezing them to separate myelinated fibers. This approach allowed association, projection, and commissural pathways to be traced with unprecedented clarity. The technique produced prosections for macroscopic viewing, designed to help students at the Anatomical Institute of Basel grasp the brain's 3D organization after studying sectional anatomy. In 1938, Klingler published an atlas based on these dissections, but it quickly went out of print, and World War II halted further development.
Results
In 1956, Josef Klingler and Eugen Ludwig co-authored a multilingual atlas presenting "the inner structure of the brain demonstrated on the basis of macroscopic preparations." The work revealed the brain's organized network of fascicles and connections, anticipating modern connective perspectives and microsurgical fiber tract dissections that later refined this field. Its plates continue to be reproduced in neurosurgical and neuroanatomical education, and Klingler's dissections remain a standard for validating tractography.
Conclusion
Klingler's *Atlas Cerebri Humani* endures as both a historical milestone and a living reference, demonstrating that scientific rigor combined with aesthetic vision can reveal the brain's hidden architecture in ways that continue to shape contemporary practice.

Keywords: Brain, White matter, Fiber tracts, Dissection, History of medicine, Neurosurgery

Edited by:
Marcelo Moraes Valença

Carolina Martins,
cmrecife@hotmail.com

Received: April 7, 2026
Revised: April 28, 2026
Accepted: May 11, 2026

© Copyright 2025

Introduction

Seventy years after its publication, Joseph Klingler's *Atlas Cerebri Humani* (1) remains a landmark in neuroanatomy, transforming the study of white matter from schematic drawings into vivid, three-dimensional dissections. This paper revisits 1956 Klingler´s Atlas to describe its publication features and characteristics that made it an enduring scientific and educational reference in neuroanatomy and neurosurgery.

Historical background

In 1934-1936, Klingler pioneered the freezing dissection technique, fixing brains in formalin and freezing them to separate myelinated fibers which allowed association, projection, and commissural pathways to be followed with unprecedented clarity. Initially, the technique was used to provide prosections aimed at being viewed macroscopically. Their intent was to facilitate the mental task of students at the Anatomical Institute at the University of Basel in three-dimensionally understanding the inner structures of the brain, particularly after having studied its sectional anatomy (1). In 1938, an initial atlas was published with this material but was soon out of print and the outbreak of World War II prevented the continuation of this work.

In 1956, E. Ludwig and J. Klingler co-authored a pentalingual (German, English, French, Spanish and Latin) atlas. It proposed to present "the inner structure of the brain demonstrated on the basis of macroscopical preparations" (1) and revealed the brain's organized network of fascicles and connections, anticipating modern connective perspectives and the microsurgical fiber tract dissections that would latter refined this field (2–5). Its plates continue to be reproduced in neurosurgical and neuroanatomical education, and his dissections - achieved long before advanced imaging existed, remain standard for validating tractography (6).

Seventy years after its publication, *Atlas Cerebri Humani* by Joseph Klingler and Eugen Ludwig remains one of the most influential works in neuroanatomy. At a time when the understanding of white-matter architecture was limited to schematic drawings or coarse gross dissections, the atlas offered something radically different: a three-dimensionally hinted, almost tactile, visually coherent representation of the brain's fibre pathways. It did not merely illustrate anatomy — it revealed the brain as an organized network of fascicles and connections, anticipating by decades the modern connective perspective (Figure 1).

The authors

Joseph Klingler (1897–1962), a Swiss anatomist trained in Basel, devoted his career to understanding the structural logic of the human brain. His meticulous nature and artistic sensibility converged in a method that transformed neuroanatomical study: the freezing-dissection technique. Klingler discovered that by fixing the brain in formalin and then freezing it at very low temperatures, the expansion of water within the tissue gently separated myelinated fibers. Once thawed, these fibers could be teased apart with unprecedented clarity, allowing major association, projection, and commissural pathways to be followed over long distances (1,2). Although the prosections were meant to be seen macroscopically, the preparations were accomplished under magnification of loupes. This approach produced dissections of remarkable elegance — clean, layered, and spatially coherent — enabling students and surgeons to visualize the brain's internal architecture in a way that had never been possible. He was 68 years old when the 1956 Atlas of Cerebri Anatomy was published - the same year he eventually retired from the Anatomy Institute at the University of Basel (6).

Klingler's technique was not merely a technical innovation; it reshaped the conceptual landscape of neuroanatomy. Many of the fibre systems he exposed — such as the superior longitudinal fasciculus, the uncinate fasciculus, and the cingulum — are central to neurosurgical planning, tractography validation, and functional network models (3,5). Modern diffusion MRI, despite its sophistication, still relies on Klingler's dissections as a standard for anatomical truth (6).

Eugen Ludwig was a prominent Morphologist and served as Professor of Anatomy at the Anatomy Institute at the University of Basel from 1913 to 1922. He became Associate professor from 1922, and eventually Full Professor and holder of the Chair of Normal Anatomy in Basel from 1929 to 1955 and is listed at the University of Basel website for his work as Rector, in 1941 (7). Ludwig appointed Klingler "Anatomical Preparator" or "Lab Technician" in 1929, and after Klingler obtained his honorary doctorate in 1946, promoted him to "Custodian" of the Anatomical Institute in 1948.

The Atlas

The *Atlas Cerebri Anatomi* comprises 100 anatomical tabulae. Each tabula presents a photograph of a dissected specimen followed by a corresponding contoured image that bears labels comprising arrows and numbers (Figure 1C). An adjacent legend, in Latin, follows the - then recently promulgated - Paris Nomina Anatomica, and details the content presented in each view. Mr. Armin Wolf (anatomical technician), Mr. Rolf Muspach (Illustrator) and Mr. Ernst Bernhard (photographer) are credited for their efforts in this section (1). There are superior, lateral and basal views of brains, hemispheres and encephala highlighting features of major tracts and their related structures including the optic radiation (7 tabulae), parts of the corticospinal tract (17 tabulae), cerebellum (4 tabulae), corpus callosum (4 tabulae), thalamic radiation (4 tabulae), midbrain and diencephalic tracts (6 tabulae). There are detailed dissections of the hippocampus (20 tabulae) and of the dentate gyrus (6 tabulae) as well as of the parahipocampal gyrus and uncus (5 tabulae). Four tabulae combine fiber dissection and coronal cuts through the brain and two tabulae detail with diagrams characteristics of the uncinate gyrus and uncus.

The tabulae section is preceded by an introduction, the description of Klingler's method, and remarks on nomenclature sections. These sections are presented in German, English, French and Spanish and the authors credited Mr. Andre Dalcq (Bruxels), Dr. Normand L. Hoerr (Cleveland) and Dr. V. Jabonero (Oviedo) for the French, English and Spanish translations, respectively, while taking care themselves of the German and Latin parts. There is also an invaluable index of related works, displaying previous publications of 30 authors, including Giacomini, Gratiolet, Arnold, Retzius, Schwalbe and Zuckerkandl, as well as both Atlas' authors.

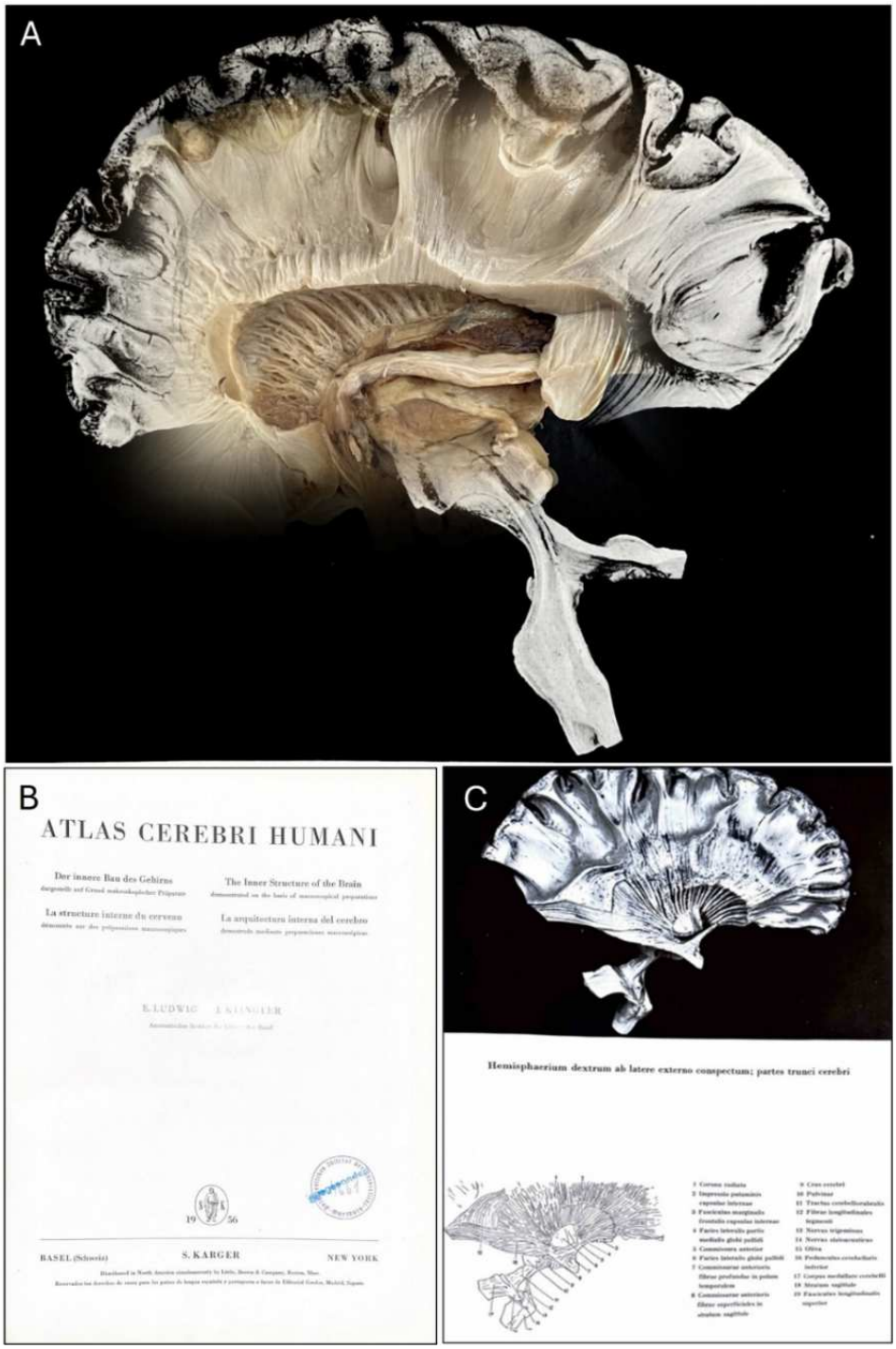

Figure 1. A. *Atlas Cerebri Humani* Tabula 29 has been embedded with a modern fibre-dissection performed by one of the authors (Martins C.). Although 70 years separate these dissections, they were made to serve the same purpose. B. Front page of the *Atlas Cerebri Humani.* The aim of this publication is to display the inner structure of the brain using macroscopical preparations. C. This is a multilingual Atlas organized on 100 anatomical tabulae. Each tabula displays a photo of the fiber dissection; a contoured corresponding image marked with arrows and numbers and a Latin legend of displayed structures.

Conclusions

As we celebrate the Platinum Jubilee of *Atlas Cerebri Humani*, the work stands not only as a historical milestone but as a living reference. Klingler's vision — that understanding the brain requires both scientific rigor and aesthetic clarity — continues to guide anatomists, neurosurgeons, and neuroscientists. His atlas remains a reminder that even in an era of digital imaging, the human hand, guided by curiosity and precision, can reveal the brain's hidden architecture with unmatched depth.

References

1. Ludwig E, Klingler J. Atlas Cerebri Humani. Karger; 1956.
2. Klingler J. Erleichterung der makroskopischen Präparation des Gehirns durch den Gefrierprozess. Schweiz Arch Neurol Psychiatr; 1935, p. 247–56.
3. Türe U, Yaşargil MG, Friedman AH, Al-Mefty O. Fiber Dissection Technique: Lateral Aspect of the Brain. Neurosurgery 2022;47:417–27.
4. Zanuttini L, Staartjes VE, Chen S-C, Lin C-F, Hsu SPC, Martins C, et al. White matter microdissection of the lateral aspect of the brain: 2-dimensional video demonstration. Acta Neurochir (Wien) 2025;167:215. Doi:10.1007/s00701-025-06635-z.
5. Kadri PA do S. The Cartographic Atlas of the Brain. Cham: Springer International Publishing; 2023. Doi:10.1007/978-3-031-38062-4.
6. Agrawal A, Kapfhammer JP, Kress A, Wichers H, Deep A, Feindel W, et al. Josef Klingler's Models of White Matter Tracts: Influences on Neuroanatomy, Neurosurgery, and Neuroimaging. Neurosurgery 2011;69:238–54. Doi:10.1227/NEU.0b013e318214ab79.
7. Universität Basel. Rektoren der Universität Basel 2026.

Antonio Cavalcanti de Albuquerque Martins
https://orcid.org/0000-0002-1249-8622
Carolina Martins
https://orcid.org/0000-0002-0197-3520

Authors Contribution: ACAM, CM: Data collection and organization, substantial contributions to the conception of the work; reviewing it critically for important intellectual content, final approval of the version to be published, agreement to be accountable for all aspects of the work.
Conflict of interest: There are no conflicts of interest.
Funding: There was no funding.