Neurological Surgery and Anatomy 2026, 3(1): 1-4, e-ISSN: 2966-0696
DOI: 10.37085/nsa.2026.1

Original

Calvarial hyperostosis & epilepsy: what is there to know?

Denise Souza de Meira Mota, Jose Ricardo Alves de Lima, Mirella Pessoa Sant'Anna, Daniele Maria da Silva, Luciano Tavares Montenegro, Marcelo Moraes Valença, Carolina Martins

Federal University of Pernambuco, Recife, Pernambuco, Brazil

Introduction
Calvarial hyperostosis and ossification of the falx cerebri are rare postmortem findings, occasionally observed in patients with long-standing epilepsy. Their etiopathogenesis remains unclear, though chronic antiepileptic drug use and metabolic alterations have been implicated.
Objectives
To describe a case of pronounced calvarial hyperostosis and falx cerebri ossification in a patient with chronic epilepsy, and to explore its clinical relevance and potential implications for neurosurgical practice.
Methods
The body of a female person with history of epilepsy and prolonged antiepileptic drug use was examined at the Death Certification Department of the Federal University of Pernambuco (SVO-UFPE) in October 2025. These findings were not related to the cause of death.
Results
Autopsy revealed marked thickening of the cranial vault, particularly in the frontal bone (exceeding 20 mm), and complete ossification of the falx cerebri. The inner skull surface was coarse and tightly adherent to the dura mater. These findings clearly surpassed normal anatomical limits.
Conclusion
This case highlights the potential link between chronic epilepsy, long-term antiepileptic therapy, and abnormal cranial bone remodeling. It highlights the importance of recognizing such alterations in clinical and surgical contexts. Moreover, it reaffirms the broader role of autopsy—not only in determining cause of death, but in uncovering anatomical insights that inform and improve care for the living.

Keywords: Calvarial hyperostosis, Epilepsy, Anticonvulsants, Autopsy

Edited by:
Hung Tzu Wen

Carolina Martins,
maria.cmlima@ufpe.br

Received: February 13, 2026
Revised: April 05, 2026
Accepted: May 04, 2026

© Copyright 2025

Introduction

Calvarial hyperostosis and thickening of the falx cerebri are rare postmortem findings, discovered incidentally during autopsy.

In individuals with long-standing epilepsy, these abnormalities are commonly detected in vivo through neuroimaging techniques. While they are generally regarded as being associated with the disorder, the precise nature of this relationship remains ambiguous. It is often unclear whether such findings might represent inherent characteristics of an epileptic syndrome in itself or whether if they arise as secondary effects of a sustained treatment with antiepileptic medications.

Nevertheless, patients with epilepsy are prone to prolonged seizures that may lead to head trauma and subdural hematomas— common indications for urgent neurosurgical intervention. Thickened frontal bone complicates craniotomy by increasing drilling time, reducing visibility of anatomical landmarks, and elevating the risk of dural tears due to tight adherence between dura mater and inner table. In urgent settings, these factors may delay decompression and elevate intraoperative risk, making awareness of these findings important for the safe management of these patients.

This paper presents the autopsy findings of hyperostosis of the cranium in a long-term epileptic patient, highlighting the gaps in knowledge that could further benefit from research in this area.

Methods

In October 2025, the Death Certification Department at Federal University of Pernambuco (SVO-UFPE) received a female cadaver body to examine. The patient was in her mid-thirties and had a history of epilepsy, for which she chronically used antiepileptic drugs. This study is registered at the Ethics Committee of Federal University of Pernambuco under the number CAAE: 94582325.1.0000.5208.

Results

During autopsy examination an exceedingly thick cranium was observed, particularly around the calvaria, with a completely ossified falx cerebri.

The minimum thickness of the calvaria was 5mm on the occipital squama and over 20mm in areas of the frontal bone. The thickness of the falx varied from 1 to 3mm. The inner surface of the skull was coarse and rugged with a tightly adherent dura (Figure 1). No dysplastic areas in the cerebral cortex were seen.

Discussion

Calvaria universal hyperostosis and thickening of the falx cerebri are rare postmortem findings, discovered incidentally during autopsy.

In patients with long-standing epilepsy, such findings are frequently observed in vivo through neuroimaging. Although these abnormalities are considered to be associated with these conditions, it often remains unclear whether they are intrinsic to the epileptic syndrome itself or represent consequences of prolonged treatment with antiepileptic drugs.

Although most of the literature on anticonvulsant-induced bone changes focuses on osteopenia and osteoporosis, the imbalance generated between the osteoclastic and osteoblastic activity in this circumstance has the potential to result in abnormal cranial bone growth (1). It is hypothesized that anticonvulsants such as phenytoin and valproate (2) may interfere with vitamin D metabolism, leading not only to decreased bone mineral density but also to aberrant osteoblastic activity that could contribute to localized hyperostosis.

Risk for development of cranial hyperostosis may be greater during chronic use of these drugs – as in adults with pediatric onset epileptic syndromes or during particular periods of life such as menopause. Internal frontal hyperostosis (IFH), a subtype of calvarial hyperostosis, has been reported in postmenopausal women and individuals with chronic epilepsy and is characterized by thickening of the inner table of the frontal bone (3).

Beyond the epileptic scenario, autopsy findings of non-focal or universal cranial hyperostosis must exclude differential diagnoses such as osteopetrosis (4), Paget's disease, acromegaly or hematologic disorders based on clinical history and histopathology.

Cranial hyperostotic findings in itself are typically asymptomatic in life, and their presence may reflect long-term metabolic and pharmacologic influences on bone remodeling in epileptic patients.

Beyond being an imagiological finding and a marker of an upset bone metabolism, the increased thickness of the skull in epileptic patients may bear important neurosurgical repercussions. Patients with epilepsy are prone to prolonged seizures that may lead to head trauma and subdural hematomas— common indications for urgent neurosurgical intervention. Thickened bone complicates craniotomy by increasing drilling time, reducing visibility of anatomical landmarks, and elevating the risk of dural tears due to tight adherence between dura mater and inner table. In urgent settings, these factors may delay decompression and elevate intraoperative risk and are directly related to the excessive thickness of the cranium.

In healthy adults, calvaria thickness typically ranges from 6.5–7.1 mm in males and 5.1–6.0 mm in females. Studies using CT imaging and anatomical dissection have consistently shown that the calvarial bone exhibits sex- and site-specific differences. The parietal bone is generally the thickest region, followed by the frontal and occipital bones (5). In our patient the thickness of the cranial vault visibly surpassed these normal limits, but the range of thickness only respected the regional distribution in the occipital area.

The increased thickness of the skull adds challenge to equipment as well. Craniotomes routinely used in neurosurgery have dural protector attachments which vary in length from 23 to 27mm, being the 25mm the one most frequently available in ORs treating adult cases. To negotiate a skull beyond 20mm of thickness with such a hand piece will cause overheating of the motor and may require an excess of cutting bits available for use, as those may undergo exhaustion and breakage during the procedure.

Several questions remain to be answered in the realm of cranial hyperostosis and epilepsy, including prevalence, age and gender of distribution, type of drug associated and span of use, average thickness and thickness distribution in patients affected and the impact of other factors.

A deeper understanding of these phenomena could enhance diagnostics, inform treatment strategies, and ultimately improve outcomes for living individuals with these conditions - fulfilling the fundamental purpose of autopsy: to serve the living by learning from the dead.

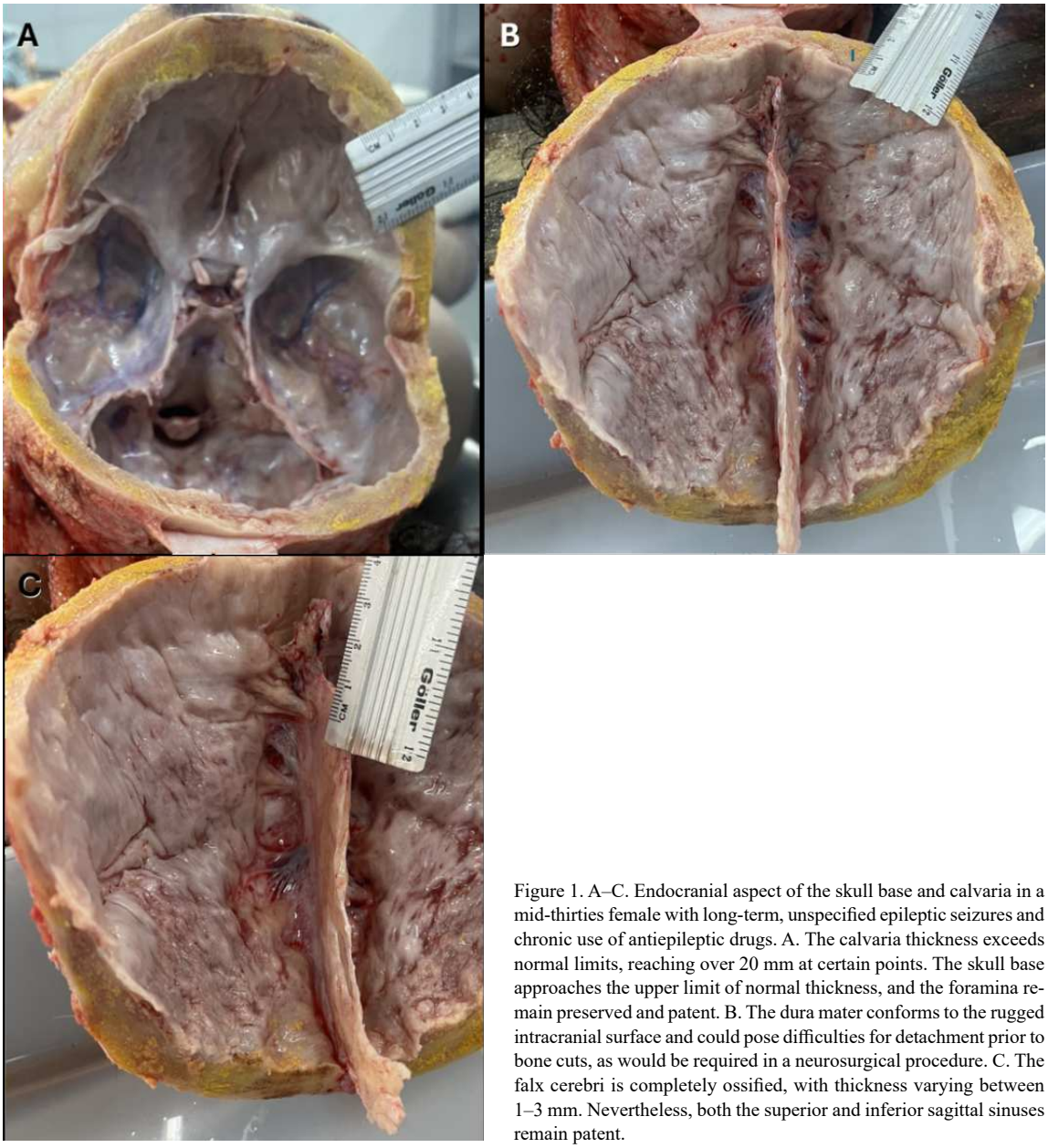

Figure 1. A–C. Endocranial aspect of the skull base and calvaria in a mid-thirties female with long-term, unspecified epileptic seizures and chronic use of antiepileptic drugs. A. The calvaria thickness exceeds normal limits, reaching over 20 mm at certain points. The skull base approaches the upper limit of normal thickness, and the foramina remain preserved and patent. B. The dura mater conforms to the rugged intracranial surface and could pose difficulties for detachment prior to bone cuts, as would be required in a neurosurgical procedure. C. The falx cerebri is completely ossified, with thickness varying between 1–3 mm. Nevertheless, both the superior and inferior sagittal sinuses remain patent.

Conclusions

Health education – supported by virtual tools – is an instrument for promoting people's life quality. In SCI scenario, it provides health professionals of different backgrounds access to specialized technical knowledge in adequately managing SCI patients. SCI-instructed health providers facilitate patient, family and community education. Virtual tools such as these require Tutors who are experts in their fields and familiar with technology.

References

1. Pack A. Bone health in people with epilepsy: Is it impaired and what are the risk factors? Seizure 2008;17:181–6. Doi:10.1016/j.seizure.2007.11.020.
2. Sankavi K, Selvakumar C. First line antiepileptics and their hidden risks - a unique case report on diffuse calvarial thickening and twisted tongue linked to the use of phenytoin and sodium valproate. Asia Pac J Med Toxicol 2024;13:164–6.
3. She R, Szakacs J. Hyperostosis frontalis interna: case report and review of literature. Ann Clin Lab Sci 2004;34:206–8.
4. Valença MM, Lima, M de. Osteopetrose: Relato de caso e revisão da literatura. An Fac Med Univ Fed Pernamb 1996;41:143–8.
5. Farzana F, A. Shah B, Shadad S, Zia ul Haq P, Sarmast A, Ali Z. Computed tomographic scanning measurement of skull bone thickness: a single center study. Int J Res Med Sci 2018;6:913–6. Doi:10.18203/2320-6012.ijrms20180614.6.

Denise Souza de Meira Mota
https://orcid.org/0009-0008-1540-344X
Jose Ricardo Alves de Lima
https://orcid.org/0009-0003-1222-7480
Mirella Pessoa Sant'Anna
https://orcid.org/0000-0002-2218-9153
Daniele Maria da Silva
https://orcid.org/0009-0006-1158-8550
Luciano Tavares Montenegro
http://orcid.org/0009-0003-9051-7133
Marcelo Moraes Valença
https://orcid.org/0000-0003-0678-3782
Carolina Martins
https://orcid.org/0000-0002-0197-3520

Authors Contributions: DSMM, JRAL, LTM, MMV, CM: Conceptualization, Supervision, Methodology. DSMM, JRAL, MPS, DMS, CM: Investigation, Data Collection, Writing — review & editing. CM: Writing — original draft, Image Treatment. DSMM and CM contributed equally as first authors in this paper.
Conflict of Interest: There is no conflict of interest.
Funding: There was no funding.