Neurological Surgery and Anatomy 2026, 3(1): 10-20, e-ISSN: 2966-0696
DOI: 10.37085/nsa.2026.3

History of medicine

Christ Pantocrator & hand neuromuscular systems

Gabriela Cavalcanti de Oliveira[1], Julia Nathaly Cavalcanti Mendes de Sales[1], Victoria Maria Costa Xavier Brasil Rodrigues[1], Antonio Cavalcanti de Albuquerque Martins[1,2], Carolina Martins[3]

[1]Medical School of Pernambuco, Recife, Pernambuco, Brazil
[2]Institute of Integrative Medicine Professor Fernando Figueira, Recife, Pernambuco, Brazil
[3]Federal University of Pernambuco, Recife, Pernambuco, Brazil

Edited by:
Marcelo Moraes Valença

Abstract

Introduction
Christ Pantocrator, a central motif in Byzantine art, is a symbol of the plural nature of Christ. His body features and elevated right hand being distinctive traits. While traditionally interpreted symbolically, its anatomical basis has not been analyzed.

Objective
To examine the anatomical and functional basis behind the hand gesture of Christ Pantocrator, its origins, similar representations, symbolic meanings and potential use of this image as teaching-case in human anatomy.

Methods
Depictions of Christ Pantocrator were searched and selected according to dates before and after 1054 CE. Hand gestures were compared between sides, across periods, and against other depictions of Christ. Finger and hand positioning were observed and muscular involvement described according to hands' neuromuscular systems. Functional and morphological classification of these gestures was attained.

Results
The right-hand gesture of Christ Pantocrator typically involves flexion of the fourth and fifth digits with partial extension of the second and third, coordinated with thumb opposition and in a pincer-like grip, at the far end on a spectrum towards precision. This capacity for refined digital opposition is more developed in humans than in any other primate and requires elements from all neuromuscular systems of the hand.

Conclusion
Anatomical analysis of Christ Pantocrator hand gesture reinforces Byzantine aesthetics. Irrespective of recognition in Byzantine era, today it should be understood as an additional, specifically anatomical sign affirming the humanity of Christ and a bridge between human and divine. Its use as teaching-case for hands' neuromuscular systems can prove a compelling motivation for learning anatomy.

Keywords: Neuromuscular systems, Human anatomy, Hand, Precision grip, Byzantine art

Carolina Martins,
maria.cmlima@ufpe.br

Received: January 28, 2026
Revised: April 24, 2026
Accepted: May 11, 2026

© Copyright 2025

Introduction

A central icon of Byzantine art, Christ Pantocrator (In Greek: *Χριστός Παντοκράτωρ*), meaning "Christ, the Almighty" or "Christ, Ruler of All", embodies the union between sacred and human, symbolizing divine power and eternity within the traditions of Eastern Christianity. Found in mosaics and panel paintings — such as those in Monastery of Saint Catherine in Sinai, Egypt and Hagia Sophia Basilica in Istanbul, Türkiye — the image depicts Christ in a frontal position, holding the Gospel in His left hand and performing a hand gesture — usually seeing as a blessing- with His right hand.

The configuration of the fingers in this hand gesture is meaningful and represent key theological concepts. From an anatomical perspective, this hand gesture results from the coordinated action of the hand muscles revealing uniquely human features embodied in a sacred symbol.

This study details the anatomical aspects — specifically the neuromuscular systems engaged in the hand gesture of Christ Pantocrator — and illuminates how profoundly it embodies the ultimate aim of Byzantine art: the manifestation of the divine through the human form.

Method

This descriptive study analyzes classical representations of Christ Pantocrator from various historical periods, selected from public collections of sacred art. They were searched and selected according to dates before and after 1054 CE to verify consistency of this representation during a period of divergence between traditions. The position of Christ's hands was examined to characterize finger configuration in these gestures. Anatomical literature (1–4) was reviewed to identify the forearm's extrinsic muscles, the hand's intrinsic muscles, and the neuromuscular system underlying each digital movement. Findings are presented using images, tables, and diagrams, enabling correlations between iconographic posture and hand biomechanics, and supporting discussion of their anatomical and symbolic coherence.

Results

Christ Pantocrator

In Byzantine tradition, Christ Pantocrator is the dominant image in church decoration, often placed in a dome or apse. In the ancient world, geometric spheres (such as the dome or apse) represented the cosmos. Combined with the image of Christ at its centre, this served as a symbolic affirmation of Christ as master of the universe (5). Christ is, therefore, portrayed as the human ruler of the mortal world and the divine ruler of the heavenly realm, encompassing the entire universe. The Christ Pantocrator is, therefore, *par excellence*, a symbol of the plural nature of Christ.

The Christ Pantocrator from St. Catherine's Monastery at Mount Sinai, Egypt (Figure 1), is the earliest surviving example of its type (6,7), preserved largely due to favourable weather conditions and the Monastery's remote geographical location (6), which protected it from decay and Byzantine iconoclasm.

The Christ Pantocrator in the dome of Hagia Sophia (Figure 2) — today Istanbul, then Constantinople, the thriving capital of the Eastern Roman (Byzantine) Empire — only appeared in the thirteenth century, possibly due to financial or construction constraints. Portable icons, however, were thought to feature there by the end of late antiquity and the Middle Ages (5,7).

As Christ Pantocrator, Christ is depicted as a long-haired, bearded, muscular adult male (with a thick neck and strong clavicular region), markedly different from the youthful Christ (Christ Emmanuel) or the suffering Christ on the cross. By donning a golden tunic or mantle (Greek himation), the image references *Christos Helios*, the "Sun of Righteousness" (5). Christ is shown frontally, with a solemn expression, a cross within his halo, and notable facial asymmetry, with divergent pupillary lines of sight, typical of the reverse perspective of Byzantine art (12). His right hand is raised in a gesture, while the other holds the Gospel - either as a book or a scroll. This image emphasizes both Christ's divinity and humanity and appears to have evolved from the sixth century onward as a calculated shift (7) vital to the success of Christianity.

Although considerable scholarly debate exists regarding the evolution, origins, and symbolic meaning of Christ's facial features, clothing, surrounding symbols, and even hairstyle (5,7), far less attention has been devoted to the hand gesture (or the precise position of each finger, for that matter) of the Christ Pantocrator. This gesture is usually described as rooted in oratorical traditions and interpreted as a sign of blessing, forgiveness, benediction, teaching, authority, or peace (5,7); although the precise hand and finger positions vary between representations.

In Hagia Sophia, different hand gestures appear in various mosaic panels (Figure 2C-E). These gestures in Byzantine iconology seem to derive from Greco-Roman orators, who used them to request silence at the beginning of a speech or as an auxiliary means of conveying their message. The Christ Pantocrator above the Imperial Door (8) joins the pollex (thumb) to the tips of the fourth and fifth digits in a relaxed manner. This same gesture is seen in the earlier Christ Pantocrator at Mount Sinai (7) and in a slightly different version in the Comnenus Mosaic (11) at Hagia Sophia, where Christ is depicted as a toddler seated on the Virgin Mary's lap. Although youthful, this depiction shares several iconographic elements with the Christ Pantocrator. Here, the thumb joins the annularis (ring finger) at its middle, while the index and middle finger are raised.

Elsewhere in Hagia Sophia, the Christ Pantocrator in the Empress Zoe Mosaic (10) joins the pollex and annularis, a gesture that appears to replicate the IC XC Christogram.



Figure 1. A. Icon of Christ Pantocrator. St. Catherine's Monastery, Mount Sinai, Egypt, encaustic on wood panel, 84 x 45.5x 1.2cm. Sixth century CE (6,7). It is thought to have been commissioned by Justinian I between 548 and 565 CE, produced in a workshop in Constantinople, and subsequently sent to the Monastery (7). Note the long hair, arranged around the head — an unusual hair style that reminds the ascetics, the strikingly different hemifaces and pupillary lines of sight — markings of the reverse perspective characteristic of Byzantine art (12), and the hand gesture on the right and the Gospel on the left hand.

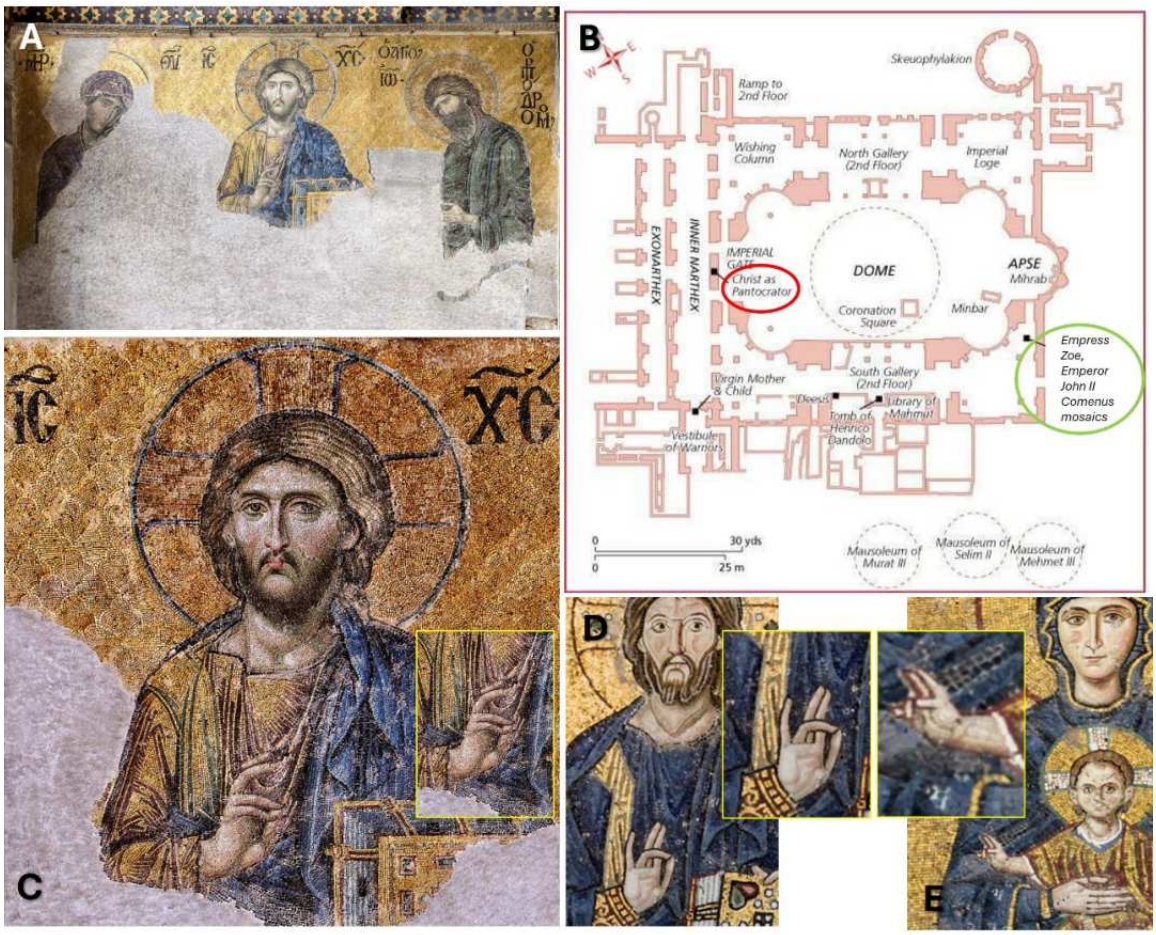

Figure 2. A. The Christ as Pantocrator (8) is usually depicted in the center of a Deësis (*δέησις*, meaning "prayer" or "supplication" scene); Christ usually being flanked by Mary and St. John the Baptist. In Istanbul, Christ Pantocrator is sided by the Greek letters IC XC, a “Christogram” or shorthand abbreviation for "*Iēsoûs Chrîstos*" (Jesus Christ), being the first and last letters of each Greek word: *ΙΗΣΟΥΣ* (Iēsous/Jesus) and *ΧΡΙΣΤΟΣ* (Christos/Christ), with the Greek Sigma (Σ) written as a 'C' (lunate sigma), possibly dating from the 13th century (5,7,8). B. In Hagia Sophia in Istanbul, this Deësis panel is located above the Imperial Door (9), in the southwest gallery (red circle). C. Although similar, the Christ Pantocrator in the center of this Deësis has a different hand gesture than the Christ seen close by (green circle) at the center of Empress Zoe’s Mosaic (Christ Enthroned) (10) (D) or the Jesus as a toddler in Mary’s lap at the center of the Comnenus Mosaic (11), assumed to be older (11th Century CE) (E). The different hand gestures of the Christ possibly speaking for specific, time-evolving meanings. D. Center part of the Empress Zoe mosaic, Hagia Sophia, circa 11th Century CE (10). Insert: Detail of the hand gesture. E. Center part of the Comnenus mosaics, Hagia Sophia, circa 11th Century CE (11) Insert: Detail of the hand gesture.

Anatomical Analysis

Considering these representations of Christ, while the left hand is usually displayed in power grip; the right hand, elevated and in first plane, is in precision grip.

Within precision hand movement category, pincer-like grips can be distinguished based on the part of pollex contacting other fingers into tip-to-tip (terminal), pad-to-pad (subterminal) or lateral and - from more to less contact area between fingers - organized within a spectrum of descending power and increasing precision.

Christ's right-hand postures are not only in precision grip, but into pincer-like grips along the highest precision end of the spectrum (Box 1).

Three neuromuscular systems: a) ulnar, b) radial, c) median, are involved in these postures. The ulnar system creates the grasping groove. The radial system guarantees best position for ulnar and median systems to function, providing synergistic and antagonistic actions essential to dynamic function; and the median system provides opposition – fundamental to the ability to handle objects with increasing degrees of precision.

Box 1. Functional & morphological classification of Christ's hand gestures

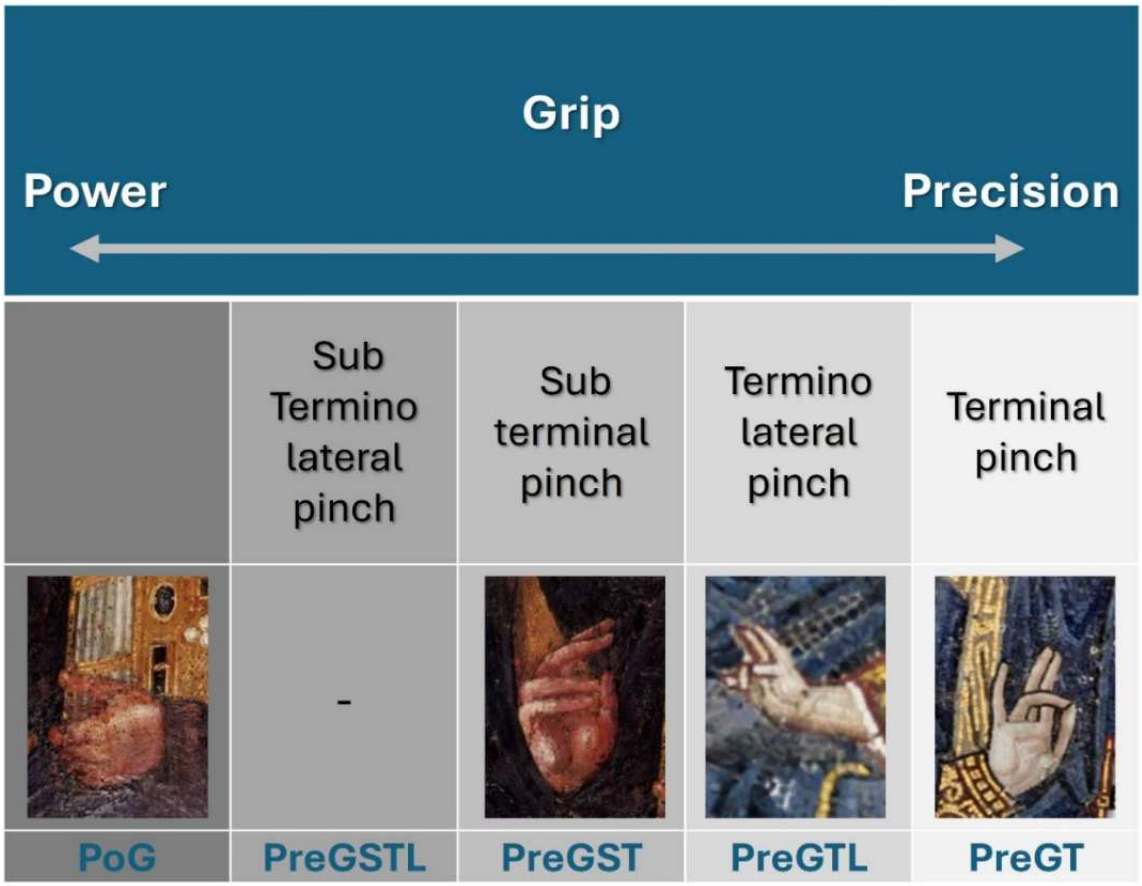

Neurological Surgery and Anatomy

Box 2. Christ Pantocrator hand gesture and neuromuscular systems of the hand

<table>
<tr><th>Action Area</th><th colspan="4">Movement and Muscle</th><th colspan="2">Neural Pathway</th></tr>
<tr><td rowspan="11"></td><td colspan="4">Creating the grasping channel</td><td rowspan="11">Ulnar Nerve (Nervus Ulnaris)</td><td rowspan="11">C8-T1</td></tr>
<tr><td colspan="2" rowspan="2">Flexion of metacarpophalangeal joints and approximation/ separation of last four fingers</td><td>Interossei m.</td><td rowspan="5">Internal border</td></tr>
<tr><td>lumbricales tertius et quartus mm.</td></tr>
<tr><td colspan="2" rowspan="3">Opposition of the 5th metacarpal by antepulsion and radial rotation and flexion of first phalangeal joint of 5th finger</td><td>Flexor digiti minimi brevis m.</td></tr>
<tr><td>Opponens digiti minimi m.</td></tr>
<tr><td>Abductor digiti minimi m.</td></tr>
<tr><td colspan="2">Flexor of interphalangeal joints of 4th and 5th fingers</td><td>Flexor digitorum profundus m.</td></tr>
<tr><td>Approximation and radial rotation of the thumb, as happens during the sub and terminolateral pincer-like grip (Box 1 PreGST)</td><td rowspan="2">Both muscles are contracted during maximal approximation pincer-like grip (Box 1 PreGST)</td><td>Adductor pollicis m.</td><td rowspan="3">External border</td></tr>
<tr><td>Antepulsion, approximation and ulnar rotation of the thumb, as happens during subterminal pincer-like grip (Box 1 PreGT)</td><td>Flexor pollicis brevis m. (caput profundum)</td></tr>
<tr><td colspan="4">*Rotating the hand to the ulnar side
(grasping channel and tool assume same axis of the forearm)</td></tr>
<tr><td colspan="2">Ulnar deviation of the hand required in power grip (Box 1 PoG)</td><td>Flexor ulnar carpi m.</td></tr>
<tr><td colspan="7">*This action and muscle are important for power grip. But, as grips usually reverse — on the same hand during execution of a dynamic task, we elected to keep them listed here, in a subtle colour.</td></tr>
</table>

Neurological Surgery and Anatomy

Action Area	Movement and Muscle		Neural Pathway	
	**Helping opposition of thumb**		Radial Nerve (Nervus Radialis)	(C5) C6-T1
	Synergic action during thumb opposition	Abductor pollicis longus m.		
	Carpal alignment and extension during precision grip			
	Separation of the wrist. Carpal extension during precision grip (Box 1 PreG)	Extensor carpi radialis longus e brevis mm.		
	Carpal extension during precision grip (Box 1 PreG)	Extensor digitorum m.		
	Adjunct movement			
	Extension of index during maximal approximation pincer-like grip (Box 1 PreGST-GT)	Extensor indicis m.		
	Extension of 5th digit during maximal approximation, when the pincer-like grip involves only the 4th digit (Box 1 PreGT)	Extensor digiti minimi m.		

Neurological Surgery and Anatomy

Action Area	Movement and Muscle		Neural Pathway	
	***Pinching***		Median Nerve (Nervus Medianus)	C6-T1
	Antepulsion, adduction and ulnar rotation of the thumb (opposition)	Opponens pollicis m.		
		Abductor pollicis brevis		
	Auxiliary during opposition to the 4th and 5th digits. Participation in maximal approximation subterminal pincer-like grip (Box 1 PreGST)	Flexor pollicis brevis m. (caput superficialis)		
	Flexion of distal phalanx of the thumb. Participation in terminal pincer-like grip	Flexor pollicis longus m.		
	Grasping and handling			
	Flexion of phalangeal joints of 2nd and 3rd digits	Flexor digitorum profundus m.		
	Flexion of intermediate phalangeal joints of the four last digits	Flexor digitorum superficialis m.		
	Wrist deviated to radial side and dorsiflexed (with extensor carpi radialis longus - See SNM of radial nerve)	Flexor carpi radialis m.		
	Approximation of thenar and hypothenar areas	Palmaris longus m.		

Discussion

Parallels between "mudras", "hasta" and byzantine iconography

Visual parallels between Sanskrit "mudras," Indian "hasta", and Byzantine hand gestures are striking — suggesting a shared origin in human history; nevertheless, their purposes and applications seem different.

"Mudra" is a Sanskrit word used for the hand or the hands position to describe ritual gestures conveying different messages (13,14).

In the Vedas, the word derives from "mud" and "ra" meaning "to rejoice" and "to give" (14). It acquired, connected, post-Vedic alternative meanings, including "seal or stamp" or "mark – here particularly "a token or mark of divine attributes impressed upon the body", and in this sense included the act of calculating using the fingers. This word found expanded meanings in different Buddhist practices that include "to make an instantaneous impression", "to show the nature of deity by images", "to show the nature of deity by way of body", "to show the meaning of the language of deities" (13).

However, while "mudra" is often used by hand gestures with religious or spiritual meanings, "hasta" is usually employed for hand gestures in Indian dance (13), that are thought as a sign language used to tell a story or plot.

No one knows for sure where and how "mudras" originated but they have been in use for millennia and can possibly be traced back to the remote past when men started communicating with each other using gestures as a sign language in the absence of script, dialogue and oral language itself.

The earliest recorded uses appear in symbolic form, within the Egyptian and Indus scripts—still only partially deciphered (14).

It is believed that its use in ancient civilizations in Rome, Egypt, Greece, and South Asian cultures as Hinduism, Buddhism and Jainism help shape the iconography of a god/goddess (14) and convey symbolism related to the different manifestations of the same god/goddess.

In Hinduism, the earlier recorded knowledge and analysis of mudras is registered in Mantra, Upasana, and Nritya Shastras and the Bhagavad Gita (13,14). In Hinduism, "mudra" use relates each finger of the hand to a specific meaning, energy, element and body part/ functions; therefore, the specific positioning of the fingers help channel energy and has health uses. There are 24 known single hand postures and 13 dual hand postures, to be employed with static poses (asanas) or dynamically during the practice of Hinduism (14). Although Hinduism is one of the oldest religions of the world, hand gestures are also part of Buddhism, Jainism, Christianity and Islamism.

As non-verbal communication, hand gestures are deemed not only to retain the efficacy of the spoken word, but also to convey an external expression of inner resolve, in this sense being even more powerful than the spoken word.

It seems that Christianity borrowed from this more universal use of hand symbols present worldwide. In Christianity, it seems that hand gestures underlined and sealed what was in the mind of the speaker or actually being said and evolved from the ancient Roman orator's gesture indicating "I am speaking" (15). Because of the persecution of early Christians, the alternate meanings were initially conveyed only to initiates. Later — possibly after the 4th century CE, they were partially integrated into the Christian teachings. Because secrecy was no longer necessary, their use declined and their meaning was largely forgotten (12). However, loose versions of these gestures can still be observed during daily Mass celebrations and other church functions (16).

If any correlation can be made, the hand gesture with the pollex (thumb) connecting to the annularis (ring finger or 4th digit) and minimus (auricularis or 5th digit) — as seen in the *Christ Pantocrator of Mount Sinai Monastery* (3) and at the main Deësis, over the Emperor's Door, in Hagia Sofia (6) — would be akin to the *Pran Mudra*. As a "mudra," this gesture is associated with invoking (or offering) enhanced vitality and protection against disease (14), while in its Christian context it functions as a version of the finger position of benediction or blessing (10), which also appears in a variant where the pollex, annularis, and minimus do not touch, or even in a more anatomically distant configuration in which the pollex is abducted and unopposed, with the annularis and minimus flexed at the first interphalangeal joint. In this last version the three extended fingers are deemed to represent the Trinity (Father, Son and Holy Spirit) and the two flexed ones the dual nature of the Christ (Divine and Human) — complex theological precepts of Christian faith (16,17).

The pollex and annularis conjoined at the tip as seen in the Empress Zoe's mosaic would be akin to (7). As a "mudra" it is deemed to be related to invoking (or offering) balance between mind and body. In its Christian context this hand position seems to replicates the Christogram in which the fingers are arranged to form the first and last letters of Jesus (IHCOYC) and Christ (XPICTOC) in Greek (I-C-X-C): the extended index forms the I, the relaxed middle finger forms the C, the thumb and ring finger together form the X, and the curved little finger (minimus) forms the final C (lunate sigma) (5); other meanings attributed to this hand gesture are "Christ incarnated" by conjoining His dual nature (5,7) and an indication of "inner peace", the inner state proper of the Christ and an aspired state to be searched for by His Followers, as well as the state required to practice of hesychasm — a contemplative, mystical tradition in Eastern Orthodox Christianity focused on achieving inner stillness (hesychia) (5), akin to meditation.

Neuromuscular systems and hand grip

In the 50's, Napier (18) defined a functional and morphological classification of the hand movements with sound anatomical basis; furthermore — contrary to the thought at the time that hand position was conditioned by the shape of object being grasped, he demonstrated that the position assumed by the hand while holding or grasping an object depended on the purpose with which that object was being held and the stabilization required to performing the task at hand. Two large groups issued, within which other refined versions could be added: a) power and b) precision grip postures.

Further from being static, Napier (18,19) also demonstrated that the type of grip changed — and many times contrasted between hands, according to the characteristic of the task, and its execution. This re-

alization has since influenced the understanding of hand movements and their pathology, rehabilitation and prosthetics (20) as well as the design of daily life (21), surgical (22) and robotic instruments (23) and the anatomical approach to the study of the hand (4).

Particularly in anatomy teaching, the field evolved from identification of individual muscles in the arm, forearm and hand, and their grouping according to regional compartments; to a broader and more meaningful understanding of neuromuscular systems involved in specific hand movements.

The fundamental difference between these grip postures is related to the thumb. While adducted at the carpometacarpal and metacarpophalangeal joints in power grip, it is abducted at both joints during precision grip — a complex movement Napier redefined as opposition (19): a movement which results in the pulp surface of the thumb becoming diametrically opposed to the pulp surface of one or other of the remaining digits for the purposes of prehension.

In the precision grip, the thumb forms one jaw of a clamp (anatomically, the external border of the grasping clamp — See Box 2), while the opposing jaw is part or the whole of the flexor surface of the fingers (the internal border of the grasping clamp). In this thumb position, the sensory surfaces of the fingers are utilized to their greatest benefit (18), allowing — in response, for fine adjustments of posture. The thenar branch of the median nerve has a prominent role here as it provides motor innervation to the thenar muscles enabling thumb opposition and precision grip, while the deep branch of the ulnar nerve supplies the hypothenar and interosseous muscles, supporting finger ab/adduction and fine coordination.

In the power grip the clamp opposed to the flexed fingers is formed by the palm itself. Here the fingers are flexed, fingers and palm rotated and concave and the wrist deviated to the ulnar side. This ulnar deviation is paramount as it determines that the thumb axis, grasping channel — an object being held, coincides with the axis of the forearm — potentially increasing momentum. This ulnar deviation is overcome when the precision grip is attained (please compare the ulnar deviation on the left hand and the radial action on the right hand in Figure 1). Moreover, while the wrist is not allowed to flex in the power grip — ensuring the best conditions for effective finger flexion, this is enhanced into dorsiflexion of the wrist in precision grip — allowing objects to be manipulated away from the palm and exclusively at finger level.

Studies in the evolution of the human hand have shown that the fossil record (24) and biomechanical analyses based on them (25) support these grip postures as evolving from activities like throwing (power grip) and clubbing (precision grip) Among several anatomical features that allowed precision to develop, the role of the muscle opponens pollicis in positioning the longer and more powerful version of the pollex is essential.

Anatomical analysis of Christ Pantocrator

To our knowledge this is the first time the iconography of the Christ in Byzantine art is submitted to detailed anatomical scrutiny. From an anatomical standpoint, most variations of Christ's right-hand gestures in Byzantine iconography involve opposition of the thumb, a movement dependent on intrinsic muscles of the thenar region that have developed over the last two million years (18,24,25).

This capacity for refined digital opposition is far more developed in humans than in any other primate, but the genus Homo (25). Furthermore, this precision, pincer-like grip signals the human species' ability to manipulate objects and create.

In Eastern Christian tradition, iconography does not seek mere realistic reproduction, but rather the revelation of the divine presence through the transfigured human form (12). The manual gestures of Christ are seen to embody fundamental theological principles, such as the union of the human and divine natures and the Trinitarian mystery (5,7,12,13,16). In this realm, our analysis reinforces the coherence between symbol and spirituality defined by Byzantine aesthetics. Irrespective of recognition in the Byzantine era, today it should be understood as an additional, specifically anatomical sign affirming the humanity of Christ and a bridge between the human and the divine.

For anatomical teaching, since the precision grip engages all three neuromuscular systems of the hand, its representation — as in Christ Pantocrator, provides solid and meaningful didactic foundation for teaching hand anatomy, offering a compelling way to motivate students to learn.

Conclusion

In the right-hand gesture of Christ Pantocrator, thumb opposition serves as a subtle yet profound reminder of Christ's humanity. By depicting Christ with a gesture rooted in distinctly human motor anatomy, Byzantine artists affirmed not only Christ's divine authority but also Christ's full participation in the embodied condition of humankind.

References

1. Gray Henry, Standring Susan, Ellis Harold, Berkovitz BKB. Gray's anatomy : the anatomical basis of clinical practice. Elsevier Churchill Livingstone; 2005.
2. Gardner E, Gray DJ, O´Rahilly R. Anatomia - Estudo Regional do Corpo Humano - Métodos de Dissecação. 4th ed. Rio de Janeiro: Guanabara Koogan; 1978.
3. Schunke M, Schulte E, Schumacher U. Prometeus, atlas de anatomia: cabeça e pescoço. Rio de Janeiro: Guanabara Koogan; 2007.
4. Smith-Fernandéz VM, Rodríguez García S, Smith-Fernandéz A, Fernandéz-Ortega I, Smith-Agrega JM. Atlas de los sistemas neuromusculares : con funciones musculares estáticas y dinámicas. 2nd ed. Espaxs; 2003.
5. Baghos M. Christ Pantokrator in the Byzantine Art of Italy. PHRONEMA 2019;34:55–84.
6. The Monastery Skevophylakion. The Holy Monastery of the God-Trodden Mount Sinai 2026. https://www.sinaimonastery.com/index.php/en/treasures/skevophylakion-treasury (accessed January 9, 2026).

7. JOHNSON A. Christ pantocrator: god, emperor, and philosopher the byzantine iconography of Christ. University of Georgia, 2021.
8. Christ Pantocrator Deesis mosaic Hagia Sophia [image on the Internet]. ca. 13th century CE. https://commons.wikimedia.org/wiki/File:Christ_Pantocrator_Deesis_mosaic_Hagia_Sophia.jpg (accessed January 9, 2026).
9. The Hagia Sophia Grand Mosque. Müze İstanbul 2026. https://muze.gen.tr/muze-detay/ayasofya (accessed January 9, 2026).
10. Empress Zoe mosaic Hagia Sophia. ca. 11th century CE. https://commons.wikimedia.org/wiki/File:Empress_Zoe_mosaic_Hagia_Sophia.jpg (accessed January 9, 2026).
11. Comnenus mosaics Hagia Sophia [image on the Internet]. ca. 1118 CE. https://commons.wikimedia.org/wiki/File:Comnenus_mosaics_Hagia_Sophia.jpg (accessed January 9, 2026).
12. Díaz Calvete J. Pavel Florensky, reverse perspective and the neurosciences. Bachelor thesis. Universitat Pompeu Fabra, 2019.
13. Todaro D. The Meanings of the term Mudra and a Historical Outline of "Hand gestures." Journal of Esoteric Buddhism 1985;1985:71–54.
14. Rajput MS. The Source, Meanings And Use Of "Mudra" Across Religions. International Journal of Computational Research and Development 2016;1:36–41.
15. Rocconi E. The Orator and the Dancer. Conceptualizing Gestures in Roman Performances. In: Schlapbach K, editor. Aspects of Roman Dance Culture. Religious Cults, Theatrical Entertainments, Metaphorical Appropriations, vol. 80, Franz Steiner Verlag; 2022, p. 269–84. Doi:10.25162/9783515133258.
16. Kollmorgen G. The Latin Gesture of Benediction: A History in Images and a Plea for a Return. New Liturgical Movement 2010. https://www.newliturgicalmovement.org/2010/02/lat-in-gesture-of-benediction-history-in.html (accessed January 8, 2026).
17. Lossky V. The mystical theology of the Eastern Church. New York: ST Vladimir's Seminary Press; 1976. https://archive.org/details/mysticaltheology0000loss (accessed January 11, 2026).
18. Napier JR. The Prehensile Movements Of The Human Hand. J Bone Joint Surg Br 1956;38-B:902–13. Doi:10.1302/0301-620X.38B4.902.
19. NAPIER JR. The form and function of the carpo-metacarpal joint of the thumb. J Anat 1955;89:362–9.
20. Feix T, Romero J, Schmiedmayer H-B, Dollar AM, Kragic D. The GRASP Taxonomy of Human Grasp Types. IEEE Trans Hum Mach Syst 2016;46:66–77. Doi:10.1109/THMS.2015.2470657.
21. Norman D. The design of everyday things. Basic Books; 2013.
22. Rhoton Junior AL. Rhoton cranial anatomy and surgical approaches. 1st ed. Illinois: Lippincott William & Wilkins; 2003.
23. Cutkosky MR. On grasp choice, grasp models, and the design of hands for manufacturing tasks. IEEE Transactions on Robotics and Automation 1989;5:269–79. Doi:10.1109/70.34763.
24. Young RW. Evolution of the human hand: the role of throwing and clubbing. J Anat 2003;202:165–74. Doi:10.1046/j.1469-7580.2003.00144.x.
25. Karakostis FA, Haeufle D, Anastopoulou I, Moraitis K, Hotz G, Tourloukis V, et al. Biomechanics of the human thumb and the evolution of dexterity. Current Biology 2021;31:1317–25. Doi:10.1016/j.cub.2020.12.041.

Gabriela Cavalcanti de Oliveira
https://orcid.org/0009-0006-6987-9828
Julia Nathaly Cavalcanti Mendes de Sales
https://orcid.org/0009-0001-6709-8407
Victoria Maria Costa Xavier Brasil Rodrigues
https://orcid.org/0009-0009-9936-275X
Antonio Cavalcanti de Albuquerque Martins
https://orcid.org/0000-0002-1249-8622
Carolina Martins
https://orcid.org/0000-0002-0197-3520

Authors contribution: GCO, JNCMS, VMCXBR, ACAM, CM: Investigation, data collection and Writing—review & editing; GCO, JNCMS, VMCXBR: Writing—original draft; ACAM, CM, Historical data gathering: Conceptualization, Methodology, Image treatment, Supervision; GCO and ACAM contributed equally as first authors in this paper.
Conflict of Interest: There is no conflict of interest.
Funding: There was no funding.