Neurological Surgery and Anatomy 2025, 2(3): 87-93, e-ISSN: 2966-0696
DOI: 10.37085/nsa.2025.16

Original

Where is the beginning of the sylvian cistern?

Florisvaldo Jose Morais Vasconcelos Junior[1], Marcelo Moraes Valença[1], Carolina Martins[1,2]

[1]Federal University of Pernambuco, Recife, Pernambuco, Brazil
[2]Medical School of Pernambuco, Recife, Pernambuco, Brazil

Abstract

Introduction

The sylvian cistern is the most important microsurgical avenue, used worldwide to approach lesions located in the opercula, insula, and anterior basal cisterns. Its sphenoidal segment is bounded laterally, superiorly, and inferiorly by identifiable neural structures. However, its medial boundary—formed by the medial sylvian arachnoidal membrane surrounding the middle cerebral artery (MCA) as it arises from the carotid bifurcation—remains challenging to delineate in neuroimaging, particularly in non-contrast studies.

Objective

This investigation evaluates the anatomical basis and feasibility of using a sagittal plane projected from the posterior portion of the olfactory sulcus as a surrogate marker for the medial limit of the sylvian cistern.

Methods

Ten contrast-enhanced T1-weighted brain MRI scans were reviewed, yielding 20 hemispheres. Image datasets were processed using 3D Slicer (version 5.8.1), and the sagittal plane projected from the posterior portion of the olfactory sulcus was compared to the location of the internal carotid artery bifurcation.

Results

In 95% of cases (19/20 sides), the projected plane led to the carotid bifurcation and helped separate the anterior perforating substance, forming the roof of this cistern, into lateral and medial portions.

Conclusion

These findings support the use of a sagittal plane projected from the posterior olfactory sulcus as a reliable surrogate for the medial boundary of the sylvian cistern, particularly in non-contrast imaging. In contrast-enhanced studies, the carotid bifurcation remains a valid and frequently employed landmark. The integration of both approaches may enhance anatomical precision and facilitate further studies of the sylvian cistern, including volumetric studies, and their translation into the surgery.

Keywords: Lateral sulcus (sylvian fissure), Subarachnoidal spaces, Neuroimaging

Edited by:
Juliana Ramos de Andrade

Florisvaldo Jose Morais Vasconcelos Junior,
florisvaldo.vasconcelosjunior@ufpe.br

Received: October 23, 2025
Revised: Dezember 30, 2025
Accepted: Dezember 30, 2025

© Copyright 2025

Introduction

The sylvian cistern is the main surgical route to the brain and used worldwide. It may lead surgeons to lesions located in the opercula and insula; it is a route to the anterior basal cisterns at a supratentorial level, and through those to several other compartments and spaces in and around the brain and brainstem. The sylvian cistern is bent in a L-shape around the limen insulae, and classically divided into anterior or sphenoidal segment, facing the sphenoidal crest and related to the sylvian fissure stem; and a lateral compartment, superficially related to the anterior and posterior rami of the sylvian fissure and whose space is further subdivided into a vertical, medial or insular component and a horizontal, lateral or opercular part (1–4).

The anterior or sphenoidal segment of the sylvian cistern is located medial to the limen insula. This anatomical fact is fairly recognizable - even without seeing this landmark - by any surgeon opening the cistern and even by an experienced observer outside of the surgical field. At this point the cisternal axes have a difference close to a 90-degree angle between its anterior and lateral parts, therefore, whenever a surgeon reaches the limen insula, he/she will – instinctively - reposition the microscope - to guarantee that the structures being followed are aligned once more in a position perpendicular to their eyesight (1). These repositioning maneuvers signal that the limen insulae has been reached and the anterior segment of the sylvian fissure is about to be entered.

If the lateral limit of the sphenoidal compartment is easy to determine, so is its superior limit. The superior wall of the sphenoidal segment of the sylvian cistern is formed by the posterior part of the orbital gyri and the lateral part of the anterior perforated substance in a superficial level and leads into the depth of the anterior limiting sulcus of insula on its deep part. Its inferior wall is formed by the planum temporale, which is positioned on the superior surface of the anterior part of the temporal lobe, and uncus. While the lateral, superior and inferior limits of this space are marked by recognizable neural structures, that can be easily pinpointed and followed using other methods of study, its medial limit is purely arachnoidal and formed by the medial sylvian arachnoidal membrane. This arachnoidal wall separates the sphenoidal part of the sylvian cistern from the main cisternal compartment at the anterior incisural space, which is the carotid cistern.

The proximal sylvian membrane is therefore the true medial limit of the sylvian cistern and its arachnoidal boundary separating the sylvian and carotid cisterns. The medial sylvian membrane surrounds the MCA just a few millimeters lateral to its origin at the internal carotid artery (ICA) and has been shown to be thin and incomplete. It was absent in 18% of specimens examined (2). When present, the medial sylvian membrane attaches inferiorly to the anterior surface of the uncus and blends superiorly into the olfactory membrane, which follows the olfactory tract. The medial limit of the sylvian cistern is therefore the most challenging of all the limits of this cistern to translate into auxiliary studies. The quest for a meaningful surrogate limit for the sylvian cistern, useful to determine its beginning in neuroimagiological studies is the focus of this report.

Methods

Because the arachnoidal membranes identified in surgery cannot usually be seen in preoperative imaging, cisternal studies using imagiological images have relied on their neural and vascular limits (1,2,5). Methods of estimating the origin of the sphenoidal segment of the sylvian cistern in imagiological studies may include a) the use of the carotid bifurcation or b) the posterior projection of the olfactory sulcus.

This preliminary study was conducted to assess the feasibility of using the sagittal plane traced from the posterior portion of the olfactory sulcus to define the medial boundary of the sylvian cistern. From an anatomical standpoint, this boundary coincides with the limit of the portion of the anterior perforated substance that forms the roof of this part of the cistern. If a consistent relationship exists between this plane and the carotid bifurcation, this landmark could be used as an alternative in non-contrast imaging studies.

We used a series of 10 contrast-enhanced T1-weighted brain magnetic resonance imaging (MRI) scans with a slice thickness of 1 mm. All selected scans were reviewed and showed no radiological evidence of neurological abnormalities. Each MRI scan was evaluated bilaterally, with both cerebral hemispheres analyzed independently, resulting in a total of 20 sides studied. The study was approved by the institutional ethics committee (CAAE 79008824.9.0000.5208).

The selected MRI datasets were processed using the 3D Slicer software (version 5.8.1 (revision 33241), March 2025). 3D slicer is a free and open-source software platform developed through grants from the U.S. National Institutes of Health (NIH).

Results

Among the analyzed scans, the sagittal plane traced from the posterior portion of the olfactory sulcus coincided with the bifurcation of the internal carotid artery in 19 sides (95%) (Figure 1)

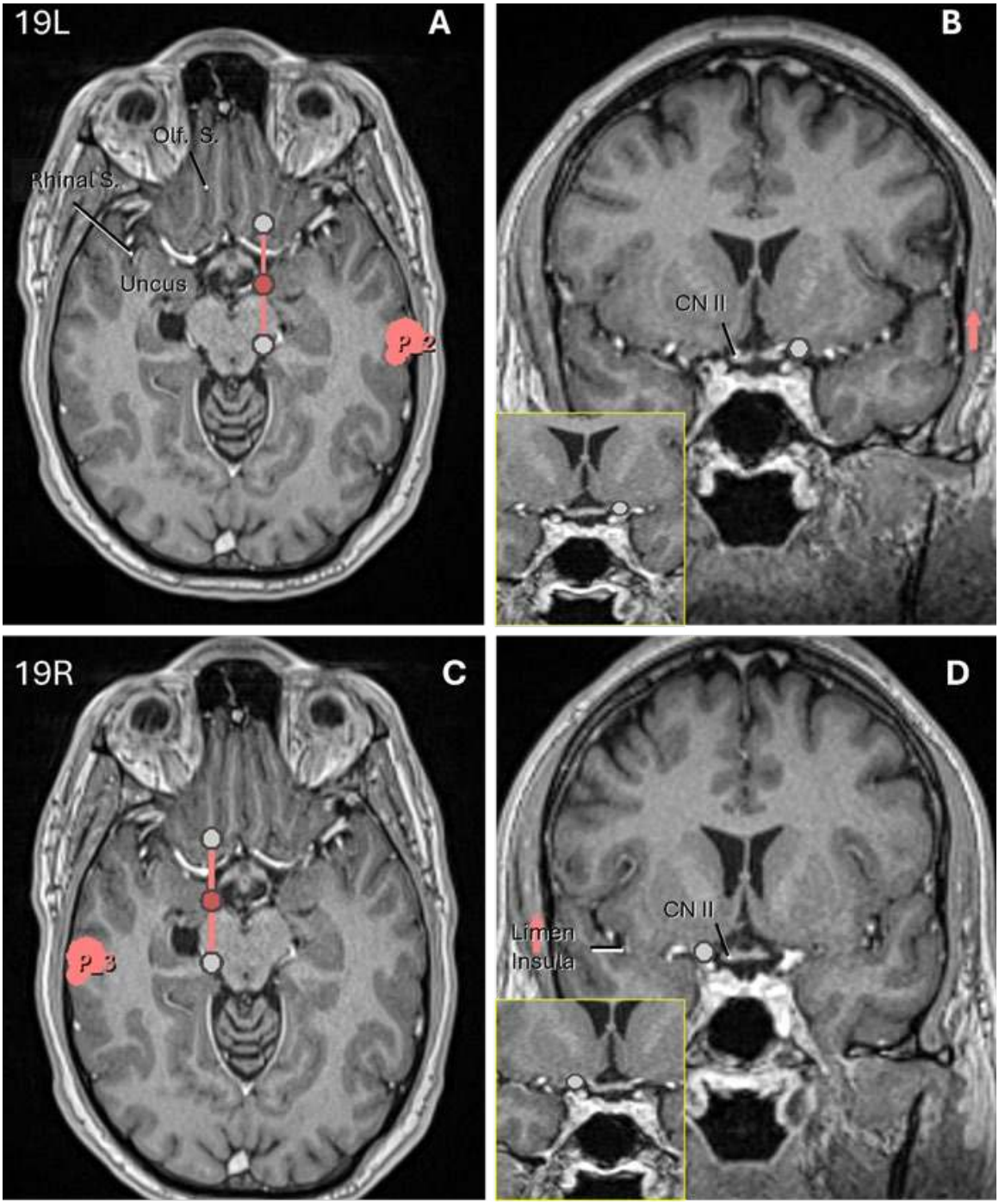

Figure 1. Left (A and B) and right (C and D) MRI scans of patient 19. The sagittal plane was plotted using the posterior part of the olfactory sulcus as seeing on the axial scans (A and C). The coronal images (B and D) revealed that this plane was coincident with the carotid bifurcation (see enlarged inserts). It is noteworthy that the sagittal plane projected from the posterior portion of the olfactory sulcus coincide also with the medial uncal apex and the lateral mesencephalic sulcus. CN: Cranial Nerve; S.: Sulcus; Olf.: Olfactory.

In only one side (patient 11, right side), the sagittal plane traced from the olfactory sulcus did not coincide with the bifurcation, being medially displaced by 7.5 mm. In this case, the carotid bifurcation was observed to be laterally deviated and within the sphenoidal portion of the sylvian cistern (Figure 2).

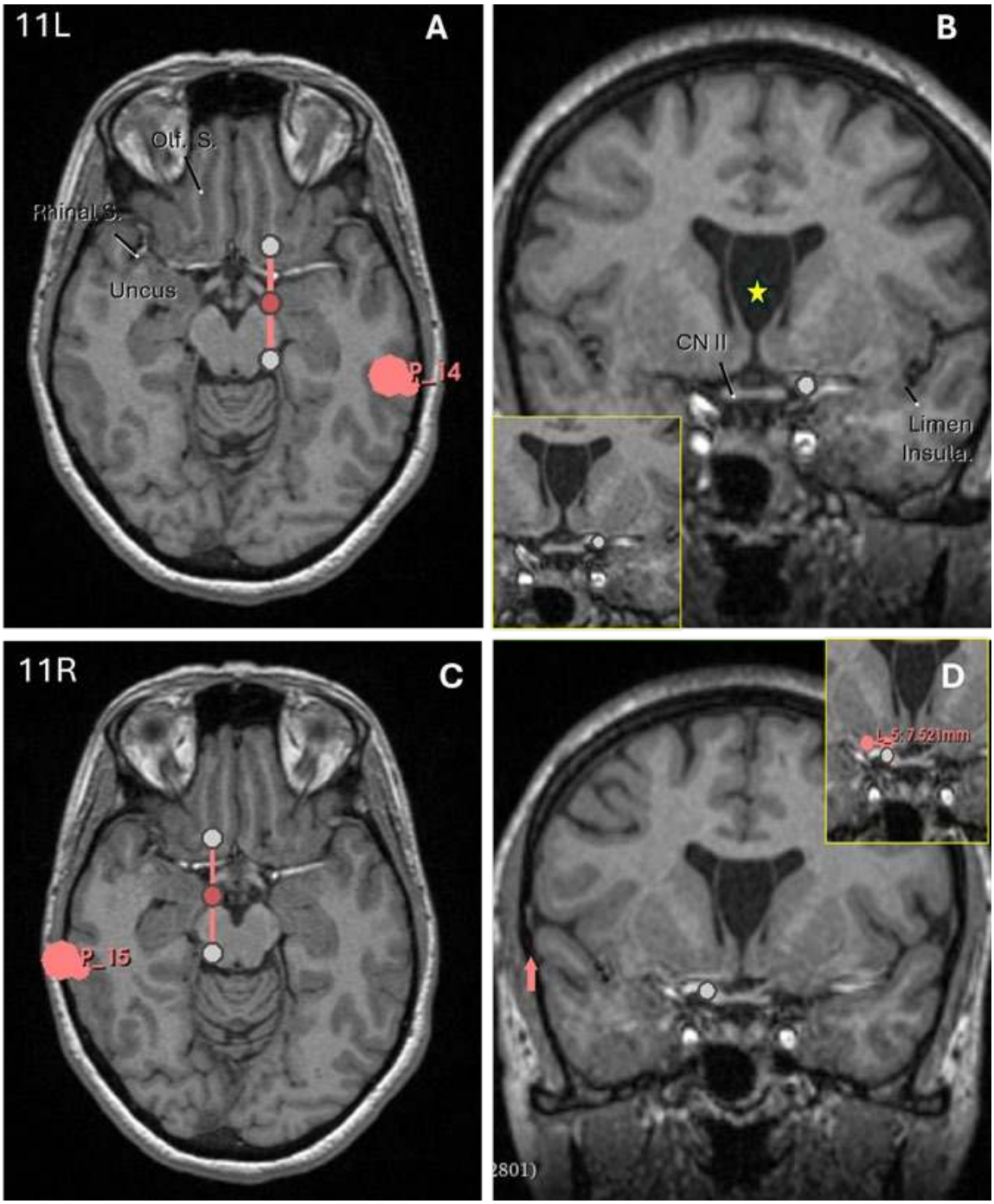

Figure 2. Left (A and B) and right (C and D) MRI scans of patient 11. The sagittal plane was plotted using the posterior part of the olfactory sulcus as seeing on the axial scans (A and C). Although the coronal image on the right (B) revealed that this plane was coincident with the carotid bifurcation, on the left this plane led to a point 7.42mm medial to that. The alignment of this sagittal plane with the medial apex of the uncus and the lateral mesencephalic sulcus is also seen here. CN: Cranial Nerve; S.: Sulcus; Olf.: Olfactory. Yellow Star: Cavum septum pellucidum.

Additionally, the plane traced from the posterior portion of the olfactory sulcus coincided with the apex/anterior surface of the uncus and with the lateral mesencephalic sulcus (Figures 1 and 2), two other easily identified landmarks either in surgery or in imagiological studies.

Our findings suggest that the sagittal plane traced from the posterior portion of the olfactory sulcus can be used as a surrogate marker to determine the medial boundary of the sphenoidal portion of the sylvian cistern when the carotid bifurcation is not visualized, or in combination with it.

Discussion

Dissection within the arachnoidal compartments is the hallmark of the microneurosurgeon (1), who works in vivo, within the brain, located into the skull and bathed by CSF, using magnification and extra-illumination (of either the microscope or the endo or exoscope). All other methods of study, either imagiological/radiological or anatomical/pathological, will not preserve in full the required above-mentioned conditions for recognition of these delicate membranes to allow proper study, but may help track surrogate markers as the neural and vascular elements that give attachment or are located adjacent to the arachnoidal walls of these cisterns, and in this way favor translational knowledge that can be useful in interpreting preoperative data and its application during surgery. Nevertheless, even when dealing with the arachnoidal membranes during a microsurgical dissection, these transparent, delicate sheaths are best seen when apposed or grouped together - as usually happens at points where the cisterns meet.

The carotid bifurcation is the major crossroad for the cisterns at the anterior tentorial space. Just under the anterior perforated substance - which forms the neural roof of those spaces (6) - the carotid, lateral extension of the lamina terminalis, sphenoidal segment of sylvian and olfactory cisterns meet on each side. This anatomical fact is not always realized by surgeons when reaching the carotid bifurcation, because the anterior perforated substance is located in his/her retroview (Figure 3). In the center of this collective space is the carotid cistern. The proximal sylvian membrane is the arachnoidal boundary separating the carotid and sylvian cisterns and encompasses the proximal M1 segment, while the carotid cistern separates from the lateral extension of the lamina terminalis cistern by another arachnoidal sheath called the lateral lamina terminalis membrane that also surrounds A1 just after its origin. Postero-medially the olfactory cistern and its olfactory membrane, identifiable in all specimens studied (2), leads into the carotid cistern – an anatomical notion frequently used when surgeons need to quickly reach the carotid cistern in swollen and angry, post-subarachnoid hemorrhage brains. The olfactory membrane extends from the posterior orbital gyri and below the olfactory tract to the posterior part of rectus gyrus and laterally, it blends with the proximal sylvian membrane (2).

The use of the carotid bifurcation to determine the medial limit of the sylvian cistern is based on the knowledge that the medial sylvian membrane surrounds M1 a few millimeters from its origin, making this the landmark of choice whenever contrast has been applied. However, it is important to understand that when a tortuous bifurcation is present, as seen in elder patients with dolico-ectatic vessels, the arachnoidal sheets may be displaced and dislodged with the artery and differences may be found in estimating the sylvian cistern limit and volume by adopting this method. In this study, a laterally deviated carotid bifurcation exemplified such a situation (Figure 2). Furthermore, using the carotid bifurcation itself or a given distance from the bifurcation along the initial M1 segment as a surrogate for the medial limit of the sylvian cistern may be problematic in non-contrast enhanced studies.

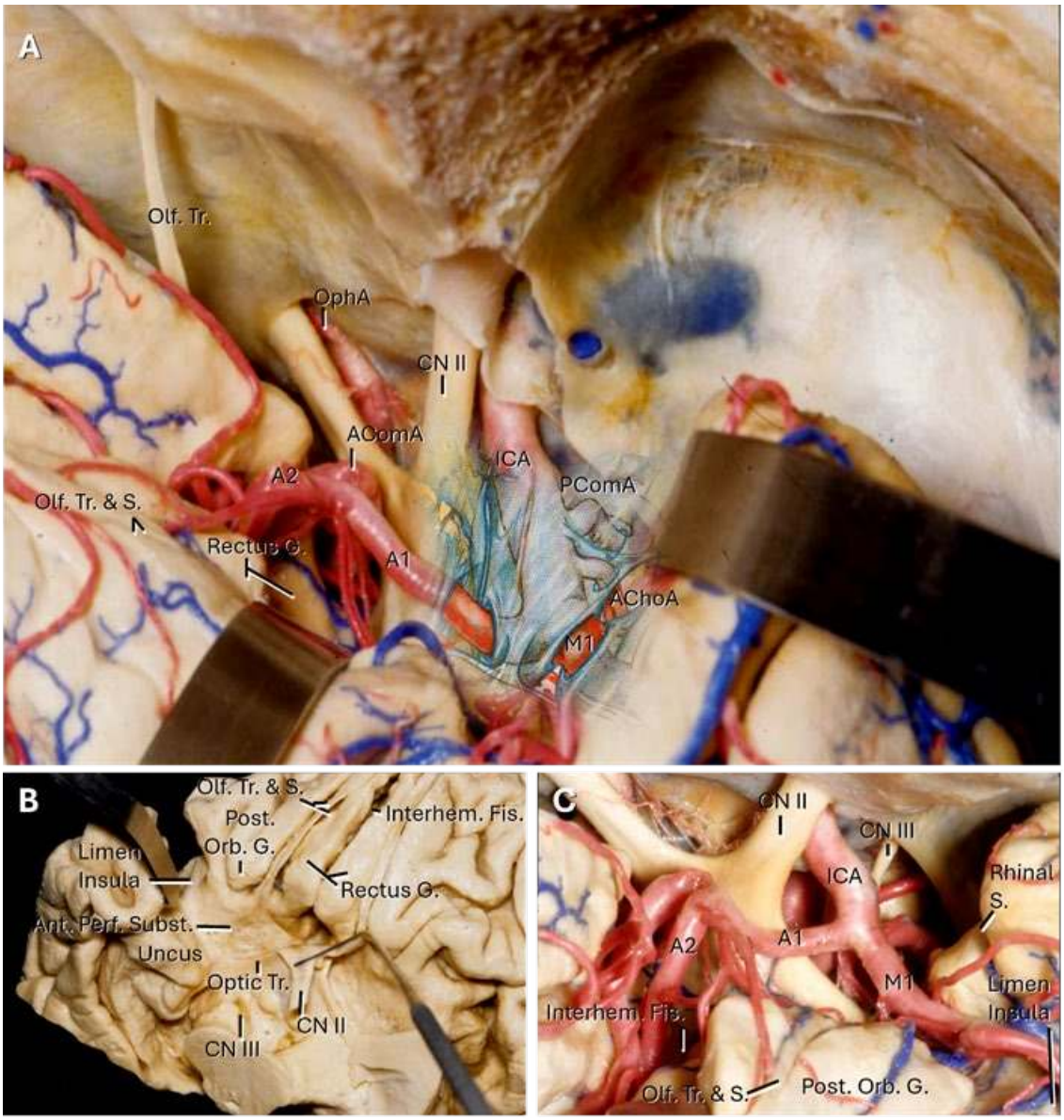

Figure 3. A. Microsurgical dissection of a cadaveric injected specimen (CM) simulates a pterional, transylvian approach to the carotid bifurcation. Over it, an artistic rendering of the arachnoidal layers (part of a drawing by Mr. Peter Roth - medical illustrator to Prof. Yasagil) was merged. This allows one to understand the arachnoidal walls of the cisterns gathering at the carotid bifurcation, as these transparent, delicate sheaths are best seen when apposed or grouped together. The carotid bifurcation, a major crossroad for the cisterns at the anterior tentorial space, is located under the anterior perforated substance - which forms the neural roof of those spaces. The carotid cistern, the lateral extension of the lamina terminalis cistern, the sphenoidal segment of sylvian and olfactory cisterns all meet at this point - on each side. This anatomical fact is not always realized by surgeons when reaching the carotid bifurcation, because the anterior perforated substance is located in his/her retroview. B. Same region as in A but now seen from the opposite (anatomical) direction. The roof of this space is formed by the anterior perforated substance. The anterior perforated substance and its anterior limits – the olfactory striae, are located at a higher level, a fact that also contributes for them not being devised when the patient is in a surgical position (compare with C), where only the posterior part of the rectus gyrus and the posterior orbital gyrus are seen. The neural limits of the sphenoidal compartment of the sylvian fissure coincide, in part, with the limits of the anterior perforated substance. Superiorly, it is related to the lateralmost part of the anterior perforated substance and the posterior orbital gyrus and leading in the depth to the anterior limiting sulcus of insula. Its lateral limit is the limen insula, while its inferior limit is the temporal pole and - medial to the rhinal sulcus, the uncus. Postero-medially, the anterior perforated substance meets the optic tract, while anteromedially it continues into the interhemispheric fissure, contrarily, the medial limit of the sphenoidal segment of the sylvian cistern is purely arachnoidal and formed by the medial sylvian membrane. C. Same specimen as in A. The interhemispheric fissure has been opened and a more medial view within the carotid bifurcation area obtained. The olfactory tract lies at the olfactory sulcus. Please notice the relationship of the posterior part of the olfactory tract and sulcus to the carotid bifurcation and the anterior perforated substance on B. A1: First segment of anterior cerebral artery; A2: Second (or post communicating) segment of anterior cerebral artery, AComA: Anterior communicating artery; AChoA: Anterior choroidal artery; Ant.: Anterior; CN: Cranial Nerve; Fis.: Fissure; G.: Gyrus, Gyri; ICA: Internal cerebral artery; Interhem.: Interhemispheric; M1: First segment middle cerebral artery; Orb.: Orbital; Olf.: Olfactory; PComA: Posterior communicating artery; Perf.: Perforating; Post.: Posterior; S: Sulcus; Subst.: Substance; Tr.: Tract.

In those cases, the olfactory sulcus might be applied. The olfactory sulcus is a readily identified landmark a) on the basal surface of the brain either in cadaveric specimens - where it is related to the overlying olfactory tract; b) in surgery, where it is marked by presence of the olfactory tract and cistern that will join the carotid cistern just under the anterior perforated substance; as well as c) in neuroimaging studies (either CT or MRI). The olfactory sulcus is the lateral limit of the rectus gyrus and separates this gyrus and the interhemispheric fissure just medial to it, from the laterally located orbital gyri, on the basal surface of the brain. According to Ono (7), whose study used 25 autopsy specimen brains, the posterior end of the olfactory sulcus was 7mm (right side) and 8mm (left side), on average, lateral to the medial border of the hemisphere and its depth ranged on average between 6mm (left side) and 6.5mm (right side), being at the posterior level, perpendicular to the horizontal plane and pointing towards the frontal horn of the lateral ventricle. The posterior end of the olfactory sulcus was not seen to extend laterally in 52% (right side) and 28% (left side) of the hemispheres studied, but when it did, in most cases, a short lateral extension (inferior to 10mm) was present in 48% (left side) and 20% (right side) of specimens studied. Ono and Rhoton (6,8) used the posterior projection of the olfactory sulcus to separate the anterior perforated substance into medial and lateral parts, but this was done to analyze the structures directly crossing through this area, and not in estimating the medial limit of the sylvian cistern. Nevertheless, its use can be extended, not only because the lateral part of the anterior perforated substance is the neural roof of the sphenoidal part of the sylvian cistern but also because the olfactory membrane is continuous inferiorly with the medial sylvian membrane.

Although the number of MRI used is small, the observations made here repeated consistently. Also, other interesting anatomical relationships of the sagittal plane projected from the posterior part of the olfactory sulcus not previously anticipated could be found. Both types of findings will benefit from further observation.

In conclusion, the sagittal plane projected using the posterior olfactory sulcus seems to be a reasonable landmark for the medial limit of the sylvian cistern in contrast-enhanced as well as non-contrast-enhanced studies.

References

1. Yasargil M. Microneurosurgery. 1st ed. New York, editor. Vol. IVa-IVb. New York: Gerog Thieme Verlag; 1994. 1–396 p.
2. Inoue K, Seker A, Osawa S, Alencastro LF, Matsushima T, Rhoton AL. Microsurgical and endoscopic anatomy of the supratentorial arachnoidal membranes and cisterns. Neurosurgery. 2009 Oct;65(4):644–64. Doi: 10.1227/01.NEU.0000351774.81674.32
3. Wen HT, Rhoton AL, De Oliveira E, Castro LHM, Figueiredo EG, Teixeira MJ. Microsurgical anatomy of the temporal lobe: Part 2-sylvian fissure region and its clinical application. Neurosurgery. 2009;65(6 SUPPL. 1). Doi: 10.1227/01.NEU.0000336314.20759.85
4. Gibo H, Carver CC, Rhoton AL, Lenkey C, Mitchell RJ. Microsurgical anatomy of the middle cerebral artery. Vol. 54, J Neurosurg. 1981. Doi: 10.3171/jns.1981.54.2.0151
5. Matsuno H, Rhoton AL, Peace D. Microsurgical Anatomy of the Posterior Fossa Cisterns. Neurosurgery [Internet]. 1988 Jun 1;23(1):58–80. Doi: 10.1227/00006123-198807000-00012
6. Rhoton Jr. A, Ono M. Microsurgical anatomy of the region of the tentorial incisura. In: Wilkins R, Rengachary SS, editors. Neurosurgery. 2nd ed. New York: McGraw Hill; 1996. p. 897–915.
7. Ono M, Kubik S, Abernathey C. Atlas of Cerebral Sulci. NewYork: Thieme; 1990. 218.
8. Ono M, Rhoton AL, Barry M. Microsurgical anatomy of the region of the tentorial incisura. J Neurosurg. 1984;60:365–99. Doi: 10.3171/jns.1984.60.2.0365

Florisvaldo Jose Morais Vasconcelos Junior
https://orcid.org/0009-0003-0605-1044
Marcelo Moraes Valença
https://orcid.org/0000-0003-0678-3782
Carolina Martins
https://orcid.org/0000-0002-0197-3520

Acknowledgments: The authors thank Dr. Ronaldo Lessa for providing images used in this study.
Authors' contributions: FJMVJR, MMV, CM: conceptualization, methodology, validation, formal analysis, investigation, resources, data collection; FJMVJR, CM: Writing — original draft, writing — review & editing and visualization; CM: Image Treatment; MMV, CM: supervision.
Obs: FJMJr. and CM contributed equally as first authors in this paper
Conflict of interest: There are no conflicts of interest.
Funding: The first author received a federal grant (CNPq) during the period of preparation of this manuscript .