Neurological Surgery and Anatomy 2025, 2(2): 50-58, e-ISSN: 2966-0696
DOI: 10.37085/nsa.2025.9

Original

What happens to the hippocampus during uncal herniation?

Carolina Martins[1,2], Pedro Luna Carvalho[1], Luiza de Sá Ferreira Araújo[1], João Victor Melo Soares[1], Roberto Vieira de Mello[2], Luciano Tavares Montenegro[2], Marcelo Moraes Valença[2], Antonio Cavalcanti de A. Martins[1,3]

[1]Medical School of Pernambuco, Recife, Pernambuco, Brazil
[2]Federal University of Pernambuco, Recife, Pernambuco, Brazil
[3]Professor Fernando Figueira Institute of Integral Medicine, Recife, Pernambuco

Introduction
Uncal herniation is a well-known phenomenon linked to unchecked intracranial hypertension and associated with specific neurological syndromes. Its understanding is critical for medical students as it can the cause or be associated with death. The hippocampus, formed by cornus ammonis and dentate gyrus, is part of the limbic lobe, and its anatomical knowledge, a crucial part of the study of several diseases, including Alzheimer's.
Objective
To describe hippocampal anatomy using microsurgical anatomy images and Anatomage 10.0 data, evaluating the peri-mortem effects of uncal herniation.
Materials and Methods
Microsurgical dissection of formalin-fixed cadaveric-human brains exposed limits and parts of the hippocampal formation. Anatomage Table 10.0 is a technological tool for anatomy learning, which provides an interface for interaction with digitized data from human cadaveric donors. Both types of images were combined to allow identification of parts of hippocampal formation.
Results
Five cadaveric donors in Anatomage 10.0 showed unilateral or bilateral signs of uncal herniation. Amount of herniated tissue was inversely related to donor's age, suggesting age-related atrophy and/or different pathologies leading to death. Anatomage 10.0 allows layers of anatomical structures to be peeled back, highlighting the anatomical relationships under different degrees of uncal herniation.
Conclusion
The hippocampus is expected to be affected during uncal herniation, but this understanding is seldom reached by medical students exploring the limbic system. Anatomage 10.0 can expedite this realization, stimulating students to acquire more detailed anatomical terminology for adequately describing what they are seen. This contributes to deeper, clinically meaningful understanding of the brain.

Keywords: Brain, Humans, Hippocampus, Limbic lobe, Intracranial hypertension

Edited by:
Juliana Ramos de Andrade

Carolina Martins
maria.cmlima@ufpe.br

Received: June 10, 2025
Revised: August 31, 2025
Accepted: August 31,2025

© Copyright 2025

Introduction

Uncal herniation is a well-known phenomenon related to unchecked intracranial hypertension. It is associated with - at least - three well-defined neurological syndromes. Because of its clinical importance, uncal herniation is an obligatory part of the curriculum for medical students. Besides, uncal herniation can be the main cause or an associated event - present at the moment of death; and the "tentorial groove" is a common finding engraved into postmortem brain specimens. The term hippocampus can be applied to the *cornus ammonis*, or to its combination with the dentate gyrus, which forms the hippocampal formation. The head of the hippocampus abuts the cortical surface of the brain at the posterior surface of uncus. As part of the limbic lobe, the anatomical understanding of the hippocampus and its parts is paramount in paving a future understanding of several diseases, including Alzheimer's.

Objective

This study describes the anatomy of the hippocampus using combined microsurgical anatomical images and Anatomage 10.0 data and evaluates the peri-mortem effects of uncal herniation on these structures.

Methods

The study was registered at Medical School of Pernambuco, Brazil. It was approved by the IRB and Ethics Committee (CAAE 81080724.9.0000.5569). Microsurgical dissection of formalin-fixed, silicone-injected, cadaveric-human brains exposed the limits and parts of the hippocampal formation. These dissections were undertaken during a period of over a decade, at the George Schrader Colter International Microneurosurgical Anatomy Lab – US, under supervision of Professor Albert Rhoton Jr. and are now part of the Rhoton Collection (1). These were complemented with dissection of formalin-fixed, non-injected, cadaveric-human brains from the Postmortem Examination Department at Federal University of Pernambuco (UFPE) and Anatomage© Table 10.0 data.

Anatomage© Table 10.0 (Anatomage Inc., San Jose, CA) is a technological tool devised to provide an interface through which students can interact with digitalized data from human cadaveric donors. It is the result of an international venture with collaboration with the Stanford Clinical Anatomy Department (2). Its 10.0 version houses acquired multiaxial imaging of the body of five donors, together with corresponding imagiological and histological imaging. Its functionalities allow selection, enlargement, rotation, removal ("electronic dissection"), replacement, and multiplanar reconstruction of anatomical data.

Results

The brains of five cadaveric donors included at Anatomage version 10.0 presented unilateral or bilateral signs of uncal herniation. The amount of herniated tissue varied but seemed inversely related with the age of the donor, possibly pointing to atrophic brain changes related to age and the pathology that led to death. Because Anatomage 10.0 allows peeling layers of anatomical structures it relates to the "see-through" concept of neuroanatomical learning, making its use a fortuitous moment to highlight the relationships between the uncal herniation and the anatomy of its inner structures, including the hippocampus (Figures 1-3).

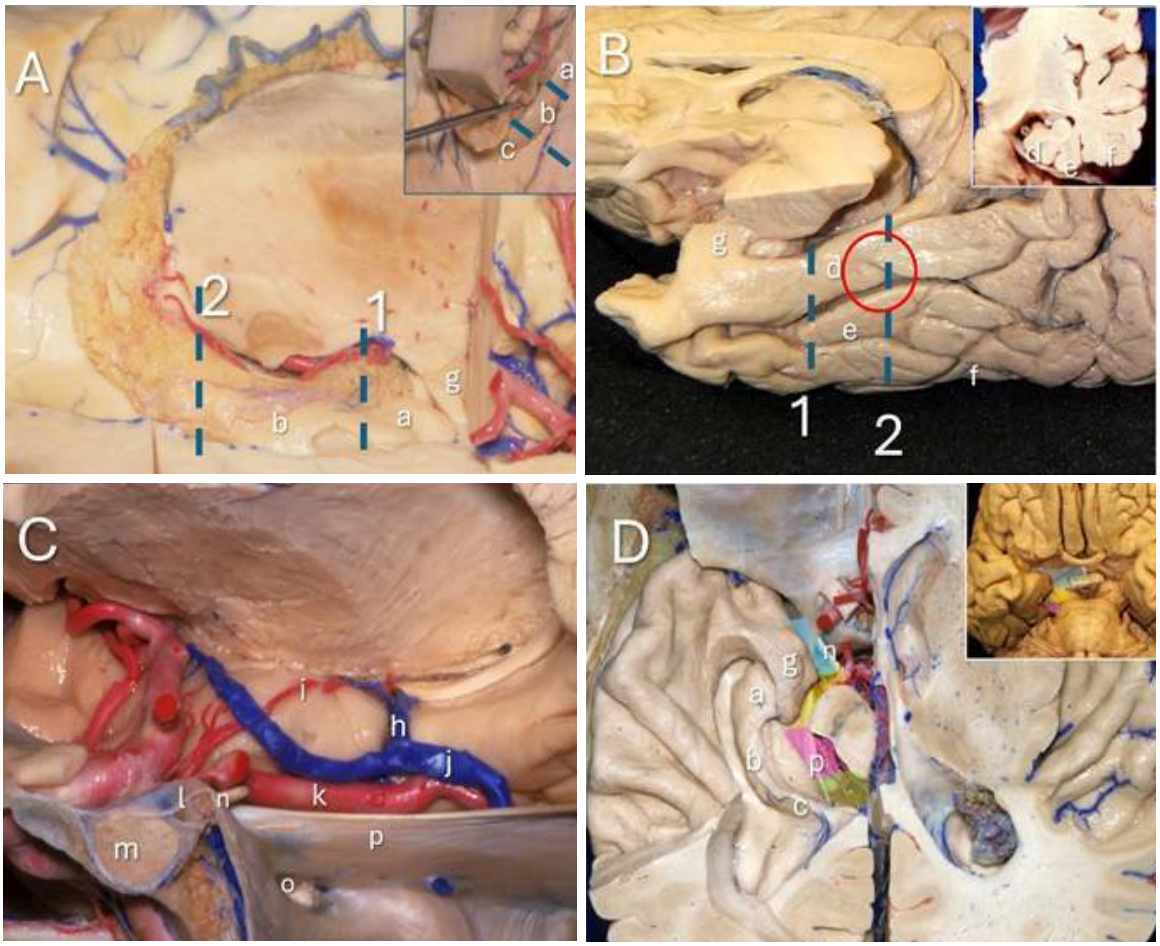

Figure 1. A. Right hippocampus exposed through the ventricle. Dotted line 1: Anatomical limit between head and body of hippocampus. It coincides with inferior choroidal point on the ventricular side, and the posterior border of uncus (B & C) and the posterior part of the crural cistern (yellow on D), on the cisternal side. Dotted line 2: Anatomical limit between body and tail of hippocampus. It coincides with the smooth curvature of hippocampus to reach the anterior wall of atrium. See insert at A: The choroid plexus is elevated to expose the curved transition between body and tail of hippocampus. B. Cisternal view of the uncus and parahipocampal gyrus. Although the hippocampus (and amygdala) cannot be readily seen, their inner location can be devised by regional landmarks. The head of the hippocampus corresponds to the posterior surface of the uncus and is anterior to line 1. Its body extends posteriorly to the parahipocampal sulcus (red circle) (3). A surrogate marker to line 2 is the inferiormost part of the lateral mesencephalic sulcus and vein (useful when coming into this area from a subtemporal transventricular perspective) or 1 cm anterior to the splenium of corpus callosum - which is (in itself) on average 6cm from the occipital pole (useful when coming into this area from an interhemispheric occipital or infratemporal transtentorial perspective). C. The cisternal aspect of these gyri help form the walls of the cisternal spaces around the midbrain, which comprise specific vessels and neural segments. D. The left hippocampus has been dissected to explore its ventricular and cisternal relationships. Blue: Carotid cistern, Yellow: Crural cistern, Pink: Ambient cistern, Green: Quadrigeminal cistern. See insert: The gradual anterior to posterior occupation of the cisternal space by the surfaces of uncus and the parahipocampal gyrus help explain the progressive symptomatology of Plum and Posner's (4) "early" and "late" uncal herniation syndrome. Beyond the rostro-caudal degeneration there is an anteroposterior wringing of the brainstem with anatomical and clinical correlates that become important in understanding the postherniation syndromes presented by survivors (and planning for their rehabilitation). *a: head of hippocampus (and corresponding posterior surface of uncus on the cisternal side), b: body of hippocampus, c: tail of hippocampus, d: parahipocampal gyrus, e: fusiform gyrus, f: inferior temporal gyrus, g: anterior surface of uncus (and amygdala on the ventricular side). h: inferior ventricular vein, i: anterior choroidal artery (h and i both passing through the inferior choroidal point – a landmark that also helps to locate and divide the hippocampus during vascular studies), j: basal vein of Rosenthal, k: posterior cerebral artery, l: posterior clinoid process, m: hypophyseal gland, n: CNIII, o: CNV, p: tentorial edge (the shape of the tentorial incisura should be considered when understanding the uncal herniation syndromes).*

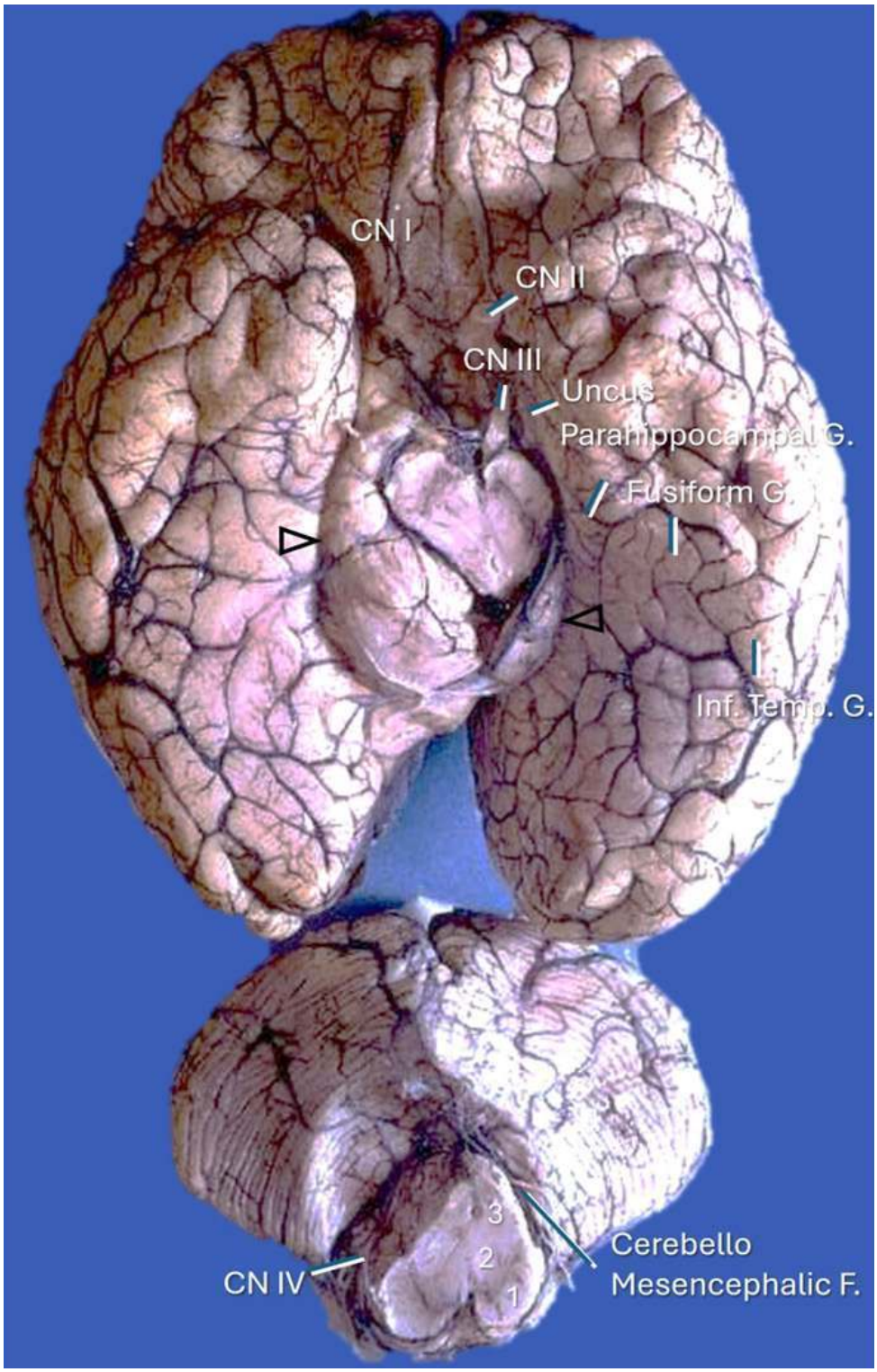

Figure 2. Formalin fixed, non-injected cadaveric brain, harvested during postmortem examination. The midbrain has been sectioned to expose the basal surface of the brain and the tentorial surface of the cerebellum. Bilateral tentorial notches (open arrowheads) are seen, especially on the right side, were a complete horizontal uncal herniation is seen compressing the base of the peduncle (1), the tegmentum (2) and tectal parts of the midbrain (3). Note that the right parahipocampal and fusiform gyri have been dislocated medially and downward, to compress vertically the posterior lip of the cerebellomesencephalic fissure formed by the wing of the central and the quadrigeminal lobes of the cerebellum.

Neurological Surgery and Anatomy

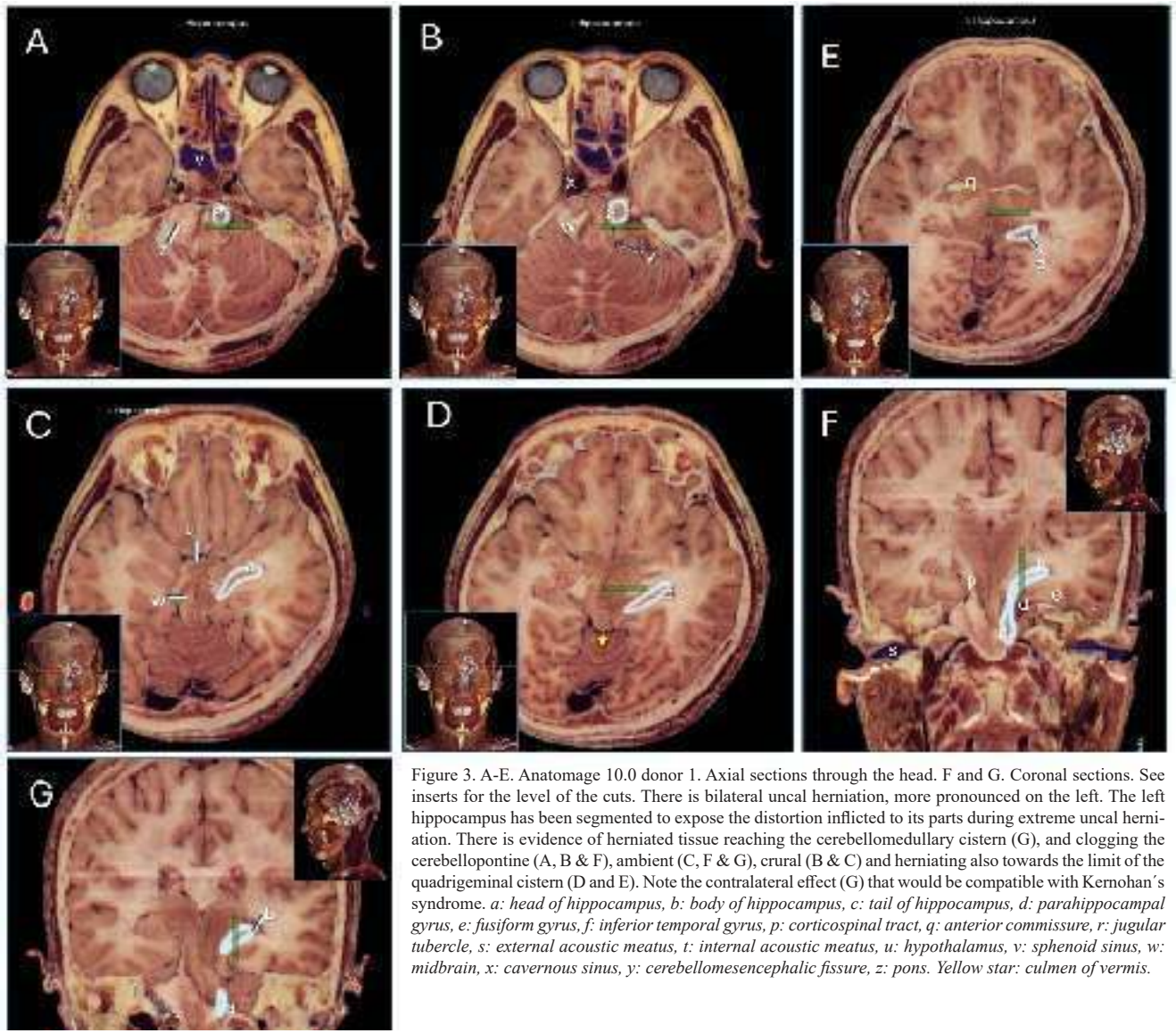

Figure 3. A-E. Anatomage 10.0 donor 1. Axial sections through the head. F and G. Coronal sections. See inserts for the level of the cuts. There is bilateral uncal herniation, more pronounced on the left. The left hippocampus has been segmented to expose the distortion inflicted to its parts during extreme uncal herniation. There is evidence of herniated tissue reaching the cerebellomedullary cistern (G), and clogging the cerebellopontine (A, B & F), ambient (C, F & G), crural (B & C) and herniating also towards the limit of the quadrigeminal cistern (D and E). Note the contralateral effect (G) that would be compatible with Kernohan´s syndrome. *a: head of hippocampus, b: body of hippocampus, c: tail of hippocampus, d: parahippocampal gyrus, e: fusiform gyrus, f: inferior temporal gyrus, p: corticospinal tract, q: anterior commissure, r: jugular tubercle, s: external acoustic meatus, t: internal acoustic meatus, u: hypothalamus, v: sphenoid sinus, w: midbrain, x: cavernous sinus, y: cerebellomesencephalic fissure, z: pons. Yellow star: culmen of vermis.*

Discussion

Care must be exercised to differentiate uncal and tentorial herniation. Tentorial herniation is the most common and important form of brain herniation. It can be divided in descending, - when imbalance between the pressures within the supra- and infratentorial compartments cause the uncus and parahippocampal gyrus to prolapse downward through the incisura – and an ascending form, caused by infratentorial mass pushing the cerebellum and brainstem upward through the incisura (5). The type of herniation therefore depends on the site of origin and rate of ascent of the intracranial pressure (directly influencing the clinical syndrome presented) and the size and shape of the incisura (6). Uncal herniation thus refers to the downward displacement of the uncus and parts of the parahipocampal gyrus into the *incisura tentorii* and corresponds to but one type of tentorial herniation (Figure 2).

The tentorium slopes downward from its apex, located at its junction with the cerebral falx to its anterior attachments at the clinoidal processes. Its free edge limits a roughly triangular area, the *incisura tentorii* (tentorial incisura). The incisural space is divided into an anterior, middle and posterior incisural spaces, according to its position in relation to the brainstem (5,6).

Pending on the morphology of the tent, more or less of the cerebellum (when seen from above), uncus and parahippocampal gyrus (when seen from below) may be normally visible between the midbrain and the free edge. This amount varies from none\minimum if the free edge hugs the midbrain; to a large amount if the incisura is broad and incompetent. The distance from the free edge to the midbrain to range from null to 6.6 mm, being on average 0.7 mm (5). The width of the incisura varied between 26-35 mm, being on average 29 mm (6,7) and its length from the apex to dorsum, 46-67 mm, being on average 52 mm (6). If the incisura is wide and\or there is a low position of the anterior portion of the free edge, herniation is facilitated (5,6).

Usually, the junction between the pons and midbrain is situated around the level of the edge. Ono et al. (6) measured the height between the midpoint at the lateral mesencephalic sulcus and the free edge to find it to vary from 3 mm below to 2.5 mm above it, being on average 0.2 mm below. The bulbous prominence on the anterior part of the uncus hangs over the free edge, above the oculomotor trigone. It is this part of the uncus that gets notched or grooved by the tent on the tentorial notch. Tentorial notch or groove is the name given to the marking left at the uncus by the tentorial edge and a recognized postmortem feature. This marking should not be confused with the sulci present at uncus (8). Recognizable at the basal surface of post-mortem human cadaveric specimens (Figure 2), the tentorial groove is, on average, 9 mm long and 4 mm lateral to the uncus tip (3). This usually disappears at the level of the middle incisura space because the free edge is often elevated and closer to the midbrain at this point, to - sometimes - reappear at the level of the posterior incisural space (Figure 2) , marking the posterior part of the parahippocampal, isthmus of the cingulate, and lingual gyri (5,6).

Following a spectrum of progressively greater tissue displacement and according to the incisural space where the tissue herniates, the uncal herniation has be classified into anterior, posterior and complete types (5). The anterior type of uncal herniation is the most frequently, seen in neuroimaging of critical patients and at *post-mortems*; with the uncus herniating into the crural and interpeduncular cisterns. The midbrain is displaced in a horizontal direction and may rotate if the compression is off centre. Opening of the ipsilateral ambient cistern will allow further filling with brain tissue, contrary to what happens at the contralateral ambient cistern, which not only narrows but where the cerebral peduncle can also be encroached towards the opposite tentorial edge. The complete herniation presupposes filling of the cisterns around the midbrain (Figures 1D and 2).

The horizontal displacements just described are the anatomical basis for the uncal herniation syndrome (ipsilateral III nerve palsy and contralateral motor deficit) and the Kernohan syndrome (isolated or additional contralateral III nerve palsy and ipsilateral motor findings). The torsional component can be responsible for stretching or severing of the penetrating vessels and intra-axial vascular damage that may present as central or locked-in syndromes (see Tables 1 and 2). Further progression of this displacement from this point will occur in a more vertical direction, but a downward displacement of structures towards the cerebellomedullary cistern to the level of the jugular tubercle – as presented in Figure 3 is seldom seen and is an opportunity created by the anatomical protocol for *post-mortem* scanning of donors of Anatomage Table version 10.0.

Whenever the rostro-caudal degeneration process reaches the midbrain, it progresses rapidly - and unless immediate, corrective action is taken to treat the cause of the intracranial pressure imbalance between the supra and infratentorial cranial compartments - brain death will issue.

The clinical syndromes mentioned above, and the postherniation syndrome that will affect survivors – the ones whose timely treatment could rescue from these extremes conditions of elevated intracranial pressure, have been extensively detailed by Plum and Posner (4) more than half a century ago, including the less frequent and conspicuous signs - that do not cease to surprise modern authors (9–11).

Neurological Surgery and Anatomy

Table 1. Hallmark findings in uncal herniation syndromes

Syndrome	Hallmark Clinical Findings	Notes
Uncal herniation or tentorial notch syndrome	Reduced level of consciousness	As the diencephalic structures may be relatively preserved when compared to the mesencephalic ones, the reduced level of consciousness is neither the first of the most striking signal of this syndrome. Patients can be awake (10), drowsy or comatose.
	Ipsilateral pupillary dilation	A "sluggish pupil" - that reacts slowly to light - is the first sign of an impending uncal herniation and may precede the full-blown syndrome by 1-2 hours (4). Examiners may save countless lives by paying attention to this important detail. Oculomotor nerve could be kinked, compressed or it may be stretched if the herniating tissue displaces the midbrain posteriorly. Initially the pupilloconstrictor fibres, concentrated on the superior surface of the nerve are affected. The initial irritating effect manifests itself as pupillary constriction or sluggish fotomotor reflex, but this usually gives way to a paralytic effect with pupillary dilation as the hernia enlarges (5). With progression of the herniation, the somatic fibres of the oculomotor nerve are also affected.
	Ptosis	It is usually present (with palsy of other muscles in the extrinsic ophthalmoplegia) by the time there is a fully enlarged pupil. However, because at this point, most patients are comatose, - it may go unnoticed. It will only call attention if the patient survives - as part of the post-herniation syndrome.
	Contralateral Babinski sign and decerebrate posturing	This is a dynamic finding that may start as asymmetric plantar findings, with no response on the contralateral side. It may progress to decerebrate posturing, by which time the Babinski sign (plantar extension) will be present. If distortion of the contralateral crura cerebri is reached, bilateral pathologic signs are to be expected.
Kernohan notch syndrome or Kernohan-Woltman notch phenomenon	Ipsilateral motor signs Contralateral pupillary dilation	The character of a "false-localizing" syndrome - composed of contralateral mydriasis and ipsilateral motor deficit - is the aspect mostly emphasized in the literature (12), as the isolated result of massive lateral tentorial displacement. However, in practice, these findings may also be interpreted as a spectrum of lateral displacement that will eventually reach the contralateral cistern and vessels coursing through it (potentially less clearly identified by the summation of signs and resemblance to the final pathway of all herniation syndromes) (4). As happens with the ptosis on the post-herniation syndrome - which will only be acknowledged and dealt with in survivors - here the contralateral parkinsonian signs (related to the affection of the substantia nigra), the cerebellar set of signs (related to the involvement of the superior cerebellar artery) and the contralateral visual field loss or cortical blindness (related to the involvement of the posterior cerebral artery) (12) will also compose the post-herniation syndrome.

Table 2. Understanding other signs and symptoms present in complete uncal herniation and post-herniation syndromes.

Syndrome	Clinical Findings	Notes
Unilateral or bilateral abducens syndrome	Paralytic convergent strabismus	Caudal displacement of the brainstem may result in palsy of the abducens nerve by stretching its cisternal segment or strangling around the anterior inferior cerebellar artery (6).
Epileptic syndrome	Mesial temporal lobe epilepsy with anatomical changes seen on neuroimaging	The compression of the uncus, amygdala, parahippocampal gyrus and hippocampal formation against the free edge may cause memory, behaviour and personality changes. Residual scarring of the hippocampus may cause seizures (5).
Pituitary stalk compression syndrome	Diabetes insipidus	The pituitary stalk may be stretched and compressed against the dorsum sellae, causing diabetes insipidus.
Hypothalamic syndrome	Dysautonomia	Distortion and compression of the posterior hypothalamus may cause cardiovascular, respiratory, and thermoregulatory disturbances.
Parinaud syndrome	Vertical gaze paralysis	Compression of the quadrigeminal plate and tectum of midbrain in complete uncal herniation may cause vertical gaze disturbances.
Aqueduct obstruction	Hydrocephalus	Compression and obstruction of the aqueduct causes hydrocephalus and further raises intracranial pressure in the supratentorial compartment, which in turn increases the downward herniation.

Table 1 summarizes the most important chronological aspects of these syndromes, while Table 2 highlights the syndromes that might be present in complete herniations.

Conclusions

Although the hippocampus is expected to be affected during uncal herniation, it is infrequent for a medical student to reach this understanding while studying the anatomy of the limbic system. By using the Anatomage 10.0 not only can this realization be expedited but the regional anatomy can be explored. In order for the student to describe these findings, a more detailed anatomical terminology of this area becomes a necessity, fostering a better, deeper and clinically meaningful understanding of this area of the brain (3,4,12–14).

References

1. Martins C. Rhoton's Lab. World Neurosurg 2016;92. Doi:10.1016/j.wneu.2016.06.035.
2. Alasmari WA. Medical students' feedback of applying the virtual dissection table (Anatomage) in learning anatomy: A cross-sectional descriptive study. Adv Med Educ Pract 2021;12:1303–7. Doi:10.2147/AMEP.S324520.
3. Ono M, Kubik S, Abernathey C. Atlas of Cerebral Sulci. NewYork: Thieme; 1990.
4. Plum F, Posner J. Diagnostico de Estupor e Coma. 2nd ed. Rio de Janeiro: Guanabara Koogan; 1977.
5. Rhoton Jr. A, Ono M. Microsurgical anatomy of the region of the tentorial incisura. In: Wilkins R, Rengachary SS, editors. Neurosurgery, vol. 1. 2nd ed., New York: McGraw Hill; 1996, p. 897–915.
6. Ono M, Rhoton AL, Barry M. Microsurgical anatomy of the region of the tentorial incisura. J Neurosurg 1984;60:365–99.
7. Martins C, Felipe L, Tabarelli P, Campero A, Alencastro LF, Moraes Valença M, et al. Exploring the third ventricular floor anatomy: clinical insights for endoscopic third ventriculostomy. Neurological Surgery and Anatomy 2024;2024:15–21. Doi:10.37085/ns&a.2024.5.
8. Martins C, Quilis Quesada V, Cavalcanti A, Martins A, Moraes Valença M, Wen HT, et al. A handy tool to teach microneurosurgical anatomy of uncus. Neurological Surgery and Anatomy 2024;2024:67–71. Doi:10.37085/ns&a.2024.15.
9. Wijdicks E, Gary M. Transient locked-in syndrome after uncal herniation. Neurology 1999;52:1296–7.
10. Katzir M, Attia M, Sviri GE, Zaaroor M. Uncal herniation in a fully conscious patient - The sliding uncus syndrome. Br J Neurosurg 2015;29:308–9. Doi:10.3109/02688697.2014.977779.
11. Udayakumaran S, Ben Sira L, Constantini S. Chronic uncal herniation secondary to posterior fossa shunting: Case report and literature review. Child's Nervous System 2010;26:267–71. Doi:10.1007/s00381-009-1027-z.
12. Beucler N, Cungi P-J, Baucher G, Coze S, Dagain A, Roche P-H. The Kernohan-Woltman Notch Phenomenon : A Systematic Review of Clinical and Radiologic Presentation, Surgical Management, and Functional Prognosis. Review Article J Korean Neurosurg Soc 2022;65:652–64. Doi:10.3340/jkns.2022.0002.
13. Duvernoy H., Cattin F., Risold P-Y. The Human Hippocampus. 4th Edition. Heidelberg: Springer-Verlag; 2013.
14. Kier EL, Fulbright RK, Bronen RA. Limbic Lobe Embryology and Anatomy: Dissection and MR of the Medial Surface of the Fetal Cerebral Hemisphere. vol. 16. 1995.

Carolina Martins
https://orcid.org/0000-0002-0197-3520
Pedro Luna Carvalho
https://orcid.org/0009-0008-7485-3141
Luiza de Sá Ferreira Araújo
https://orcid.org/0009-0008-1145-9729
João Victor Melo Soares
https://orcid.org/0000-0001-7501-7411
Roberto Vieira de Mello
https://orcid.org/0000-0001-6707-6788
Luciano Tavares Montenegro
Marcelo Moraes Valença
https://orcid.org/0000-0003-0678-3782
Antonio Cavalcanti de A Martins
https://orcid.org/0000-0002-1249-8622

Authors contribution: CM, ACAM: Substantial contributions to the conception of the work; reviewing it critically for important intellectual content, final approval of the version to be published, agreement to be accountable for all aspects of the work. MMV, RVM, LTM: Reviewing the work critically for important intellectual content, final approval of the version to be published CM, PLC, LSFA, JVM, ACAM: Data collection and organization, draft version of the manuscript and literature review.
Conflict of interest: There are no conflicts of interest.
Funding: There was no funding.