Neurological Surgery and Anatomy 2025, 2(1): 17-21, e-ISSN: 2966-0696
DOI: 10.37085/nsa.2025.3

Case Report

Serpentine aneurysm of the middle cerebral artery: Case report

Lívio Pereira de Macêdo[1,2], Bruno Mota[2], Romero Marques[2], José Laercio Júnior-Silva[1,2], Carlos Gustavo Coutinho Abath[2]

[1]Hospital da Restauração, Recife, Pernambuco, Brazil
[2]ANGIORAD, Department of Neurointerventional Radiology, Recife, Pernambuco, Brazil

The serpentine aneurysm is an infrequent vascular anomaly, representing less than 0.1% of all aneurysms. It is defined by a substantial fusiform aneurysm exceeding 25 mm in diameter, frequently exhibiting partial thrombosis and maintaining a serpiginous vascular channel. This condition is associated with high morbidity and mortality rates, presenting considerable therapeutic challenges. Recent advancements in endovascular therapies have transformed the management of serpentine aneurysms, which are now considered the gold standard. These techniques incorporate both reconstructive and obstructive methods, often utilizing parent vessel occlusion testing to achieve favorable patient outcomes. This case report discusses a 39-year-old male presenting with headaches and right-sided transient paresthesia. Imaging, including computed tomography, revealed a partially thrombosed aneurysm in the left middle cerebral artery (MCA) region. Subsequent cerebral angiography confirmed serpentine opacification in the frontal M2 segment, characterized by sluggish flow terminating in a distal parent artery branch. The patient underwent elective embolization following parent vessel occlusion testing, which demonstrated retrograde filling of the cortical branch via a leptomeningeal anastomosis. Embolization involved the use of platinum coils to occlude both the aneurysm and its parent vessel. Postoperative recovery was uneventful, and the patient was discharged two days after the procedure. Understanding the unique angiographic features of serpentine aneurysms is crucial for effective management.

Keywords: Serpentine aneurysm, Fusiform aneurysm, Endovascular management

Edited by:
Carolina Martins

Lívio Pereira de Macêdo
livio21@gmail.com

Submitted: February 21, 2025
Accepted: April 28, 2025
Published online: April 30, 2025

© Copyright 2025

Introduction

The serpentine aneurysm is a rare entity, representing less than 0.1% of cases (1,2). It consists of a giant fusiform aneurysm (greater than 25 mm in diameter) that is partially thrombosed and features a residual serpiginous vascular channel. This condition has a natural history with a high morbidity and mortality rate. With the advancement of endovascular techniques, it is now considered the gold standard in managing these pathologies. They include both reconstructive and destructive techniques with the assistance of parent vessel occlusion testing, and they result in favorable outcomes (3,4).

Objective

To report a case of a patient with a serpentine aneurysm of the left middle cerebral artery (MCA) treated with embolization using platinum coils following balloon occlusion testing of the parent artery.

Case Report

A 39-year-old male patient presented for evaluation of headaches and transient paresthesia on the right side. Diagnostic imaging with computed tomography revealed a lesion suggestive of a partially thrombosed aneurysm in the territory of the left middle cerebral artery (MCA). Diagnosis was further confirmed with cerebral angiography, which identified the presence of serpentine opacification in the frontal M2 segment, exhibiting slow flow and terminating in a distal branch of the parent artery (figure 1).

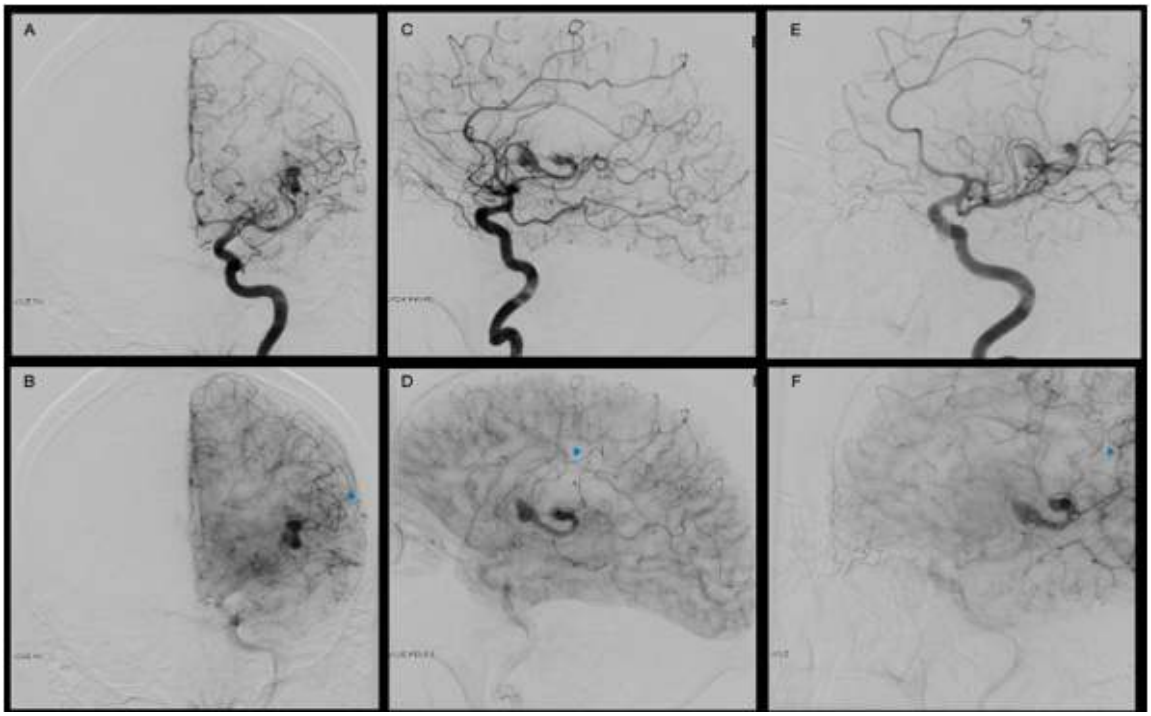

Figure 1. Intracranial digital subtraction angiography images in anteroposterior view (A and B), lateral view (C and D), and left oblique view (E and F), demonstrating, in the early arterial phase of the left internal carotid artery (ICA) (A, C, and E), the serpentine opacification in the frontal M2 segment of the left middle cerebral artery (MCA), with slow flow. In the late arterial phase (B, D, and F), it is observed that the fusiform aneurysm with a sinusoidal appearance terminates in distal branches of the parent artery (arrowheads).

Consequently, an elective procedure was performed involving parent vessel occlusion testing and embolization of the serpentine aneurysm. Initially, selective microcatheterization of the parent branch of the aneurysm was conducted, followed by balloon occlusion testing (figures 2 and 3).

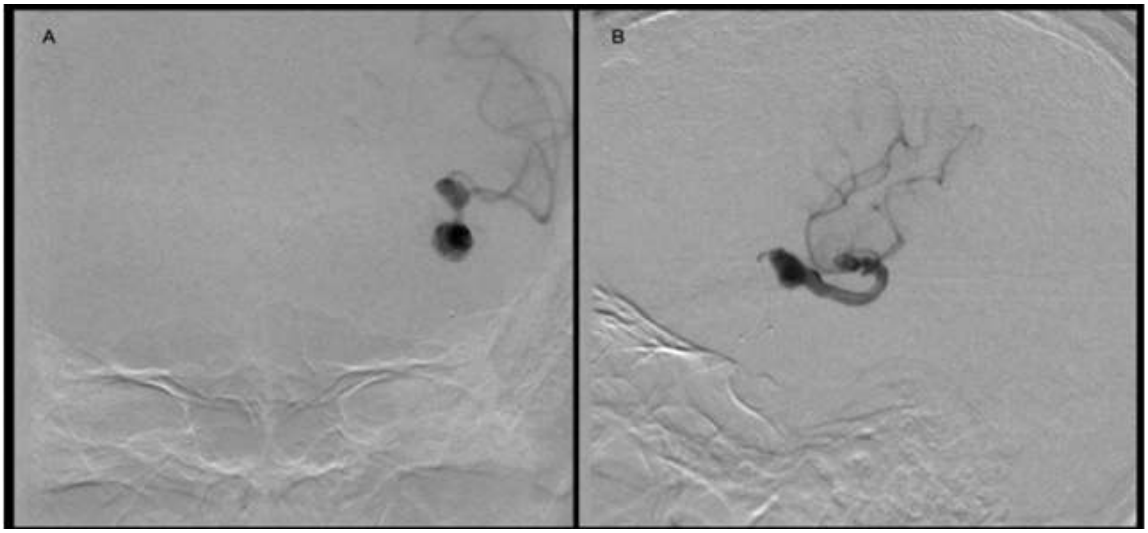

Figure 2. Intracranial digital subtraction angiography image in anteroposterior view (A) and lateral view (B), demonstrating the microcatheterization of the fusiform aneurysm, indicating that it terminates in distal branches of the parent artery.

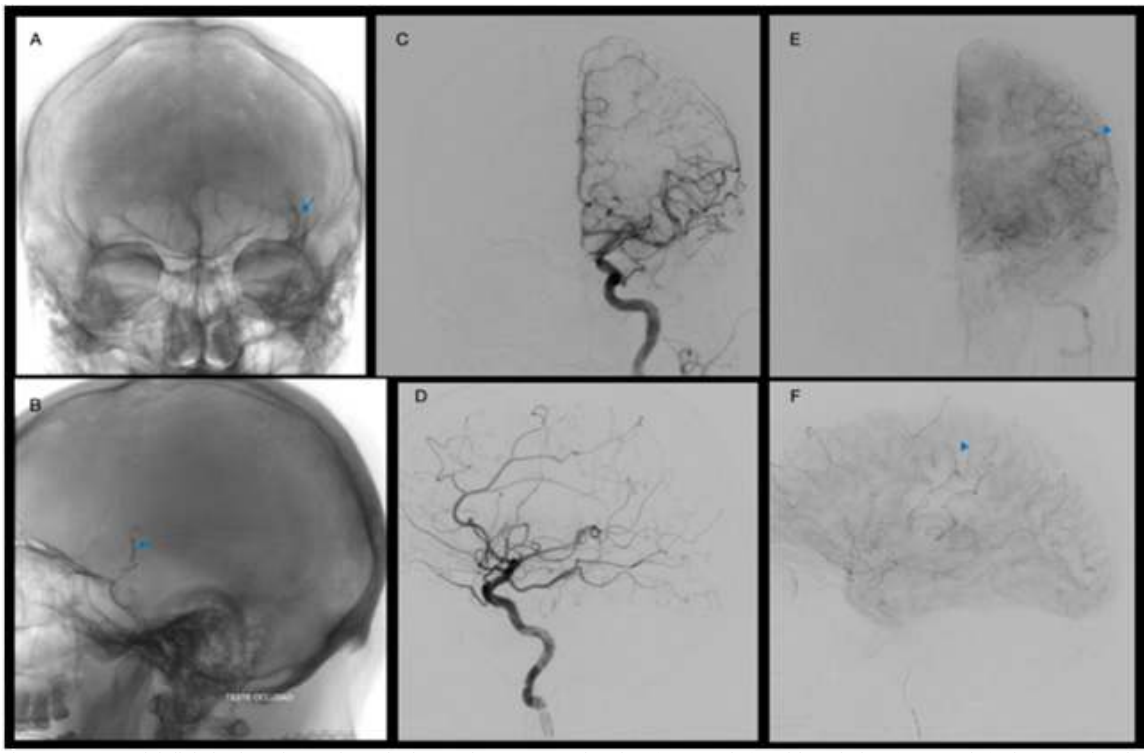

Figure 3. Intracranial digital subtraction angiography images in anteroposterior view (A, C, and E) and lateral view (B, D, and F), demonstrating the balloon occlusion test of the parent artery of the fusiform aneurysm. The balloon is positioned in the frontal M2 segment of the left middle cerebral artery (blue arrows). In the early arterial phase of the left internal carotid artery with the balloon inflated (C and D), there is no opacification of the serpentine aneurysm. In the late arterial phase (E and F), retrograde filling of cortical branches of the parent artery is observed under occlusion testing, originating from a leptomeningeal anastomosis (arrowheads).

Retrograde filling of the cortical branch of the parent artery during the occlusion test was observed, originating from a leptomeningeal anastomosis. The aneurysm was then embolized using a destructive technique with platinum coils for occlusion of both the aneurysm and parent vessel (figure 4). The patient made a good recovery without any motor deficit, and he was discharged two days after the procedure.

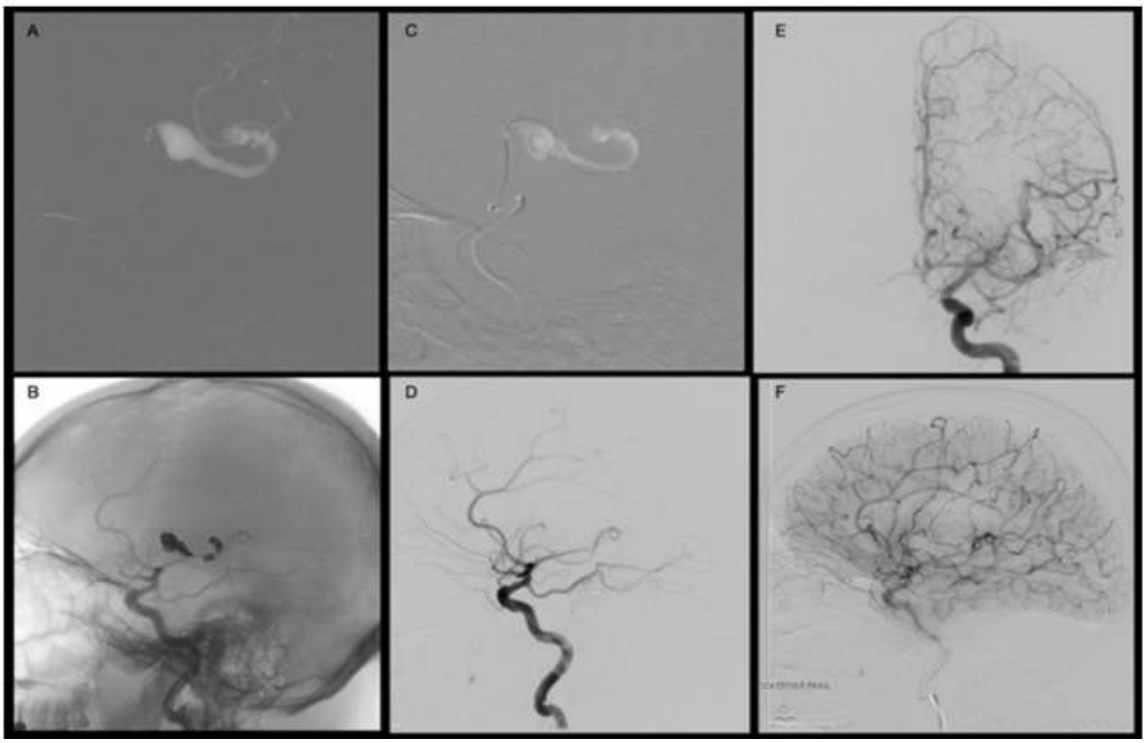

Figure 4. Intracranial digital subtraction angiography image in lateral view under magnification and roadmapping, demonstrating the working view with selective microcatheterization of the fusiform aneurysm and the initiation of platinum coil release for embolization using a destructive technique with vascular occlusion. Additionally, the image shows digital subtraction angiography in anteroposterior view (E) and lateral view (B, D, and F), illustrating the follow-up angiography after embolization of the serpentine fusiform aneurysm. In the late arterial phase (F), retrograde filling of cortical branches of the parent artery is observed.

Comments

The serpentine aneurysm was first described by Segal and McLaurin (4), presenting a series of cases with specific angiographic characteristics. These aneurysms exhibit serpiginous opacification with slow flow and terminate in a distal branch of the parent artery. Approximately 50% of these aneurysms are in the territory of the middle cerebral artery (MCA). The intra-aneurysmal vascular channel follows a sinusoidal, undulating course—hence the term "serpentiform". This formation results from the Coanda effect, a hemodynamic principle that describes how blood flow forces direct and reinforce the flow toward the aneurysm wall rather than allowing it to continue through the central portion of the aneurysm. This phenomenon occurs due to various entry and exit points at the lesion (1,3,4).

These aneurysms have a natural history associated with a high morbidity and mortality rate. Traditionally, they were treated with microsurgery, which was linked to high rates of morbidity and mortality (approximately 30-35%) (5). In recent years, studies have shown improved outcomes with the development of reconstructive techniques, such as bypass surgery, and endovascular techniques (1). Both reconstructive methods (such as the use of flow diverter stents) and destructive approaches (vascular occlusion) are performed with the aid of parent vessel occlusion testing (6–8).

Conclusion

The serpentine aneurysm is a rare entity, yet it possesses specific angiographic characteristics that are essential for appropriate management. Generally, these pathologies are technically challenging, and each case must be considered individually.

References

1. Atallah O, Hammoud Z, Aljeradat B, Almealawy YF, Badary A, Elqader JA, et al. A comprehensive analysis and systematic review of giant serpentine aneurysms. Annals of Medicine & Surgery 2025;87:1458–66. Doi:10.1097/MS9.0000000000003000.
2. Anson JA, Lawton MT, Spetzler RF. Characteristics and surgical treatment of dolichoectatic and fusiform aneurysms. J Neurosurg 1996;84:185–93. Doi:10.3171/jns.1996.84.2.0185.
3. Romano A, Moltoni G, Piazza A, Trasimeni G, Miscusi M, Palizzi S, et al. Giant serpentine aneurysm: Neuroradiological and neurosurgical management in a left-handed patient. Radiol Case Rep 2023;18:4384–8. Doi:10.1016/j.radcr.2023.09.014.
4. Segal HD, McLaurin RL. Giant serpentine aneurysm. J Neurosurg 1977;46:115–20. Doi:10.3171/jns.1977.46.1.0115.
5. Aletich VA, Debrun GM, Monsein LH, Nauta HJ, Spetzler RF. Giant serpentine aneurysms: a review and presentation of five cases. AJNR Am J Neuroradiol 1995;16:1061–72.
6. Kandemirli SG, Cekirge S, Oran I, Saatci I, Kizilkilic O, Cinar C, et al. Intracranial Serpentine Aneurysms: Spontaneous Changes of Angiographic Filling Pattern. American Journal of Neuroradiology 2018;39:1662–8. Doi:10.3174/ajnr.A5746.
7. van Rooij WJ, Sluzewski M, Beute GN. Endovascular Treatment of Giant Serpentine Aneurysms: Fig 1. American Journal of Neuroradiology 2008;29:1418–9. Doi:10.3174/ajnr.A1071.
8. Christiano LD, Gupta G, Prestigiacomo CJ, Gandhi CD. Giant serpentine aneurysms. Neurosurg Focus 2009;26:E5. Doi:10.3171/2009.2.FOCUS0918.

Lívio Pereira de Macêdo
https://orcid.org/0000-0002-5636-8256
Bruno Mota
https://orcid.org/0000-0001-5870-0673
Romero Marques
https://orcid.org/0000-0003-4016-4344
José Laercio Júnior-Silva
https://orcid.org/0009-0005-8044-6268
Carlos Gustavo Coutinho Abath
https://orcid.org/0000-0003-0059-8105

Author contributions: LPM, BM, RM: wrote the main manuscript text. All authors reviewed the manuscript.
Conflicts of interest: The authors report no conflict of interest.
Funding: This research received no specific grant from any funding agency in the public, commercial, or not-for-profit sectors.