Neurological Surgery and Anatomy 2025, 2(1): 38-47, e-ISSN: 2966-0696
DOI: 10.37085/nsa.2025.7

History of Medicine

The Fleece of Stilling: History of cerebellar white matter

Simone Olei[1,2,3], Giovanni Colacicco[4], Beatrice Astrid Lauber[4], Nupur Pruthi[5], Niklaus Krayenbühl[2,6], Marco Riva[3], Federico Pessina[3], Luca Regli[1,2], Carlo Serra[1,2]

[1]Department of Neurosurgery, University Hospital Zürich, Zürich, Switzerland
[2]Clinical Neuroscience Center, Neuroscience Center, University of Zürich, Switzerland
[3]Department of Neurosurgery, IRCCS Humanitas Research Hospital, Milan, Italy
[4]University of Zurich, Institute of Anatomy, Zürich, Switzerland
[5]Department of Neurosurgery, National Institute of Mental Health and Neurosciences, Bangalore, Karnataka, India
[6]Department of Neurosurgery, University Children's Hospital Zürich and University of Zürich, Zürich, Switzerland

Introduction
The cerebellum harbours different functions, ranging from motor to cognitive and linguistic skills. This complex functional landscape is founded on a specific architecture of intracerebellar white matter fibres surrounding the dentate nucleus, extremely difficult to visualize with modern imaging techniques. Though, surgeons may greatly benefit from detailed knowledge of this anatomy. Historical studies have proved how anatomical dissections allow an accurate study of intracerebellar white matter bundles, providing essential information about the relations between dentate nucleus, cerebellar cortex and cerebellar peduncles. Throughout the centuries, the concept of dentate capsule, the so-called *Fleece of Stilling*, has been demonstrated by multiple authors but has been neglected in recent times.

Materials and Methods
Extensive historical literature research was conducted through multiple digital libraries, searching for complete digitalized works of selected historical anatomists, with the specific goal of reconstructing the evolution of knowledge relative to intracerebellar white matter architecture from the end of the XVIIth century to recent years. Key authors have been selected, and their original works were studied and reviewed.

Results
Essays and atlases from Vieussens, Malacarne, Vicq d'Azyr, Reil, Meckel the Younger, Arnold, Stilling, Cajal, Dejerine and Jakob were collected. Their anatomical descriptions and illustrations were discussed and detailed, demonstrating their discoveries about intracerebellar white matter anatomy.

Conclusion
Information deriving from studies performed by the major anatomists of the past highlights pivotal anatomical data. Integration of this knowledge with information gained through modern imaging technologies may have an important impact on surgeries of the cerebellum and cerebellum associated structures.

Keywords: Cerebellum, Dentate nucleus, White matter, Dissection, Anatomy.

Edited by:
Marcelo Moraes Valença

Simone Olei
simone.olei14@gmail.com

Submitted: January 22, 2025
Accepted: March 24, 2025
Published online: April 30, 2025

© Copyright 2025

Introduction

Historically, the cerebellum has been regarded for a long time as an organ devolved to motor function only (1). This classical dogma has been significantly challenged during history and modern data suggest that the cerebellum has a complex and differentiated range of functions. The cerebellum has been proved to be involved in executive functioning, visuospatial processing and language modulation. It is considered to regulate thought and language as well as movement, acting to govern the speed, fluidity, accuracy and appropriateness of cognitive and emotional processes. Loss of cerebellar tissue may have clinical consequences that go far beyond motor function (1–3). To partially clarify such a complex functional landscape, modern imaging techniques have been applied for the study of cerebellar connections. DTI tractography has been widely used to study the connections of the cerebellum with the brainstem, spinal cord and brain cortex. However, due to the small volume of the cerebellar hemisphere and the intrinsic limitations of the technique, the visualization of the fine intracerebellar connections is extremely difficult (4). Moreover, tractographic and functional imaging entail a partial sacrifice of anatomical resolution and loss of spatial detail (5).

White matter fiber dissection may partially overcome these limitations. This technique has historically represented an invaluable instrument to enhance the understanding of white matter anatomy of the brain and cerebellum and has been applied to the study of cerebellar connections, thanks mainly to the pioneering studies of important anatomists, surgeons and physicians. Using anatomical dissections and histological sections, these authors have progressively underlined a specific organization of the intracerebellar white matter fibres passing around the dentate nucleus (6–12). During the last century, most of the anatomical knowledge coming from these studies has been neglected, in favour of an increasing interest towards general cerebellar connectivity (3).

In this paper, we describe how anatomical studies have shaped knowledge on intracerebellar anatomy throughout the centuries. The work of historical anatomists, performed through white matter dissection and histological sections, can thus be integrated with data coming from modern imaging studies and become a valuable asset in surgical practice. Moreover, we provide a comprehensive description and historical foundation of what has been called, in recent literature, the *Fleece of Stilling*: the capsule of the dentate nucleus, establishing a direct white matter connection between the dentate nucleus and the cerebellar hemisphere (13).

Materials and methods

Extensive historical literature research was conducted with the use of multiple sources. We decided not to attempt a systematic review process for different reasons: the historical nature of the study; the necessity of tracing historical books and papers, many of which are not included in common research databases; the necessity of including many works in languages other than English; the highly specific goal of the study, focusing specifically on intracerebellar white matter anatomy.

Our research started consulting the digital collection of the Careum Medical Library of the University of Zürich. The goal was to obtain the full digital versions, whenever available, of the original anatomical studies treating the anatomy and structure of the cerebellum, based on both anatomical dissection and histological sections. The time window of our research spanned the period between the end of the XVIIth century, when a major impetus for neuroanatomical research began, and the first half of the XXth century, when classical anatomical studies became increasingly sporadic before the diffusion of Klinger's technique (14). Our first research parameter was the name of the authors, and the second one was the use of the keywords "cerebel", "dentate nucleus", "white matter", "anatomy", "dissection", "anatomic tables" and "nervous system". These terms were translated to German, French and Latin to include authors writing in different languages.

After an initial collection of manuscripts spanning two centuries, we expanded our search to the digital libraries of the Münchener Digitalisierungs - Zentrum, Gallica (Bibliothèque National de France), the BIU Santé Médecine - Université Paris Cité and the University of Marburg. On all research engines, the same research criteria were maintained.

Finally, anatomical essays and atlases from Raymond de Vieussens (1641-1716), Vincenzo Malacarne (1744-1816), Félix Vicq d'Azyr (1748-1794), Johann Christian Reil (1759-1813), Johann Friedrich Meckel the Younger (1781-1833), Friedrich Arnold (1803-1890), Benedict Stilling (1810-1879), Santiago Ramón y Cajal (1852-1934), Joseph Jules Dejerine (1849-1917) and Alfons Jakob (1884-1931) were collected.

We purposefully selected these authors and their studies to reconstruct the evolution of anatomical knowledge on the anatomy of white matter bundles intrinsic to the cerebellar hemisphere and the deep cerebellar nuclei. A particular focus was placed on the representation of the white matter surrounding the dentate nucleus and its organization.

Results

In history, Raymond de Vieussens provided the first mention and characterization of the dentate nucleus, that he called *corpus rhomboideum*. He also described the superior medullary velum, which still carries his name as the *valve of Vieussens*. His description of cerebellar anatomy is found in his *Neurographia Universalis* (1685). Though his work focused on the systematic dissection of the whole brain and brainstem and not on the cerebellum specifically, he must be credited with a widespread influence on the anatomical terminology of the following centuries concerning the cerebellum, and must be first cited in our historical progression (15).

The first complete systematic description of the anatomy of the human cerebellum is attributed to Vincenzo Malacarne. In 1776 he published *Nuova esposizione del cervelletto umano*, where

he described the anatomy of the cerebellar hemispheres and particularly the conformation and distribution of the folia. With his dissection studies, he also theorized a correlation between the degree of human intelligence and the number of cerebellar folia, particularly focusing on patients affected by cretinism. His studies are regarded as pivotal for the following anatomists and introduced for the first time terms such as tonsil, pyramid, uvula and the adjective "lingual" as referred to the portion of vermis leaning on the *valve of Vieussens*. The attempt to localize intellect and cognitive dysfunction in the cerebellum represents a peculiar aspect of Malacarne's work, innovative for his time. However, his main interest in his late years focused on the correlation between cerebellar anatomy and "madness", while laying the foundation for electrophysiological studies in the brain (16).

Ten years later, in 1786, Félix Vicq D'Azyr published Traité d'anatomie et de physiologie

He provided a most interesting representation of the ascending cerebellar connections, combined with a partial sectional study of the white matter of the cerebellar hemisphere. The author's interest was mainly focused on the description of the superficial anatomy of the cerebellum and the white matter ascending in the superior cerebellar peduncles. As shown in Figure 1B, the author doesn't recognize an organized pattern in the intracerebellar course of the white matter fibres of the middle cerebellar peduncle, which is, however, exposed by decortication in the picture. As shown in Figure 1C, the author represents the position and dimension of the dentate nucleus, describing it as submerged at the centre of the white matter bulk of the middle cerebellar peduncle (17).

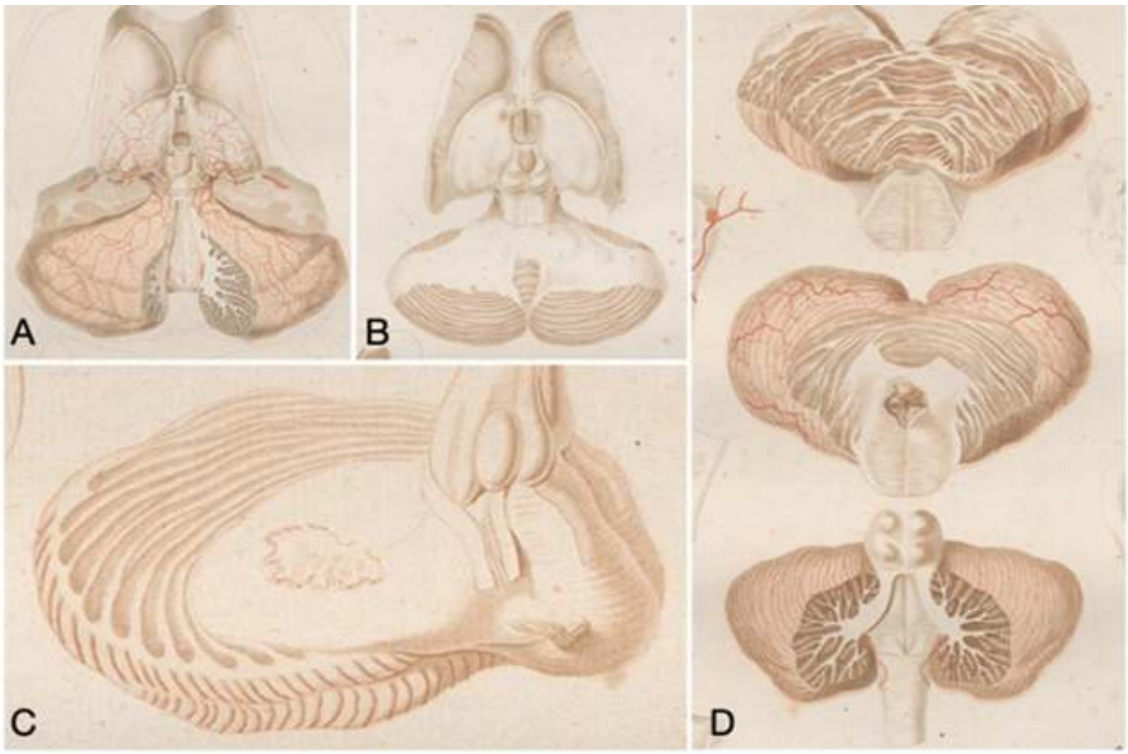

Figure 1. Vicq D' Azyr, 1786. Traité d'anatomie et de physiologie, avec des planches coloriees, représentant au natural les divers organes de l'homme et des animaux. A-D: Selected images showing axial, sagittal and coronal sections of the cerebellum and the ascending connections of the superior cerebellar peduncle. As represented in B and C, the Author doesn't recognize an architectural pattern in intracerebellar white matter. The dentate nucleus appears embodied in the deep fibers of the middle cerebellar peduncle.

A similar descriptive approach was adopted in the following years by other authors and can be traced in the works of Johann Christian Reil, who provided in 1809 an extensive description of the lobules and fissures of the cerebellar hemisphere. Reil noted how the cerebellar fissures, starting from every surface of the cerebellar hemisphere, penetrate the deep white matter pointing directly to the deep gray nuclei (18).

Between 1817 and 1826, Meckel the Younger published a four-volume essay titled *Tabulae anatomico-pathologicae*. In this work, he provided an accurate description of the embryological development of the cerebellum, followed by a description of normal cerebellar anatomy in the adult. It is evident from this work that Meckel, in line with the preceding trend, placed great emphasis on describing the superficial anatomy of the cerebellum, echoing the studies of Vicq d'Azyr and Reil, but showed less interest in the description of the anatomy of deep structures. Nonetheless, to the best of our knowledge, Meckel is the first author to explicitly mention a white matter capsule surrounding the contours of the dentate nucleus (which he called *corpus rhomboideum* after Vieussens and Vicq D'Azyr) and providing a most interesting description of it. According to Meckel, the dentate nucleus is located approximately "*in the centre of the cerebellar hemisphere*". On one hand, the white substance forming the hilum of the dentate nucleus is described by Meckel as "*continuous with that of the walls of the fourth ventricle*". On the other hand, the configuration of the white matter surrounding the remaining surface is said to reproduce that of the sublobular white matter of the cerebellar hemisphere. "*The rhomboid body of the cerebellum is not only surrounded by a thin, smooth layer of white substance* […] *but this layer acquires greater thickness, and not only forms many successive ramifications, but is also covered a second time with grey substance*". Meckel thus describes how the white matter fibres that branch from the capsule of the dentate nucleus are in continuity with the grey matter of the cerebellar hemisphere. Unfortunately, no corresponding anatomical illustrations are reported in the respective books (19).

Anatomical information around the dentate nucleus and the cerebellar peduncles was further developed by the illustrations of Arnold, who published in 1838-1839 his *Tabulae Anatomicae*. His tables provided a higher level of anatomical detail, which is of great interest from an historical point of view, as reported in Figure 2. He represented how the middle cerebellar peduncle is made of multiple fibre layers concealing the corticospinal tract. He further characterized the mutual anatomical relationship between the cerebellar peduncles by sectional study. He also described the white matter fibres of the middle cerebellar peduncles inside the cerebellar hemispheres, providing a representation of their course and isolating the white matter "envelope" around the dentate nucleus (Figure 2C) (12,20).

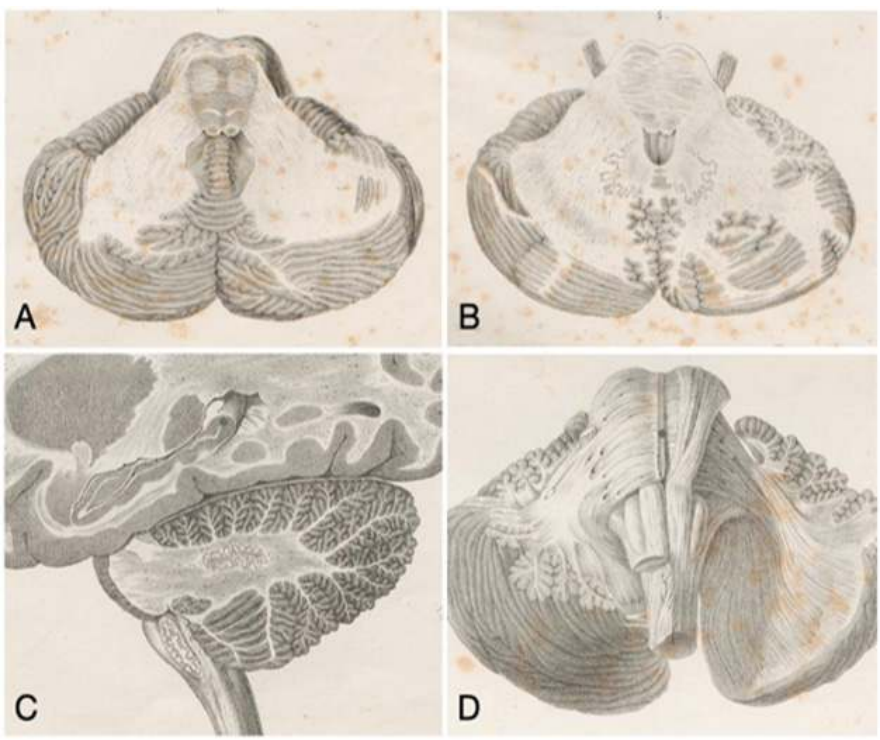

Figure 2. Arnold, 1839. Tabulae anatomicae: quas ad naturam accurate descriptas in lucem edidit (Fasciculus II). These anatomical tables represent with detail the architecture of the fibers of the middle cerebellar peduncle. In C, a thin white matter capsule is represented enveloping the dentate nucleus. In D, the corticospinal tract is visualized after partial dissection of the superficial pontine fibers.

However, it is only with the work of Benedict Stilling that the detailed anatomy of intracerebellar white matter was precisely described. In 1878, Stilling published the third part of a three-volume work titled *Untersuchungen über den Bau des kleinen Gehirns des Menschen* ("*Research on the structure of the human cerebellum*"), where he discussed the results of his dissections. He focused his work on the dentate nucleus, its connections with the cerebellar cortex and its relationship with the cerebellar peduncles. Stilling proposed a centripetal organizational pattern where the dentate nucleus, positioned at the centre of the cerebellar hemisphere, is circumferentially connected with the whole hemispheric cortex. He supposed that fibres coming from the cerebellar folia project to the dentate nucleus, creating a wide fan of white matter fibres that intersect the fibres of the afferent and efferent extracerebellar projections and ultimately collect around the dentate nucleus itself. Here, these fibres can be demonstrated with the white matter dissection technique as a tight, thin, whitish and brilliant light-refracting capsule, echoing Meckel's description. While appearing quite smooth to the eye, when observed at the microscope this capsule appears to be made up by a multitude of very thin and long fibres, converging from different directions, some running parallel to the nucleus, others penetrating and disappearing underneath. Stilling observed how this capsule enveloped the dentate nucleus "*similar to the three quarters of a circle, or the larger half of such a circle* […], *not protruding as far median towards the worm region as the lower and upper ends of the corpus dentatum*", so covering the posterior-lateral surface of the nucleus itself. Stilling called this white matter coat the *inner crossing zone*, then referred to it as a *Vlies*, a German term meaning *fleece* or *coat*, because of its tight relation with the underlying gray nucleus. Stilling stated that he couldn't establish, with the dissection technique, whether the fibres of this fleece projected also to the nuclei interpositus and tecti, but the distribution of the capsule made this hypothesis unlikely. Stilling documented his dissections through a photographic study. Selected images of his work are reported in Figure 3 and Figure 4 (6–9). It is curious to observe that, although Stilling is credited with the most extensive description of the dentate capsule, he did not provide good quality photographs illustrating it. However, Stilling made anatomical drawings of outstanding quality.

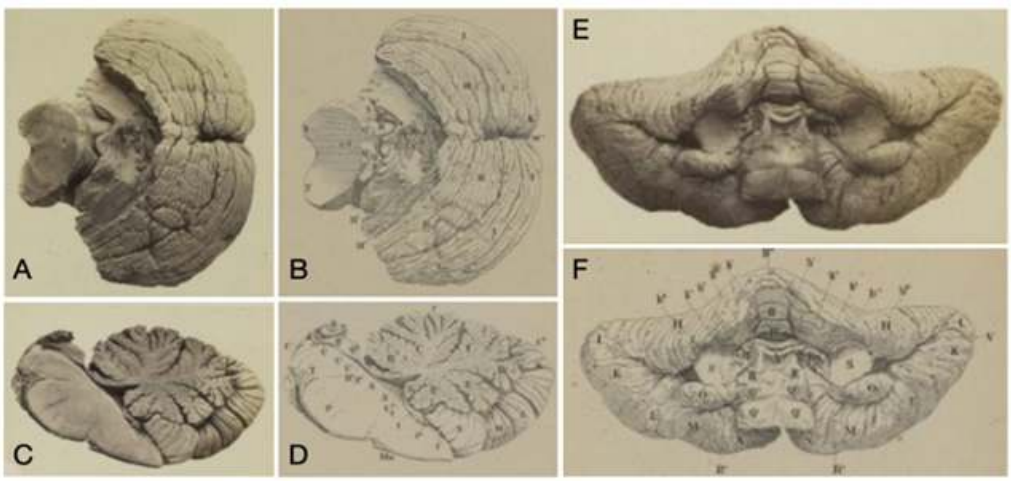

Figure 3. Stilling, 1864-1867. *Untersuchungen über den Bau des kleinen Gehirns des Menschen. Erstes/ Zweites Heft*. This image reports selected original photographs by Benedict Stilling, representing axial, sagittal and coronal sections of the cerebellum, paralleled with original drawings detailing different anatomical structures.

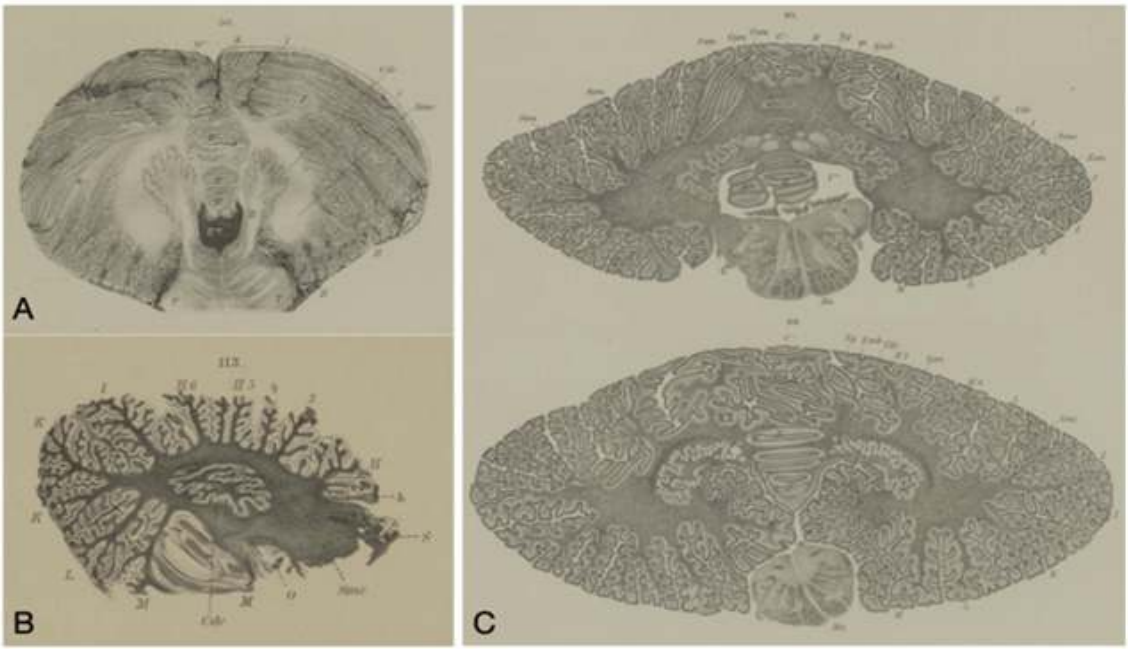

Figure 4. Stilling, 1878. *Neue Untersuchungen über den Bau des kleinen Gehirns des Menschen. Erste / Zweite Hälfte*. Original drawings by Benedict Stilling, representing in the axial and sagittal planes the white capsule of the dentate nucleus (*Cdc*: *Corpus dentatum - capsula*). In A, the capsule is represented along with the efferent projections ascending from the dentate nucleus to the superior cerebellar peduncle. In B, a sagittal section is reported, showing the capsule running all around the dentate nucleus. In C, two selected axial cuts are reported: Stilling represents the dentate capsule along with the fascicles composing the external semicircular fibers (*Scm*, *Smc*) and the cerebellar commissures (*Com*).

Stilling's observations would be further developed in the following years by using the microscope for cerebellar dissection. At the end of the XIXth century, Santiago Ramon y Cajal, studying the microscopic anatomy of the cerebellar cortex, reported a similar observation on the white matter surrounding the dentate nucleus. Moreover, based on microscopic observations of samples from patients with degenerative conditions affecting Purkinje's cells in the cerebellar cortex, in which the loss of these cells caused a rarefaction of the white matter immediately adjacent to the dentate nucleus, Cajal assumed that the axons of Purkinje's cells could represent the fibres of the *fleece* described by Stilling. Cajal noted how a minor part of these axons originated also from the vermis (21).

In 1901, Joseph Jules Dejerine published his *Anatomie des Centres Nerveux*, in which he discussed his observations on white matter dissection of cerebellar specimens. He studied the connections of the cerebellar hemispheres and the dentate nuclei and demonstrated the consistent observation of a white matter capsule tightly enveloping the dentate nucleus. He called this capsule *feutrage extraciliaire* (*extra-ciliary felt pad* or *external fleece*). He identified this layer as the *dentate capsule* described by Stilling and assumed that it consisted of projections coming from the cerebellar folia to the dentate nucleus. He also distinguished a *feutrage intraciliaire* (*intra-ciliary felt pad* or *internal fleece*), which consists of a correspondent fleece coating the region of the hilum of the dentate nucleus on the medial side. He assumed that these fibres represented direct afferent projections from the vermis to the dentate, but also connections with the nuclei interpositus and tecti. Dejerine also identified a different white matter layer, which actually covers the fleece of Stilling but has a completely different role: the layer of the *external semicircular fibres*. At this stage, Dejerine identified these fibres as afferent projections entering the cerebellum through the inferior cerebellar peduncle, covering the external fleece of the dentate nucleus and immediately covered in turn by the bulk of the afferent fibres traveling through the middle cerebellar peduncle (10). A selection of Dejerine's drawings is reported in Figure 5.

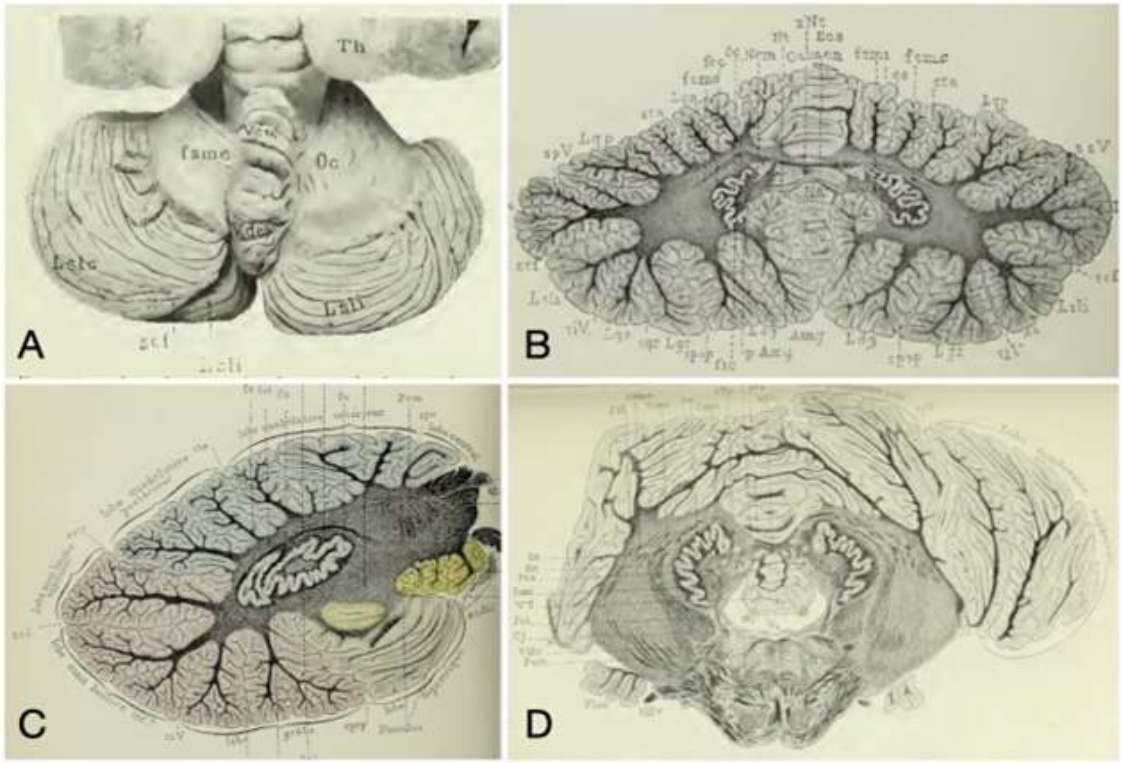

Figure 5. Dejerine, 1901. *Anatomie des Centres Nerveux*. With these refined and detailed anatomical drawings, Dejerine follows the steps of Stilling's studies. In A, the external semicircular fibers (*fsme*) are showed around the dentate nucleus (*Oc*: *Olive cerebelleuse*). In B, C and D, sections on the three anatomical planes detail the relation between the dentate capsule (*fec*: *feutrage extraciliaire*) and the external semicircular fibers.

In 1928, with his *Das Kleinhirn. Handbuch der Mikroskopischen Anatomie des Menschen*, Alfons Jakob resumed these previous anatomic works and discussed them in light of the embryologic development of the central nervous system. He proposed a morphologic description of the cerebellum based on phylogenesis and integrated his descriptions with a detailed microscopic sectional study of the cerebellum. Moreover, Jakob used previous microscopic observations of cerebellar tract degeneration in specific CNS lesions to postulate cerebellar connections. Thus, he identified the intracerebellar position of different cerebellar tracts. Selected images of his work are reported in Figure 6 (11).

Jakob's microscopic illustrations demonstrated that the dentate nucleus is surrounded by a capsule with two sides: the *inneres vlies*, corresponding to Dejerine's *feutrage intraciliaire* and covering the dorsolateral two thirds of the dentate nucleus, and the *äusseres vlies*, corresponding to the layer which Stilling called *inner crossing zone* and Dejerine called *feutrage extraciliaire*, situated at the ventromedial one third of the dentate nucleus. This capsule may be identified in humans since the embryonic stage. The first description of it is attributed by Jakob to Stilling, who named it differently across his publications (*inner crossing zone*, *äusseres vlies*, *plexus extraciliaris*, *amiculum*, *dentate capsule*). Intimately adherent to the external capsule of the dentate nucleus, Jakob confirmed the existence of a separated system of fibres, the *external semicircular fibres*. Based on observations on fiber degeneration after distant lesions, he managed to identify the fibre tracts composing it. From inside out, the systems encountered are the *dorsal spinocerebellar tract* (*Flechsig's tract*), entering through the inferior cerebellar peduncle and coursing immediately upon the capsule of the dentate nucleus, and the *olivocerebellar tract*, which is immediately adjacent to Flechsig's tract. On the inner side of the dentate, a specular system of fibres covers the internal fleece and converges from the hilum of the dentate to the superior cerebellar peduncle, being composed of the numerous axons exiting from the nucleus and directed to the brainstem. Jakob called this layer *internal semicircular fibers* (11). Figure 6B and Figure 6C show the histological rendering of the external fleece of the dentate nucleus.

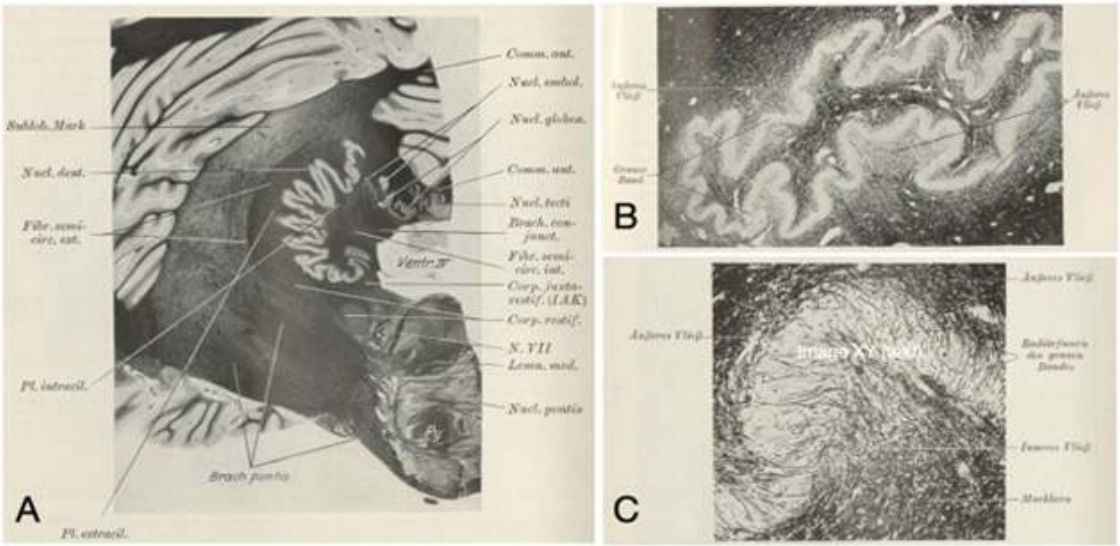

Figure 6: Jakob, 1928. *Das Kleinhirn. Handbuch der Mikroskopischen Anatomie des Menschen*. In A, a highly detailed drawing represents the *plexus intraciliaris* and *extraciliaris* surrounding the dentate nucleus from both sides. The anterior commissure is also represented. In B, a histologic section represents the transition from the dentate capsule (*Äusseres Vlies* or plexus extraciliaris) to the dentate nucleus. In C, a magnified version of the same image is reported.

Observed on axial sections, the semicircular systems of the two sides reach a close proximity along the midline and together form an arch around the inferior half of the roof of the IV ventricle. The external semicircular fibres are then completely covered by the fibers descending from the middle cerebellar peduncle, mainly composed by the afferent pontocerebellar connections directed to the cerebellar hemisphere. These fibres divide into the so called *sublobular peduncles* of the cerebellar lobules. Finally, through the study of sagittal sections, the existence of the above-mentioned commissures inside the cerebellum can be demonstrated. The *major cerebellar commissure* (*commissura cerebellaris anterior* or *large cerebellar anterior commissure*) is formed by the distal fibres of the inferior cerebellar peduncle, coursing perpendicular to the vermis and reaching to the contralateral side above the nodule, superiorly and anteriorly to the nucleus tecti. These fibres course at the height of the vertical branch of the arbor vitae and mainly involve the lingula, the culmen and the lobulus centralis of the vermis. The *minor cerebellar commissure* (*commissura cerebellaris posterior*) is formed by a smaller quantity of fibres mainly belonging to the middle cerebellar peduncle, with a triangular shape on sagittal sections, that cross to the contralateral side posteriorly to the nucleus tecti and involving the declive, the tuber and the folium. Jakob also describes an *interfastigial decussation*, connecting the nuclei tecti of the two sides and formed by fibres perpendicularly crossing the fibres of the superior cerebellar peduncle immediately behind the origin of the superior medullary velum (11). A similar description of the cerebellar commissures can also be found in the works of Stilling (7) and Dejerine (10). Illustrations of the cerebellar commissures provided by these authors can be seen in Figures 4 and 5.

Discussion

Over the centuries many anatomists, surgeons and physicians have focused their studies on the cerebellum, revealing its anatomical structure and a growing functional complexity. The above-mentioned anatomical studies have built, through centuries of meticulous research, a body of knowledge which deserves to be added as reference for surgical practice. However, during the second half of the XXth century, many anatomical concepts concerning intracerebellar white matter connectivity have been overlooked, in favour of a growing interest in the general connectomics of the cerebellum and its functions. Moreover, the study of normal microanatomy of cerebellar white matter has been progressively neglected in favour of a greater interest in modern imaging techniques, especially in pathological contexts. This may entail an excessive simplification of anatomic concepts concerning intracerebellar white matter, which could be conceived as lacking a specific organization.

For the surgeon, a clear knowledge of microanatomy plays an invaluable role in the operative setting. This applies particularly to the cerebellum, an organ with a wide spectrum of functions. Starting from the initial concept of an organ dedicated to the regulation of motor function alone, clinical and preclinical research has cast light on a spectrum of extremely different functions which differ significantly from one another. Today, the cerebellum is regarded as a fundamental regulator of voluntary movement and involuntary motion schemes, reflexes, and posture; it is thought to participate in regulation of visuospatial processing, cognitive task execution and superior functions; it is also thought to display

a peculiar regulatory modulation on language and emotional processes. Dysfunction of one or more of these systems may lead to a huge burden of clinical disturbances (22–25).

The dentate nucleus, the largest and phylogenetically the most recent of the cerebellar nuclei, is thought to play a pivotal role across many of these functions, beside playing a central part in motor control. Dysfunction of the dentate nucleus is recognized as etiological factor for severe clinical syndromes. Some authors even advocate functional specializations of different areas of the dentate nucleus based on connectivity studies (26). It is undeniable that the functional complexity of the cerebellar nuclei has an anatomical foundation: through the cerebellar peduncles, afferent and efferent projections connect the cerebellar nuclei with the entire neuraxis. Anatomical studies have proved that the dentate nucleus and the associated smaller gray nuclei of the cerebellum are also intimately connected to the ipsilateral and contralateral cerebellar cortex through a capillary system of centripetal fibre tracts and commissures that intersect with the extracerebellar pathways in a complex fashion. In this context, surgical damage to the intracerebellar network may cause severe functional impairment. Preservation of the dentate nucleus and a conservative management of the hemispheric fibers connected with it must be taken into consideration by the surgeon, whenever possible.

In current neurosurgical practice, the sacrifice of huge portions of the cerebellar hemispheres is frequently considered feasible, even necessary. While in other regions, specifically associated with noble functions (e.g. the insula and the rolandic region), brain tissue preservation is considered mandatory, the cerebellar lobules are often not given the same attention. Understanding the anatomy and connections of the dentate nucleus is highly relevant for neurosurgical practice, and precious information can be acquired through the review of historical anatomical works. It is crucial to understand the intricate connections of the dentate nucleus with the whole cerebellar hemisphere. Thus, sparing the dentate nucleus alone may not be sufficient to avoid clinical impairments. Without the greatest possible caution being applied to the surrounding cerebellar parenchyma, the resection of wide portions of cerebellar tissue may induce disconnection of the dentate nucleus from its cortical afferent projections. Detailed anatomical information can be translated into surgical guidance through integration with modern imaging techniques, including both high resolution preoperative imaging and intraoperative sonography, with the goal of optimizing clinical postoperative outcomes.

Conclusion

In this paper, an extensive review of historical studies concerning the anatomy of intracerebellar white matter connections has been performed. The resulting information, besides revisiting neglected anatomical concepts and sustaining an architectural organization of a crucial functional region, may prove useful in the surgical setting when integrated with pre- and intraoperative imaging techniques.

References

1. Sankey EW, Srinivasan ES, Mehta VA, Bergin SM, Wang TY, Thompson EM, et al. Perioperative Assessment of Cerebellar Masses and the Potential for Cerebellar Cognitive Affective Syndrome. World Neurosurg 2020;144:222–30. Doi:10.1016/j.wneu.2020.09.048.
2. Rios-Zermeno J, Ballesteros-Herrera D, Dominguez-Vizcayno P, Carrillo-Ruiz JD, Moreno-Jimenez S. Dentate nucleus: a review and implications for dentatotomy. Acta Neurochir (Wien) 2024;166:219. Doi:10.1007/s00701-024-06104-z.
3. Ramos A, Chaddad-Neto F, Dória-Netto HL, Campos-Filho JM de, Oliveira E. Cerebellar anatomy as applied to cerebellar microsurgical resections. Arq Neuropsiquiatr 2012;70:441–6. Doi:10.1590/S0004-282X2012000600011.
4. Habas C, Manto M. Probing the neuroanatomy of the cerebellum using tractography, 2018, p. 235–49. Doi:10.1016/B978-0-444-63956-1.00014-X.
5. Buckner RL. The Cerebellum and Cognitive Function: 25 Years of Insight from Anatomy and Neuroimaging. Neuron 2013;80:807–15. Doi:10.1016/j.neuron.2013.10.044.
6. Stilling B. Untersuchungen über den Bau des kleinen Gehirns des Menschen. vol. 1. Cassel: Verlag von Theodor Kay; 1864.
7. Stilling B. Untersuchungen über den Bau des kleinen Gehirns des Menschen. vol. 2. Cassel: Verlag von Theodor Kay; 1867.
8. Stilling B. Neue Untersuchungen über den Bau des kleinen Gehirns des Menschen. vol. 1. Cassel: Verlag von Theodor Fischer; 1878.
9. Stilling B. Neue Untersuchungen über den Bau des kleinen Gehirns des Menschen. vol. 2. Cassel: Verlag von Theodor Fischer; 1878.
10. Déjerine JJ. Anatomie des Centres Nerveux. Paris: J Rueff Éditeur; 1901.
11. Jakob A. Das Kleinhirn. Handbuch der Mikroskopischen Anatomie des Menschen, vol. 4, Berlim: Verlag von Julius Springer; 1928.
12. Arnold F. Tabulae Anatomicae, quas ad naturam accurate descriptas. vol. 1. Turici: Impensis Orellii, Fuesslini et sociorum; 1838.
13. Pruthi N, Kadri PAS, Türe U. Fiber Microdissection Technique for Demonstrating the Deep Cerebellar Nuclei and Cerebellar Peduncles. Operative Neurosurgery 2021;20:E118–25. Doi:10.1093/ons/opaa318.
14. Klinger J. Erleichterung der makroskopischen Preparation des Gehirns durch den Gefrierprozeß. Schweizer Archiv Für Neurologie Und Psychiatrie 1917;36.
15. Vieussens R. Neurographia Universalis. Lyon: Certe; 1684.
16. Malacarne V. Nuova esposizione della vera struttura del cervelletto umano. Torino: G. Briolo; 1776.
17. Vicq D' Azyr F. Traité d'anatomie et de physiologie, avec des planches coloriees, représentant au natural les divers organes de l'homme et des animaux. Paris: De L'imprimerie de Franc. Amb Didot l'Ainé; 1786.
18. Reil J. . Die Sylvische Grube oder das gestreifte grobe Hirnganglium, dessen Kapsel und die Seitentheile des großen Gehirns. Archiv Für Die Physiologie 1809.
19. Meckel JF. Tabulae anatomico-pathologicae, modos omnes, quibus partium corporis humani omnium forma externa

atque interna a norma recedit exhibentes. vol. 1–4. Leipzig: Gleditsch; 1817.
20. Arnold F. Tabulae anatomicae: quas ad naturam accurate descriptas in lucem edidit. vol. 2. Turici: Impensis Orellii, Fuesslini et sociorum; 1839.
21. Cajal SR. The Croonian lecture. La fine structure des centres nerveux. Proceedings of the Royal Society of London 1894;55:444–68. Doi:10.1098/rspl.1894.0063.
22. Glickstein M, Strata P, Voogd J. Cerebellum: history. Neuroscience 2009;162:549–59. Doi:10.1016/j.neuroscience.2009.02.054. Schmahmann JD. The cerebellum and cognition. Neurosci Lett 2019;688:62–75. Doi:10.1016/j.neulet.2018.07.005.
23. Stoodley CJ, MacMore JP, Makris N, Sherman JC, Schmahmann JD. Location of lesion determines motor vs. cognitive consequences in patients with cerebellar stroke. Neuroimage Clin 2016;12:765–75. Doi:10.1016/j.nicl.2016.10.013.
24. Stoodley CJ, Schmahmann JD. Evidence for topographic organization in the cerebellum of motor control versus cognitive and affective processing. Cortex 2010;46:831–44. Doi:10.1016/j.cortex.2009.11.008.
25. Tacyildiz AE, Bilgin B, Gungor A, Ucer M, Karadag A, Tanriover N. Dentate Nucleus: Connectivity-Based Anatomic Parcellation Based on Superior Cerebellar Peduncle Projections. World Neurosurg 2021;152:e408–28. Doi:10.1016/j.wneu.2021.05.102.

Simone Olei
https://orcid.org/0000-0002-2558-3017
Beatrice Astrid Lauber
https://orcid.org/0000-0001-9675-1172
Nupur Pruthi
https://orcid.org/0000-0001-5681-7659
Niklaus Krayenbühl
https://orcid.org/0000-0003-1089-221X
Marco Riva
https://orcid.org/0000-0003-4643-6451
Luca Regli
https://orcid.org/0000-0003-4639-4474
Carlo Serra
https://orcid.org/0000-0002-7305-550X

Authors contribution: SO, CS: conception and design of the work; SO: acquisition, analysis and interpretation of data; SO, CS: drafting of the work; CG, LBA, PN, KN, RM, PF, RL, CS: critical review for intellectual content; All authors: Final approval of the version to be published.
Conflicts of interest: No conflicts of interest have to be disclosed by any of the authors.
Funding: This research received no specific grant from any funding agency in the public, commercial, or not-for-profit sectors.