Neurological Surgery and Anatomy 2025, 2(1): 13-16, e-ISSN: 2966-0696
DOI: 10.37085/nsa.2025.2

Short communication

The occipital bone in type B basilar invagination

José Jailson Costa do Nascimento[1], Leandro Moura Silva[1], Shannon de Oliveira Hunt[2], Rebeca Maurício Carneiro da Silva[3], Severino Aires de Araújo-Neto[4]

[1]Department of Anatomy, Federal University of Pernambuco, Recife, Pernambuco, Brazil
[2]Center for Medical Sciences, Federal University of Pernambuco, Recife, Pernambuco, Brazil
[3]Department of Medicine, University Center of João Pessoa, Joao Pessoa, Paraiba, Brazil
[4]Department of Internal Medicine, Diagnostic Imaging, Federal University of Paraiba, Joao Pessoa, Paraiba, Brazil

Introduction
Basilar invagination (BI) is a multifactorial abnormality of the craniovertebral junction. The embryological complexity of the occipital and cervical spine, combined with diverse etiological factors, indicates a great challenge to understand the various mechanisms involved in BI development.
Objective
To present the morphology of the occipital bone in a skull with BI type B.
Methods
This is a brief description of the anatomy of the occipital bone in the type B BI through macerated skulls. Two right hemicraniums (1 with BI and 1 control) of adults (age unknown) and a skull base of a fetus with 20 weeks were used. Parts of the occipital bone were marked to illustrate the more hypoplastic components in BI.
Results
The occipital bone shows four main bony components: basioccipital (lower clivus), right and left exoccipital (lateral and condylar parts), and the supraoccipital part of the occipital squama. The BI type B presented severe hypoplasia of the basioccipital and exoccipitals, which make the appearance of the foramen magnum more inclined. The petrous parts (petromastoid) of the temporal bone followed the process of occipital invagination.
Conclusion
The occipital bone showed a complex hypoplasia in the anterior and lateral region of the foramen magnum, with an evident tendency to clivus shortening and hypoplastic occipital condyle.

Keywords
Basilar invagination, Clivus, Basioccipital, Exoccipital, Supraoccipital, Foramen magnum.

Edited by:
Carolina Martins

José Jailson Costa do Nascimento
josejailson64@gmail.com

Submitted: January 4, 2025
Accepted: March 11, 2025
Published online: April 30, 2025

© Copyright 2025

Introduction

In the last 3 decades, radiological and neurosurgical literature have evolved strongly in the BI understanding (1,2). In several cases, the radiological morphological presentations of occipital dysplasia and cervical spine point to a vast diversity of anatomical alterations in this group of patients (1,2).

The BI is a complex craniovertebral junction abnormality that can compress the brainstem and spinal cord (1). The neurological manifestations are diverse, including headaches, motor and sensory disturbances, and autonomic dysfunctions (2). Syringomyelia may occur due to obstruction of cerebrospinal fluid circulation (2). Atlantoaxial instabilities represent type A BI, while abnormalities associated with cranial base dysplasia are classified as type B BI (3). A posterior cranial fossa volume reduction is frequently observed in type B BI due to hypoplasia of the clivus and areas adjacent to the foramen magnum (4).

The present paper aimed to present the morphology of the occipital bone in a skull with BI type B.

Methods

This paper describes the anatomical division of the occipital bone by presenting images of a fetal skull of 20 weeks (Figure 1) and two right hemicraniums (1 with BI and 1 control) of adults (age unknown) (Figure 2). Parts of the occipital bone were marked to illustrate the more hypoplastic components in BI. Thus, revisiting the classical anatomy of the occipital bone can provide a broader view of BI.

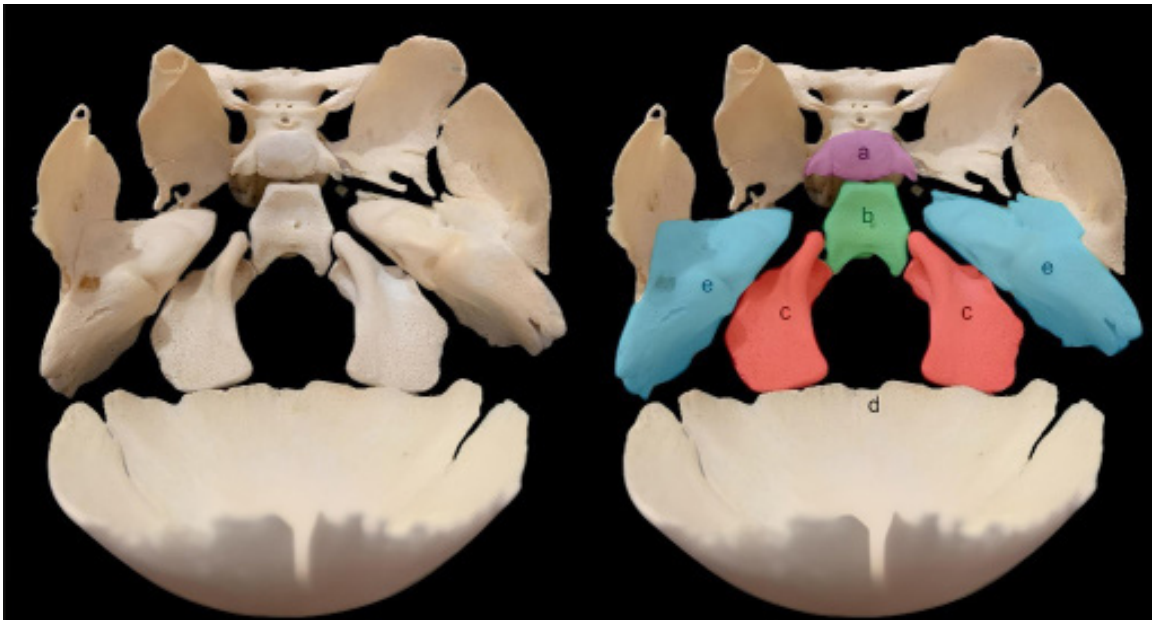

Figure. 1 Internal view of the cranial base of a 20-week-old fetus showing the complex bony framework. The gaps between the bones are filled with synchondroses, which are the predominant type of growth at the cranial base. a: basilar part of the sphenoid; b: basioccipital; c: exoccipital; d: supraoccipital, which contains a large area of the cerebellar fossae; e: petrous part of the temporal bone.

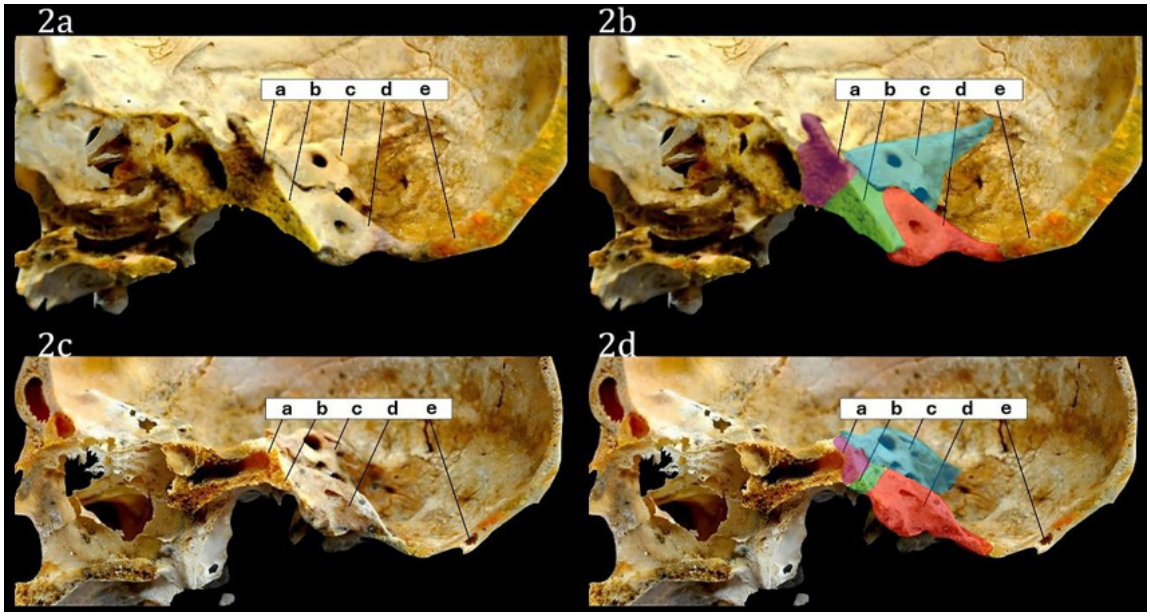

Figure 2. Sagittal view of the hemicrania of two adults, one with satisfactory growth of the cranial base (upper skull) and the other with type B basilar invagination (lower skull); A: basilar part of the sphenoid; B: basiocciptal; C: petrous part of the temporal bone; D: exoccipital; E: supraoccipital. Notably, observe the influence of basioccipital and exoccipital hypoplasia on the inclination of the foramen magnum. Additionally, the petrous part of the temporal bone appears to follow the invagination, and the sphenoidal sinus is flattened.

Results

A 20-week-old fetal skull base shows an occipital bone divided into 4 major components (Figure 1). In type B BI, the lower part of the clivus (basioccipital) and the lateral parts of the foramen magnum and the occipital condyles (exoccipitals) were the components affected by hypoplasia (Figure 2).

In this context, type B BI is an occipital abnormality with a complex morphological presentation. The subjective analysis of this BI indicated that the cranial base has associated alterations, with emphasis on the elevation of the petrous part of the temporal bone and a flattened posterior cranial fossa.

Discussion

This article presents the anatomy of type B BI in a right hemicranium compared to an occipital bone with preserved growth. To support the anatomical description of this comparison, a 20-week-old fetal skull was also used, showing the anatomical division of the occipital bone.

Around the seventh and eighth weeks of embryonic development, the primitive cartilaginous plates of the occipital bone emerge the basioccipital, exo-occipitals, and supraoccipital (5). In newborns, these parts remain articulated with each other, as well as with the temporal and sphenoid bones, through synchondroses (6). The fusion of these synchondroses represents a clinical enigma due to the temporal variability of their closure (6). The spheno-occipital, anterior intraoccipital, and posterior intraoccipital synchondroses completely close around the ages of 17, 10, and 4 years, respectively (6). The closure of the petro-occipital synchondrosis is not always completed by the age of 18 (6). This data illustrates a complex temporal dynamic of cranial base growth, which may also be influenced by the timing of the closure of the calvarial sutures, such as the coronal, sagittal, lambdoid, and squamous sutures.

Historically, there has been an association between type B BI and brachycephaly (7–9). This suggests a potential link between developmental disorders of the cranial base and conformational adaptations of the calvariae bones (10,11). The bone hypoplasia observed in type B BI suggests that this condition develops due to restricted growth of the cranial base. In "syndromic" genetic conditions - such as osteogenesis imperfecta and achondroplasia - this can be observed (12,13). Furthermore, craniosynostoses also indicate that the skull exhibits dynamic adaptive growth in response to vectorial growth restrictions (14).

Classical studies from the 18th and 19th centuries referred to basilar invagination as a depression of the cranial base caused by the weight of the head on the cervical spine (8–13). Considering that the occipital bone is a mosaic of bony plates joined by cartilages, Ackermann (8) observed in autopsies of children with rickets that the cranial base appeared to have "sunk" at the mobile cartilaginous points around the foramen magnum.

Finally, literature still does not present a consensus on the development of the anatomical phenomenon of type B BI. Most studies are retrospective and observational, which is a limiting factor for the formulation of accurate hypotheses. Although this disease has a diverse etiology (12–14), the bone growth disorders appear to be a common outcome, with varying degrees of occipital hypoplasia that also seem to influence the anatomy of the cranial base as a whole (15).

Conclusion

Type B BI is a complex abnormality that affects several regions of the occipital bone, especially the clivus and the lateral parts of the occipital bone. The three-dimensional complexity of this bone dysplasia seen in anatomical skulls may provide insights to understanding of occipital invagination by imaging exams.

References

1. Smoker WR. Craniovertebral junction: normal anatomy, craniometry, and congenital anomalies. RadioGraphics 1994;14:255–77. Doi:10.1148/radiographics.14.2.8190952.
2. Pinter NK, McVige J, Mechtler L. Basilar Invagination, Basilar Impression, and Platybasia: Clinical and Imaging Aspects. Curr Pain Headache Rep 2016;20:49. Doi:10.1007/s11916-016-0580-x.
3. Goel A. Treatment of basilar invagination by atlantoaxial joint distraction and direct lateral mass fixation. J Neurosurg Spine 2004;1:281–6. Doi:10.3171/spi.2004.1.3.0281.
4. Bianchi F, Benato A, Frassanito P, Tamburrini G, Massimi L. Functional and morphological changes in hypoplasic posterior fossa. Child's Nervous System 2021;37:3093–104. Doi:10.1007/s00381-021-05193-w.
5. Testut A. Anatomia Humana. Barcelona: Salvat; 1976.
6. Vu GH, Xu W, Go BC, Humphries LS, Kalmar CL, Taylor JA, et al. Physiologic Timeline of Cranial-Base Suture and Synchondrosis Closure. Plast Reconstr Surg 2021;148:973e–82e. Doi:10.1097/PRS.0000000000008570.
7. Caetano de Barros M, Farias W, Ataide L, Lins S. Basilar impression and Arnold-Chiari malformation. A study of 66 cases. J Neurol Neurosurg Psychiatry 1968;31:596–605. Doi:10.1136/jnnp.31.6.596.
8. Ackermann JF. Uber die cretinen eine besondere Menschenabart in den Alpen. Gotha : In der Ettingerschen Buchhandlung; 1970.
9. Nascimento JJC, Carreiro NMF, Oliveira GT, Ribeiro ECO, Holanda MMA, Neto EJS, et al. Relationship between basilar invagination and brachycephaly in Northeastern Brazil. Eur J Radiol 2018;104:58–63. Doi:10.1016/j.ejrad.2018.05.006.
10. Nascimento JJC, Silva LM, Ribeiro ECO, Neto EJS, Holanda MMA, Mello-Junior CF, et al. Investigating Type B Basilar Invagination Through Cephalic Indices. World Neurosurg 2022;164:e1262–8. Doi:10.1016/j.wneu.2022.06.007.
11. Botelho RV, Botelho PB, Hernandez B, Sales MB, Rotta JM. Association between Brachycephaly, Chiari Malformation, and Basilar Invagination. J Neurol Surg A Cent Eur Neurosurg 2023;84:329–33. Doi:10.1055/s-0041-1739503.
12. Sawin PD, Menezes AH. Basilar invagination in osteogenesis imperfecta and related osteochondrodysplasias: medical and surgical management. J Neurosurg 1997;86:950–60. Doi:10.3171/jns.1997.86.6.0950.
13. Ibrahim AG, Crockard HA. Basilar impression and osteogenesis imperfecta: a 21-year retrospective review of outcomes in 20 patients. J Neurosurg Spine 2007;7:594–600. Doi:10.3171/SPI-07/12/594.
14. Saemann A, Schmid S, Licci M, Zelechowski M, Faludi B, Cattin PC, et al. Enhancing educational experience through establishing a VR database in craniosynostosis: report from a single institute and systematic literature review. Front Surg 2024;11. Doi:10.3389/fsurg.2024.1440042.
15. Nascimento JJC, Ribeiro ECO, Silva-Neto EJ, Araújo-Neto SA, Valença MM, Diniz PRB. Letter to the editor regarding "basilar invagination": It is not a single disease. Eur J Radiol 2020;132:109280. Doi:10.1016/j.ejrad.2020.109280.

José Jailson Costa do Nascimento
https://orcid.org/0000-0002-0365-665X
Leandro Moura Silva
Shannon de Oliveira Hunt
https://orcid.org/0000-0003-4211-595X
Rebeca Maurício Carneiro da Silva
Severino Aires de Araújo-Neto
https://orcid.org/0000-0001-5141-2601

Author contributions

JJCN: performed writing and revision; LMS: edited the figures and article review; SOH: reviewed and edited the article; RMCS: reviewed and edited the article; SAAN reviewed and edited the article; All authors made the final approval of the manuscript.

Declaration of Competing Interest

The authors report no conflict of interest in this paper.

Funding Declaration

No funding was received for conducting this study.