Neurological Surgery and Anatomy 2025, 2(1): 22-28, e-ISSN: 2966-0696
DOI: 10.37085/nsa.2025.4

Case Report

Pretemp transcav kawase approach for trigeminal neuralgia

Tzu-Chiang Peng[1], Ping-Chuan Liu[1], Chun-Fu Lin[1], Sanford P C Hsu[1,2]

[1]Department of Neurosurgery, Neurological Institute, Taipei Veterans General Hospital, Taipei, Taiwan
[2]School of Medicine, National Yang Ming Chiao Tung University, Taipei, Taiwan

Background
Trigeminal neuralgia (TN) secondary to basilar artery (BA) compression is extremely rare. Macrovascular decompression is an option to address this condition. However, the unique anatomy surrounding the BA and trigeminal nerve poses significant surgical challenges. Various approaches and techniques have been discussed in the literature. We describe the pretemporal transcavernous Kawase approach, utilizing the transposition method with Teflon and an artificial dura sling, to achieve effective decompression.
Clinical presentation
We present a case of a 65-year-old male with left side medically-intractable TN secondary to dissecting BA aneurysm compression. Strategy with pretemporal transcavernous Kawase approach was conducted. The trigeminal nerve was found pushed superolaterally by ipsilateral deviation of BA. The BA was mobilized inferomedially with care to prevent perforating artery transection. A Teflon prosthesis and an artificial dura sling were interposed in neurovascular conflicting area. The patient experienced a transient period of dysphagia, necessitating nasogastric tube feeding during the postoperative course. The left-sided TN abated immediately after the intervention, and the patient was free from medication upon discharge.
Conclusion
This case was effectively managed utilizing the pretemporal transcavernous Kawase approach, coupled with a unique transposition technique employing Teflon and an artificial dura sling. This approach offered significant advantages, notably enhanced visualization of the trigeminal root entry zone (REZ) and improved maneuverability for repositioning the crooked BA inferomedially, away from the trigeminal nerve. The utilization of Teflon and an artificial dura sling as a transposition method ensured a safe distance between the BA and the trigeminal nerve. Consequently, an outstanding surgical outcome was achieved, characterized by complete resolution of TN resulting from dissecting BA aneurysm compression.

Keywords: Pretemporal transcavernous kawase approach, Macrovascular decompression, Dissecting basilar artery aneurysm, Trigeminal neuralgia.

Edited by:
Marcelo Moraes Valença

Sanford P C Hsu
doc3379b@gmail.com

Submitted: February 23, 2025
Accepted: April 28, 2025
Published online: April 30, 2025

© Copyright 2025

Introduction

Trigeminal neuralgia (TN), caused by demyelination of trigeminal sensory fibers, is a disabling illness. TN can be classified into three types: classic, secondary, and idiopathic (1). Classic TN is caused by neurovascular compression, while secondary TN is due to tumors, vascular malformations, or multiple sclerosis (2). Clinical observations and electrophysiological studies supported the concept that demyelination and ephaptic spread of excitation underlie most of these conditions (3). Decompression of the trigeminal nerve from an occupying blood vessel resulted in rapid remission of TN. Therefore, microvascular decompression (MVD) has important role in medically-refractory cases and is accompanied by good long-term outcomes (4,5). Classic TN is commonly caused by compression from the superior cerebellar artery (75-80%). Other less common etiologies include compression by the petrosal vein, anterior inferior cerebellar artery, or vertebral arteries (4,6). Classic TN secondary to indentation of crooked basilar artery (BA) was a special and rare entity among it. Because the neurovascular conflicting area was often be hindered by the petrous bone and the depth of the target anatomy limited the maneuverability, the management of BA remained problematic. In this article, we described technique of pretemporal transcavernous approach to deal with TN secondary to dissecting BA aneurysm compression.

Case Report

A 65-year-old male with hypertension presented with left side hemifacial pain for one year. The pain was described as intermittent, lancinating and restricted to CN V-2 and CN V-3 distribution. It was triggered by deglutition, yawning and chewing. These characters were typical of TN. Magnetic resonance imaging (MRI) of the brain unveiled that the tortuous BA deviated to the left side and indented the trigeminal root entry zone (REZ) (Figure. 1). A diagnosis of typical TN secondary to BA compression was made. Anti-epileptic drug with carbamazepine was effective initially but failed afterwards. Consideration was given to perform MVD via pretemporal transcavernous Kawase approach.

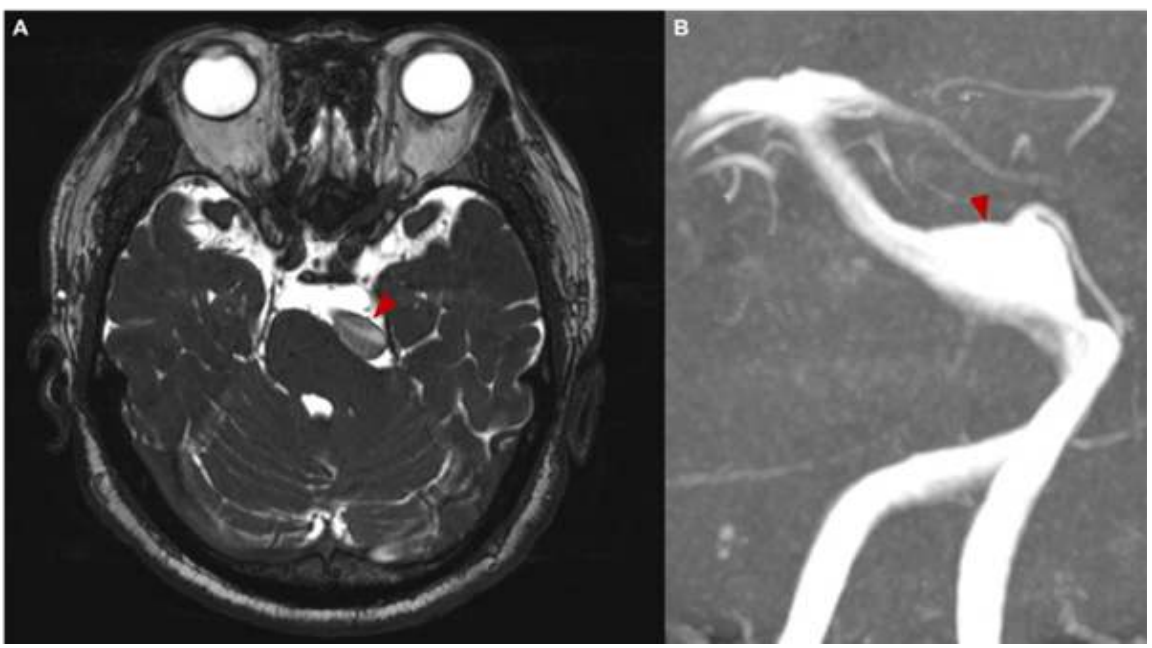

Figure 1. Brain MRI was performed before the operation. A) In the axial view of the CISS series, the dilated and tortuous BA was seen displacing the trigeminal root entry zone laterally. B) Three-dimensional magnetic resonance angiography of the BA in the coronal view revealed a left lateral deviation. (MRI = magnetic resonance imaging; CISS = constructive interference in steady state; BA = basilar artery).

The combination of pretemporal and transcavernous technique improved anatomic exposure and provided wider angle in the craniocaudal axis. The surgery included typical frontotemporal craniotomy in conjunction with zygomatic osteotomy. The patient was put in supine with a head turning angle of 45 degree to the opposite site. The malar eminence was placed at the highest point of the surgical field. The curvilinear skin incision started from 1 centimeter anterior to tragus to ipsilateral mid-pupillary line just posterior to hairline. Frontotemporal craniotomy was done in a standard fashion. Two burr holes were placed at parietal and temporal region below the superior temporal line. To avoid post-operative retro-orbital skin depression, the first burr hole was created posteriorly below superior temporal line and the second was made at the level of temporal squamous just above the posterior root of the zygoma. Zygomatic arch was vertically transected twice and mobilized downward together with temporalis muscle to offer adequate exposure to the floor of the middle fossa and lateral wall of the cavernous sinus.

The sphenoid ridge was grinded medially until reaching superior orbital fissure. At this point, a sharp incision of meningo-orbital band is often performed to allow separation of the temporal dura from periorbita. Blunt dissection was continued forward until reaching the lateral wall of the cavernous sinus. The lateral wall of cavernous sinus comprises an outer layer, namely dura propria, and an inner, membranous layer. Dura propria of the temporal lobe was bluntly dissected from the lateral wall of the cavernous sinus. After completing the work, the cranial nerves that traveled in the membranous layer of cavernous sinus were recognizable, composed of oculomotor nerve, trochlear nerve, trigeminal nerve. Other key structure such as foramen rotundum, ovale, spinosum and greater superficial petrosal nerve (GSPN) was also well appraised. Bleeding from the cavernous sinus could be controlled with careful packing or injection of fibrin glue to Mullan triangle boundary by CN V-1 and CN V-2. Transection of middle meningeal artery was always necessary to aid in exposing Kawase triangle, defined as area boundary by petrous ridge, mandibular branch of trigeminal nerve and GSPN. (Figure. 2A). Removing the bone in this triangle permitted the petroclival region to be exposed (Figure. 2B). As this section of petrous bone dose not contained neurovascular structure, it could be safely drilled. Caution was exercised that beyond the triangle, petrous part of carotid artery crossed its anterior margin and the otic capsule located posteriorly. After the opening of the petroclival dura, the BA was readily recognizable (Figure. 2C). Meckel cave was also open to access interpeduncular cistern. Indentation of trigeminal nerve and BA was well recognized.

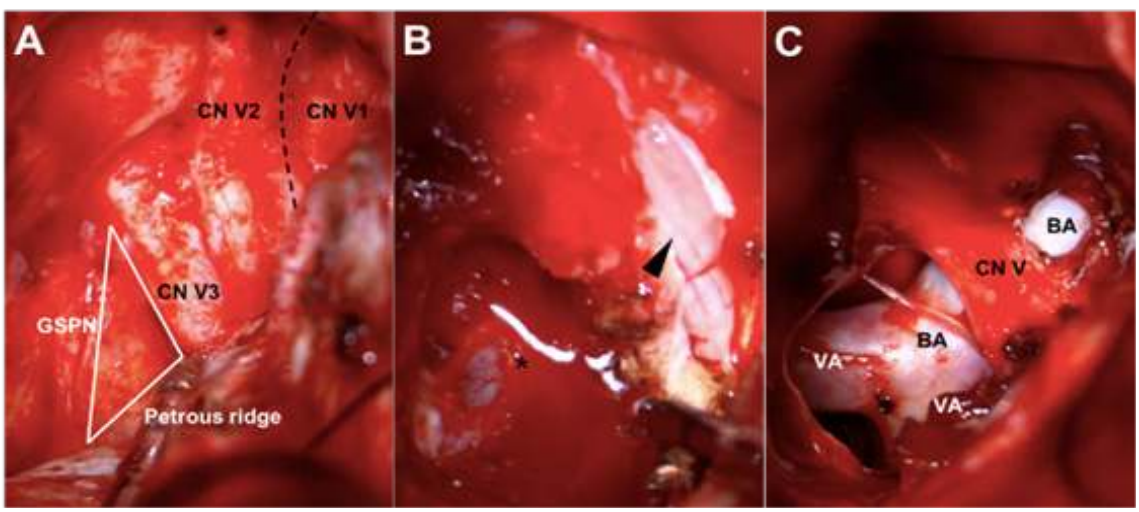

Figure 2. Photograph taken intraoperatively. (A) After untethering the middle cranial fossa structure, the temporal dura was peeled away from the lateral wall of the cavernous sinus, exposing the trigeminal division. The dotted line indicates the lower margin of the inferior cavernous sinus. Meckel's cave is located on the lateral aspect of the posterior cavernous sinus wall. The Kawase triangle, indicated by the continuous line, is also exposed. It is located between the GSPN, the petrous ridge, and the trigeminal nerve. (B) The Kawase triangle was milled, and the posterior fossa dura came into view (black star). Meckel's cave, situated at the posterior wall of the cavernous sinus, was incised in a linear fashion, exposing the posterior trigeminal root (black arrow), which appeared as multiple bundles of branches. (C) Both the posterior fossa dura and Meckel's cave were opened. In the image, the trigeminal root entry zone was seen to be compressed by the BA under direct visualization. (CN V = trigeminal nerve; GSPN = greater superficial petrosal nerve; BA = basilar artery; VA = vertebral artery).

In the present case, the BA was found crowding the ipsilateral trigeminal nerve in close proximity to its REZ and displaced it upward and laterally. The arachnoid band was dissected meticulously to aid in separating of trigeminal nerve and BA. On inspection, the neurovascular conflicting area was ensured release. Caution was exercised to spare the perforating branches of the BA. After adequate decompression, a Teflon prosthesis was interposed between the trigeminal nerve and BA. An aneurysmal clip was used to fix the prosthesis in situ and repositioned it away from trigeminal nerve. This procedure prevented the artery from repositioning and ensured a safe distance between the BA and the trigeminal nerve (Figure. 3).

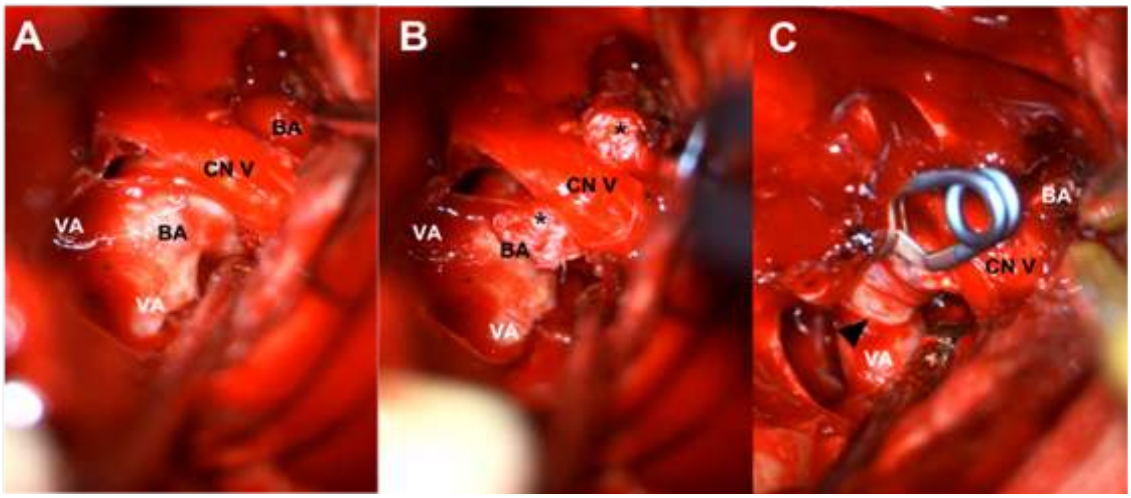

Figure 3. The intraoperative microscopic imaging illustrates the utilization of Teflon and an artificial dura sling as a transposition method to maintain a safe distance between the dissecting basilar aneurysm and the trigeminal nerve. (A) Relative anatomy of the trigeminal nerve, vertebral artery, and basilar artery. (B) The Teflon prosthesis (black star) was interposed between trigeminal nerve and BA. (C) The BAy wrapped with artificial dura, secured by an aneurysm clip. (CNV = trigeminal nerve; BA = basilar artery; VA = vertebral artery).

After the surgery, the patient had immediate improvement of TN with non-bothersome left hemifacial numbness. The anti-epileptic medication for TN was abated. A transient period of dysphasia, mandating nasogastric tube feeding was noted. Post-operative MRI demonstrated mild edema in left side hippocampus likely attributed to temporal lobe retraction during the surgery (Figure 4). The patient was discharged home with a smile from ear to ear. One year following the surgery, the patient identified mild hypoesthesia along the distribution of his left maxillary and mandibular branch of trigeminal nerve. It was hypothesized that the phenomenon probably due to chronic demyelination change of nerve owing to vessel compression because the diseased area was well compatible with the pre-existing TN region.

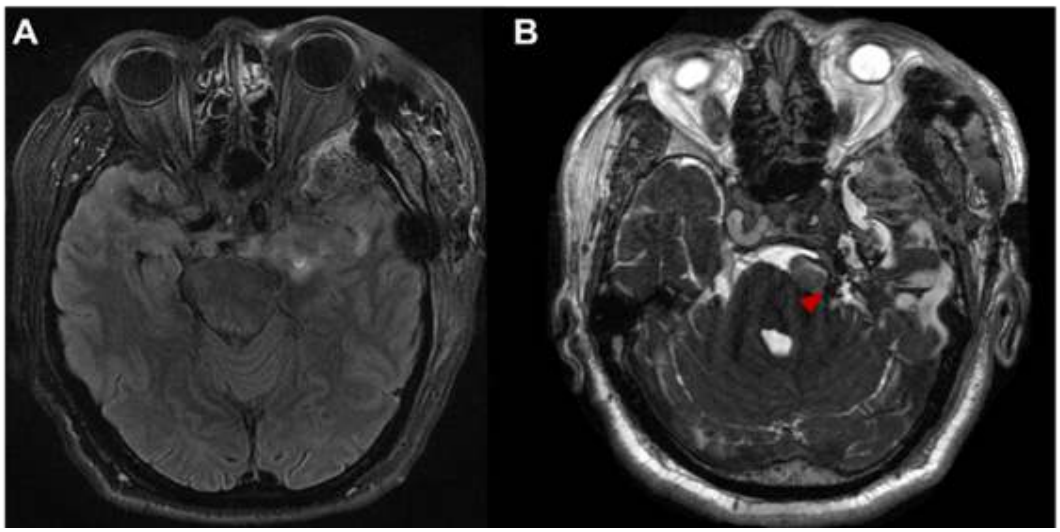

Figure 4. Brain MRI was obtained immediately after the surgery. A) In the axial view of T2-weighted imaging, the left side hippocampus had mild edema which was probably ascribed to temporal lobe retraction intraoperatively. B) In the series of CISS, It was noticed that low-signal Teflon prothesis wrapped around BA in the left cerebellopontine angle (arrowhead). (MRI = magnetic resonance imaging; CISS = constructive interference in steady state, BA = basilar artery).

Comments

The prevalence of TN is around 4-5 per 100,000. Most of the vascular based neuralgia is caused by the superior cerebellar artery (75%), the anterior inferior cerebellar artery (10%) or a vein (7%) (4,6). Dissecting a BA aneurysm is an uncommon cause and the rate of BA related TN varied from 0-7.7% in the literature (7–9). MVD was the choice of therapy for classic TN after failing of initial medical treatment. In the series of Barker et al (4), he reported more than 70% patients remained recurrence-free ten years after MVD, concluding MVD is a safe and effective treatment for TN with a high rate of long-term success.

However, in the entity of BA related classic TN, some series demonstrated poorer outcomes with the recurrence rate of 15-35% (4,10–12). The unsatisfactory outcome may be attributed to the depth of the target anatomy, compounded by the presence of critical neurovascular structures and the narrow surgical field, which together represent a significant challenge. In the past, these interpeduncular and prepontine lesions were described as "no man's land" due to the limited exposure caused by encroachment by the petrous part of temporal bone (13). Drake pioneered the development of skull base surgery and described a subtemporal route for the management of basilar apex aneurysm (14). In 1985, Kawase (13) introduced a novel surgical technique, subtemporal transpetrosal route, to approach BA aneurysm. Since then, several modifications have been developed, including the middle fossa transpetrosal-transtentorial approach, anterior transpetrosal approach, extradural temporopolar approach, modified Dolenc-Kawase approach, and temporopolar epidural transcavernous transpetrous approach. These techniques, along with their associated pitfalls, have gained widespread recognition (15–19). C.H. Liao and Sanford P.C. Hsu (20) have reported on level 4 cavernous sinus surgery, which involves opening the posterior wall of the cavernous sinus to access the posterior fossa. Therefore, we present a pretemporal transcavernous Kawase approach in this case to achieve MVD of the BA from the trigeminal nerve.

The Kawase approach is notably effective for TN resulting from BA compression. Yoon et al also described a case report that was managed successfully with pretemporal approach and the decompressive sling was also used to pull the BA away from the indented trigeminal nerve (21). This method provides broader exposure and a favorable sling trajectory. Similarly, Anton Früh et al. (22) demonstrated that the Kawase approach alone can achieve effective macrovascular decompression and adequate sling transposition. Compared to the pure Kawase approach, the pterional craniotomy and anterior petrosectomy offer an optimized decompressive effect by directing the sling inferomedially, thereby preventing further nerve compression (Table 1).

Table 1. Comparison of four approaches for classic trigeminal neuralgia related to dolichoectatic basilar artery

Author & Years	Approach	Overview	Neurovascular compression	Advantages	Pitfalls
	Traditional Suboccipital Retrosigmoid	Posterior fossa craniotomy, access to cerebellopontine angle	SCA, AICA, petrosal vein –>Telfon	Broad application, wide surgical field, less technically demanding	Higher risk of cerebellar retraction injury, less direct access to clival regions Difficult to deal with dolichoectatic basilar artery
Anton Früh, 2022	Pure Kawase Approach	Pretemporal transcavernous route, direct access to clival dura	Dolichoectatic BA –> Telfon + sling transposition	Direct access to neurovascular structures, minimizes brain tissue manipulation	Effective and experienced neurosurgeons, less direct access to bilateral VAs, potential injury to cranial nerves/vascular structures
Seungwon Yoon, 2019	Pterional Craniotomy and Anterior Petrosectomy Kawase Approach	Combines pterional craniotomy with anterior petrosectomy for wider exposure	Dolichoectatic BA –> Telfon + sling transposition	Provides wide exposure, avoids brain tissue manipulation	Effective and experienced neurosurgeons, potential for extended recovery time
Sanford, P.C, Hsu, 2024	Pretemporal Transcavernous Kawase Approach	Pretemporal approach through the cavernous sinus, access to the posterior fossa	Dolichoectatic BA –> Telfon + sling transposition	Provides wide exposure, avoids brain tissue manipulation, bilateral Vas visualization	Effective and experienced cavernous sinus surgery neurosurgeons, potential complications involving cranial nerves and vascular structures

SCA = Superior cerebellar artery, AICA = Anterior inferior cerebellar artery, VAs = Vertebral arteries, DBA = Dolichoectatic basilar artery, BA = Basilar artery.

A teflon prosthesis was interposed between the artery and the trigeminal root as we believe that the pulsatile compressiona have important role in the development of TN (8,23). Transposition involves repositioning the BA using various materials. These materials include Teflon pads, aneurysm clips, biomedical glues, sutures, vascular tapes, titanium plates, Teflon slings, and Gore-Tex slings (24,25).

In our patient, we gained access to Kawase triangle via pretemporal transcavernous route. Mobilization of internal carotid artery and opening the roof of cavernous sinus were advantageous to increase the area of exposure (26). In the pre-operative imaging study, as the BA pushed the trigeminal nerve superolaterally, it was felt that pretemporal corridor provided a direct visualization of the conflicting area and offered a better angle to reposition BA away from trigeminal REZ. The major benefits of extradural dissection are allowing more extensive degree of temporal lobe retraction and maximize the preservation of middle fossa venous outflow. Gabriel Zada et al. (17) reviewed 66 patients who underwent extradural dissection, reporting minimal temporal lobe complications. The extradural temporopolar approach offers low complication risks and is effective in providing wider exposure to the sphenocavernous and petroclival regions. Hence, the extradural temporopolar approach is not only suitable for large tumors in the sphenocavernous and petroclival regions and complex upper BA or superior cerebellar artery aneurysms, but also for dissecting a basilar compression of the trigeminal nerve. The interpeduncular cistern was access upon the Kawase triangle opening. The crooked BA and its bifurcation were found deviated and indenting the trigeminal nerve in a fashion consistent with the preop imaging study. The BA was retracted inferomedially away from trigeminal nerve at the end of surgery. The utilization of Teflon and an artificial dura sling as a transposition method ensured a safe distance between the BA and the trigeminal nerve. The arachnoid plan between the BA and the brainstem is a safe sign when performing dissection. Perforating branches from the BA should be preserved, as inadvertently lost of these branches could lead to brain stem infarction.

Other article had reported the complications of pretemporal transcavernous approach, such as facial palsy, hearing disturbance, ischemic stroke and temporal lobe injury (27–29). In one series involving 274 cases, the most frequent morbidity was CSF leak, accounting for 13.5% (16). Although some had questioned it usefulness, the combination of pretemporal approach and transcavernous technique optimized the exposure of interpeduncular and prepontine cisterns, which was not easy to be obtained via retrosigmoid approach. Anecdotal also suggested that this approach was advantageous for exploring petroclival meningioma, basilar apex aneurysm and clivus chordoma (15–17,30). The success of this technically-demanding approach depended on well-understanding of mutual relationships of skull base structure.

Summary

We reported a rare case of vascular based TN caused by dissecting BA aneurysm and managed successfully with pretemporal transcavernous Kawase approach. Satisfactory outcomes were appraised by the patient. We believed the pretemporal transcavernous Kawase approach is advantageous as it offered a wide visualization of upper clivus, and enhanced maneuverability in dealing with trigeminal REZ.

Acknowledgments

The study was also supported by Taipei Veterans General Hospital, Taipei, Taiwan.

References

1. Headache Classification Committee of the International Headache Society (IHS) The International Classification of Headache Disorders, 3rd edition. Cephalalgia 2018;38:1–211. Doi:10.1177/0333102417738202.
2. Gambeta E, Chichorro JG, Zamponi GW. Trigeminal neuralgia: An overview from pathophysiology to pharmacological treatments. Mol Pain 2020;16. Doi:10.1177/1744806920901890.
3. Love S, Coakham H. Trigeminal neuralgia: Pathology and pathogenesis. Brain 2001;124:2347–60. Doi:10.1093/brain/124.12.2347.
4. Barker FG, Jannetta PJ, Bissonette DJ, Larkins M V., Jho HD. The Long-Term Outcome of Microvascular Decompression for Trigeminal Neuralgia. New England Journal of Medicine 1996;334:1077–84. Doi:10.1056/NEJM199604253341701.
5. Sarsam Z, Garcia-Fiñana M, Nurmikko TJ, Varma TRK, Eldridge P. The long-term outcome of microvascular decompression for trigeminal neuralgia. Br J Neurosurg 2010;24:18–25. Doi:10.3109/02688690903370289.
6. Bašić Kes V, Matovina LZ. Accommodation to Diagnosis of Trigeminal Neuralgia. Acta Clin Croat 2017:157–61. Doi:10.20471/acc.2017.56.01.21.
7. Miyazaki S, Fukushima T, Tamagawa T, Morita A. Trigeminal Neuralgia due to Compression of the Trigeminal Root by a Basilar Artery Trunk. Neurol Med Chir (Tokyo) 1987;27:742–8. Doi:10.2176/nmc.27.742.
8. Linskey ME, Jho HD, Jannetta PJ. Microvascular decompression for trigeminal neuralgia caused by vertebrobasilar compression. J Neurosurg 1994;81:1–9. Doi:10.3171/jns.1994.81.1.0001.
9. Yang X-S, Li S-T, Zhong J, Zhu J, Du Q, Zhou Q-M, et al. Microvascular decompression on patients with trigeminal neuralgia caused by ectatic vertebrobasilar artery complex: technique notes. Acta Neurochir (Wien) 2012;154:793–7. Doi:10.1007/s00701-012-1320-6.
10. Sindou M, Leston J, Decullier E, Chapuis F. Microvascular decompression for primary trigeminal neuralgia: long-term effectiveness and prognostic factors in a series of 362 consecutive patients with clear-cut neurovascular conflicts who underwent pure decompression. J Neurosurg 2007;107:1144–53. Doi:10.3171/JNS-07/12/1144.
11. Bederson JB, Wilson CB. Evaluation of microvascular decompression and partial sensory rhizotomy in 252 cases of trigeminal neuralgia. J Neurosurg 1989;71:359–67. Doi:10.3171/jns.1989.71.3.0359.
12. Sindou M, Leston J, Howeidy T, Decullier E, Chapuis F. Micro-vascular decompression for primary Trigeminal Neuralgia

(typical or atypical). Long-term effectiveness on pain; prospective study with survival analysis in a consecutive series of 362 patients. Acta Neurochir (Wien) 2006;148:1235–45. Doi:10.1007/s00701-006-0809-2.
13. Kawase T, Toya S, Shiobara R, Mine T. Transpetrosal approach for aneurysms of the lower basilar artery. J Neurosurg 1985;63:857–61. Doi:10.3171/jns.1985.63.6.0857.
14. Drake CG. Bleeding aneurysms of the basilar artery. J Neurosurg 1961;18:230–8. Doi:10.3171/jns.1961.18.2.0230.
15. Kawase T, Shiobara R, Toya Sh. Middle fossa transpetrosal-transtentorial approaches for petroclival meningiomas selective pyramid resection and radicality. Acta Neurochir (Wien) 1994;129:113–20. Doi:10.1007/BF01406489.
16. Tomio R, Horiguchi T, Borghei-Razavi H, Tamura R, Yoshida K, Kawase T. Anterior transpetrosal approach: experiences in 274 cases over 33 years. Technical variations, operated patients, and approach-related complications. J Neurosurg 2022;136:413–21. Doi:10.3171/2020.12.JNS204010.
17. Zada G, Day JD, Giannotta SL. The extradural temporopolar approach: a review of indications and operative technique. Neurosurg Focus 2008;25:E3. Doi:10.3171/FOC.2008.25.12.E3.
18. Tripathi M, Deo RC, Suri A, Srivastav V, Baby B, Kumar S, et al. Quantitative analysis of the Kawase versus the modified Dolenc-Kawase approach for middle cranial fossa lesions with variable anteroposterior extension. J Neurosurg 2015;123:14–22. Doi:10.3171/2015.2.JNS132876.
19. Roche P-H, Mercier P, Fournier H-D. Approche épidurale temporopolaire transcaverneuse transpétreuse. Technique chirurgicale et indications. Neurochirurgie 2007;53:23–31. Doi:10.1016/j.neuchi.2006.10.002.
20. Liao C-H, Lin C-F, Wang J-T, Wang W-H, Chen S-C, Hsu SPC. The learning curve for cavernous sinus surgery illustrated by symptomatic intracavernous aneurysm clipping through a pretemporal transcavernous approach. J Neurosurg 2024;140:183–93. Doi:10.3171/2023.5.JNS2328.
21. Yoon S, Mascitelli JR, Mooney MA, Gandhi S, Chen T, Cole TS, et al. Kawase Approach for Dolichoectactic Basilar Artery Macrovascular Decompression in a Patient With Trigeminal Neuralgia: Case Report. Operative Neurosurgery 2019;16:E178–83. Doi:10.1093/ons/opy215.
22. Früh A, Vajkoczy P. Macrovascular decompression of a dolichoectatic vertebral artery via Kawase approach in a patient suffering from trigeminal neuralgia – A case report. Brain and Spine 2022;2:100848. Doi:10.1016/j.bas.2021.100848.
23. Piatt JH, Wilkins RH. Treatment of Tic Douloureux and Hemifacial Spasm by Posterior Fossa Exploration: Therapeutic Implications of Various Neurovascular Relationships. Neurosurgery 1984;14:462–71. Doi:10.1227/00006123-198404000-00012.
24. Amagasaki K, Takusagawa Y, Tatebayashi K, Nakaguchi H. Macrovascular Decompression with the Transposition Method Using Teflon Sling for Trigeminal Neuralgia Caused by the Vertebrobasilar Artery. World Neurosurg 2022;167:e1395–401. Doi:10.1016/j.wneu.2022.09.049.
25. Wu EM, Sun MZ, Khan NR, Morcos JJ. Kawase Approach for "Macrovascular" Decompression of Dolichoectatic Basilar Artery Causing Hemifacial Spasm Using Gore-tex Sling: 2-Dimensional Operative Video. Operative Neurosurgery 2023. Doi:10.1227/ons.0000000000000716.
26. Figueiredo EG, Tavares WM, Rhoton AL, de Oliveira E. Nuances and technique of the pretemporal transcavernous approach to treat low-lying basilar artery aneurysms. Neurosurg Rev 2010;33:129–35. Doi:10.1007/s10143-009-0231-3.
27. Chen S-C, Lin C-F, Liao C-H, Quilis-Quesada V, Wang J-T, Wang W-H, et al. The pretemporal trans-cavernous trans-Meckel's trans-tentorial trans-petrosal approach: a combo skill in treating skull base meningiomas. J Neurooncol 2020;146:407–16. Doi:10.1007/s11060-019-03354-1.
28. Krisht AF, Kadri PAS. Surgical Clipping of Complex Basilar Apex Aneurysms: A Strategy for Successful Outcome Using the Pretemporal Transzygomatic Transcavernous Approach. Operative Neurosurgery 2005;56:ONS-261-ONS-273. Doi:10.1227/01.NEU.0000156785.63530.4E.
29. Martínez-Pérez R, Tsimpas A, Marin-Contreras F, Maturana R, Hernandez-Alvarez V, Labib MA, et al. The Minimally Invasive Posterolateral Transcavernous-Transtentorial Approach. Technical Nuances, Proof of Feasibility, and Surgical Outcomes Throughout a Case Series of Sphenopetroclival Meningiomas. World Neurosurg 2021;155:e564–75. Doi:10.1016/j.wneu.2021.08.108.
30. Figueiredo EG, Zabramski JM, Deshmukh P, Crawford NR, Preul MC, Spetzler RF. Anatomical and quantitative description of the transcavernous approach to interpeduncular and prepontine cisterns. J Neurosurg 2006;104:957–64. Doi:10.3171/jns.2006.104.6.957.

Ping-Chuan Liu
https://orcid.org/0000-0003-2366-1314
Chun-Fu Lin
https://orcid.org/0000-0001-5831-6620
Sanford P C Hsu

Author contributions: HPC: Conceptualization; PTC, LPC: Project Administration; PTC, LPC: Writing - original draft; HPC, LCF: Writing – review & editing.
Conflicts of interest: The authors report no conflict of interest.
Funding: This study is not sponsored by any organization.