Neurological Surgery and Anatomy 2024, 1(2): 72-76, e-ISSN: 2966-0696
DOI: 10.37085/nsa.2024.16

Review

Historical skull illustrations: Parietal foramen

Maria Rosana de Souza Ferreira[1], Carolina Peixoto Magalhães[1], Maria Carolina Martins de Lima[2], Marcelo Moraes Valença[2]

[1]Departament of Anatomy, Federal University of Pernambuco, Vitória de Santo Antão, Pernambuco, Brazil
[2]Department of Neuropsychiatry, Federal University of Pernambuco, Recife, Pernambuco, Brazil

Introduction
Anatomical illustration has progressed historically to become a means of documentation. The representation of a particular anatomical structure in a drawing/painting meant the artist/anatomist was aware of its presence, position and relation to surrounding structures and can also be used as a primer for tracking the knowledge about such structure. Despite the detailed historical depictions of the skull, the parietal emissary foramen often went unillustrated.
Objective
This study focuses on the parietal foramen and its historical depiction.
Methods
It perused artistic illustrations of the skull to establish by whom and when this foramen was displayed.
Results
Located in the posterior part of the parietal bone, the parietal foramen allows passage for the parietal emissary vein and other structures. Its presence varies among populations, which may explain its omission in some anatomical works. However, artists like Antonio de Pereda and anatomists like Bernhard Siegfried Albinus and John Bell did illustrate it. As other emissary foramina, the parietal emissary foramen has a role in helping regulate intracranial pressure and brain temperature. Its significance has increased throughout human evolution, particularly with the development of bipedalism and larger brain volumes. The foramen may also function as a path in the spread of infection and/or tumors. Recent studies using CT scans have emphasized the importance of recognizing the parietal foramen in imaging and surgical planning.
Conclusion
This paper helps uncover part of the history of neuroanatomical illustration pertaining to the depiction of the parietal foramen and highlights its clinical and surgical importance.

Keywords
Anatomy, Neurosurgery, Parietal foramen, History, Skull, Antonio de Pereda

Edited by:
Juliana Ramos de Andrade

Marcelo Moraes Valença
mmvalenca@yahoo.com.br

Submitted: October 25, 2024
Accepted: November 15, 2024
Published online: November 29, 2024

© Copyright 2024

Neurological Surgery and Anatomy

Introduction

For centuries, the man wanted to know and register the human body. The Greeks started anatomical studies in the 4th century, when Aristotle (385 BC - 323 BC), based on his work with animal dissection, introduced the concept of comparative anatomy (1). In the pre-Renaissance period, works by Galen of Pergamon (129-200), Mondino de Luzzi (1270-1326) and Abū ʿAlī al-Ḥusayn bin ʿAbdullāh ibn al-Ḥasan bin ʿAlī bin Sīnā al-Balkhi al-Bukhari, known in the Occidental world as Avicenna (980-1037), supported the studies of anatomists, such as Leonardo da Vinci (1452-1519) and Andreas Vesalius (1514-1564). Other needs gradually arose, such as illustrating, with higher precision, the anatomical structures. Drawings enter the history of anatomy as a fundamental contribution to registering the understanding of the body, as a means of knowledge and, as a tool for the construction of visual thinking (2,3).

The skull has been depicted by many artists who, through their illustrations, enhanced the understanding of human anatomy. Leonardo da Vinci illustrated the skull in different ways (4) . Andreas Vesalius, considered the "father of modern anatomy", also illustrated the skull in his 1543 work "*De Humani Corporis Fabrica*", considered one of the most influential scientific books of all time (5).

However, when analyzing the paintings and illustrations over time, it is observed that, in the posterior view of the skull, the authors did not highlight the parietal emissary foramen. This foramen receives its name because of its location in the parietal bone, and by giving passage to a vessel, called the parietal emissary vein (6,7). Although other structures may also pass through them (7,8). When present bilaterally, the parietal emissary foramina are symmetrical, roundish structures, located postero- superiorly in the skull, parallel to the sagittal suture (7,9). In the segment where the parietal emissary foramina are located, the sagittal suture may lose its serrated complexity, becoming more rectilinear and the craniometric point is called obelion, due to its similarity to the "obelus" (÷) symbol of Greek origin (9). The fact that the sagittal suture becomes more rectilinear occurs during embryological formation, in the bone plates that form the parietal bones. (10,11).

However, the parietal emissary foramen is not always present, being subject to variations in terms of topography, number and shape (7,10–15). Its prevalence varies according to the different populational groups (6,15–17). This fact may justify the reason why some anatomists did not illustrate the parietal foramen in their work (Figure 1).

However, some authors illustrated the parietal emissary foramen. Antonio de Pereda y Salgado (1611-1678), a Spanish, baroque painter, in one of his paintings, illustrating three skulls, presents the parietal emissary foramina in one of them (Figure 2A).

Bernhard Siegfried Albinus (1697-1770), considered one of the greatest anatomists of the time, illustrated the parietal foramen in his 1747 work "T*abulae sceleti et musculorum corporis humani*" (Figure 2B-C).

In addition to help controlling the intracranial pressure, the emissary veins as a network and the one passing through the parietal foramen, in particular, seem to, play role in regulating brain temperature (19). Comparative biology and fossil evidence indicate that the frequency of emissary venous networks has increased significantly throughout human evolution (19). Before the significant expansion of brain volume in the evolution of Homo sapiens, evidence suggests that hominids first developed bipedalism. This hypothesis is further supported by findings that the parietal foramen began to appear prominently in archaic H. sapiens (19).

Falk (19) believes that there could only be an increase in brain volume when a cooling system, exerted by the emissary's veins, developed, allowing a large brain to be protected from hyperthermia.

In the pursuit of better access to intracranial targets during neurosurgical procedures, surgeons performing a craniotomy often compromise the integrity of the parietal foramen, frequently underestimating the importance of the anatomical structures that traverse it, assuming their roles are minor or are otherwise managed by pia-arachnoid or dura mater structures. However, based on the premise that every anatomical structure exists because it contributes to a physiological function — be it defense, locomotion, hemostasis, or other processes—we suggest that, whenever feasible, efforts should be made to preserve the parietal foramen and the associated neurovascular structures that traverse the intracranial and extracranial compartments. There is neuronal communication between these compartments through nerves that pass via the parietal foramen, and damage to this area may potentially contribute to postoperative pain or unpleasant sensory experiences.

Interestingly, the subcutaneous extension of a parasagittal atypical meningioma through the parietal foramen was reported (20), highlighting a unique and rarely observed pathway of tumor spread. The parietal foramen, often considered a minor anatomical feature, may allow intracranial lesions to extend into the extracranial compartment. This case underscores the clinical significance of the parietal foramen, as its presence can facilitate the extension of intracranial tumors beyond the confines of the cranial cavity, potentially complicating the clinical presentation and surgical management. While the parietal foramen is generally known for allowing neurovascular structures to communicate between the intracranial and extracranial spaces, its role in pathological conditions, such as atypical meningiomas, deserves greater attention.

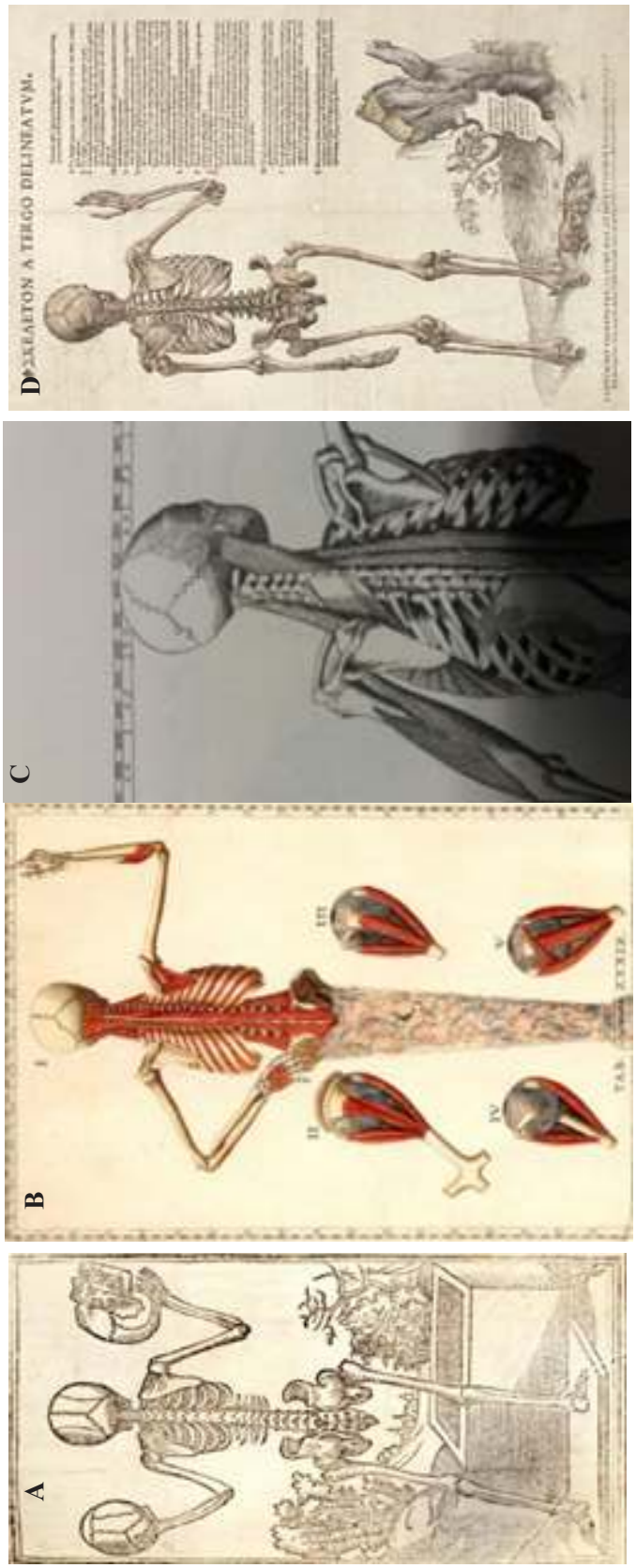

Figure 1. Norma occipitalis. These four authors did not illustrate the parietal foramen: A) Jacopo Berengario da Carpi (c. 1460 – c. 1530) - Anatomia Carpi (1535). B) Bartolomeo Eustachi (c. 1500-1574) - Tabulae Anatomicae (1552). C) Pietro de Cortona (1596 - 1669). D) Andreas Vesalius (1514 - 1564) – De Humani Corporis Fabrica (1543).

Recently, a study on the anatomical aspects of the parietal foramen was conducted (17), paying particular attention to its morphological characteristics and distribution using CT scans. The findings reported have significant clinical implications, especially for imaging diagnosis, intracranial navigation of vascular disorders, and treatment planning. Understanding the precise location and structural variations of the parietal foramen can aid in accurately identifying this anatomical feature on imaging, which is essential for differen

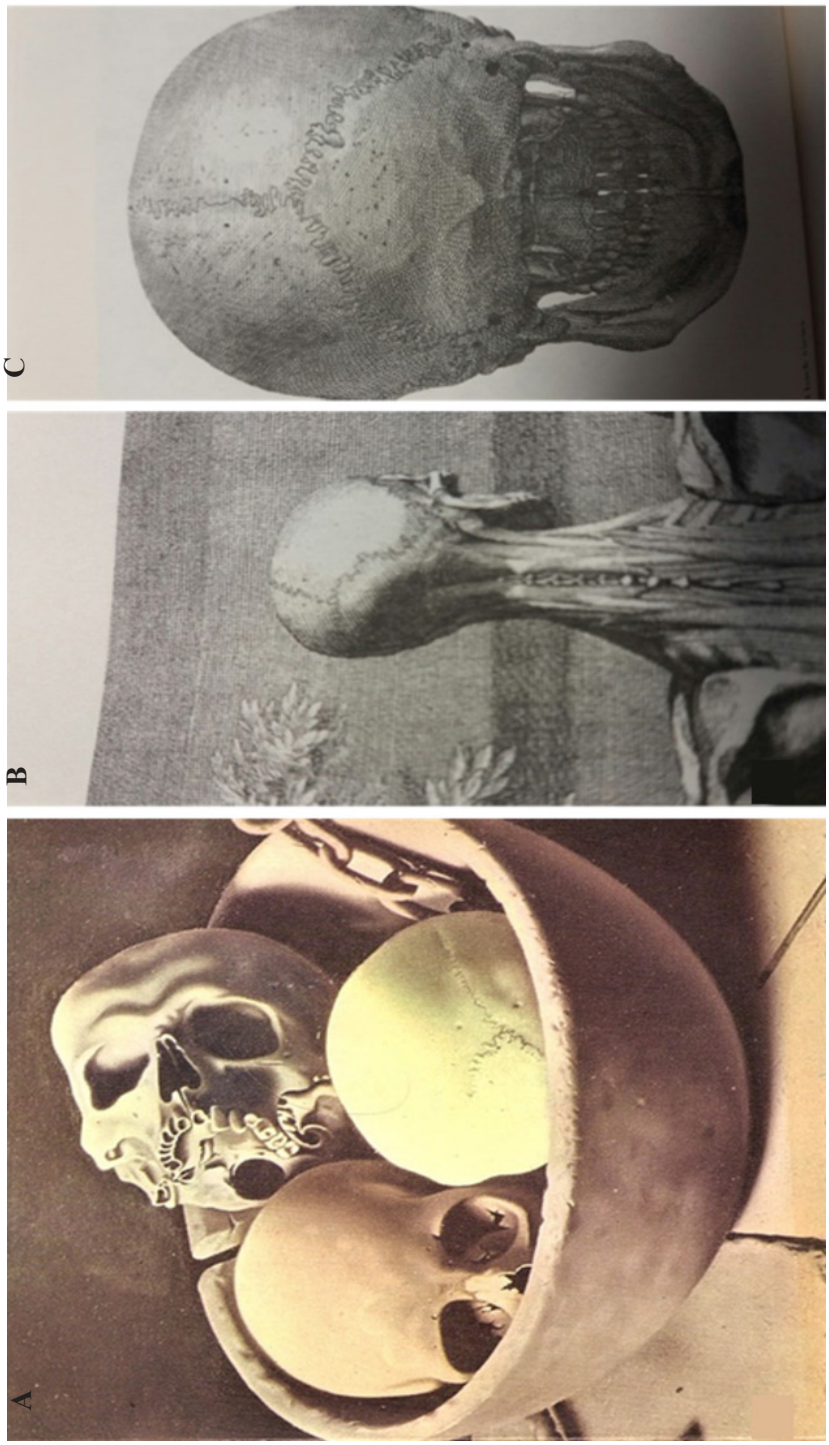

Figure 2. These authors presented the parietal foramen in their drawings: A) Antonio de Pereda y Salgado (1611-1678) in an illustration as early as 1635, B) and C) Bernhard Siegfried Albinus (1697-1770) – *Tabulae sceleti et musculorum corporis humani* (1747). Not only did Albinus present the foramen, but he also observed on the aspect of the sagittal suture at this level

The first book of bones entitled "Anatomy of the Human Body", written by John Bell, a Scottish anatomist and surgeon, published in 1810, can be included in this second list. Not only does it illustrate the parietal emissary foramen but it also offers the following description: "Orifice in the posterior part of the parietal bone, which leads to a vein of the integument and an artery that accompanies the vein, going to the superior sagittal sinus" (18) (Figure 3).

tiating normal variants from pathological conditions. Furthermore, the presence of the parietal foramen plays a critical role in surgical navigation, particularly in procedures involving vascular disorders. This highlights the importance of recognizing the parietal foramen during preoperative planning and intraoperative navigation to ensure safe and effective treatment outcomes.

In conclusion, the parietal foramen may have been overlooked by anatomists in the past, despite its clear visibility upon close examination of the skull calvarium. Examination of numerous dried skulls, a common practice for experienced anatomists who teach regularly, reveals the fairly constant presence, of at least one parietal foramen, consistently located in the posterior part of the parietal bone, near the midline. This observation underscores the importance of recognizing and preserving this anatomical feature during neurosurgical interventions.

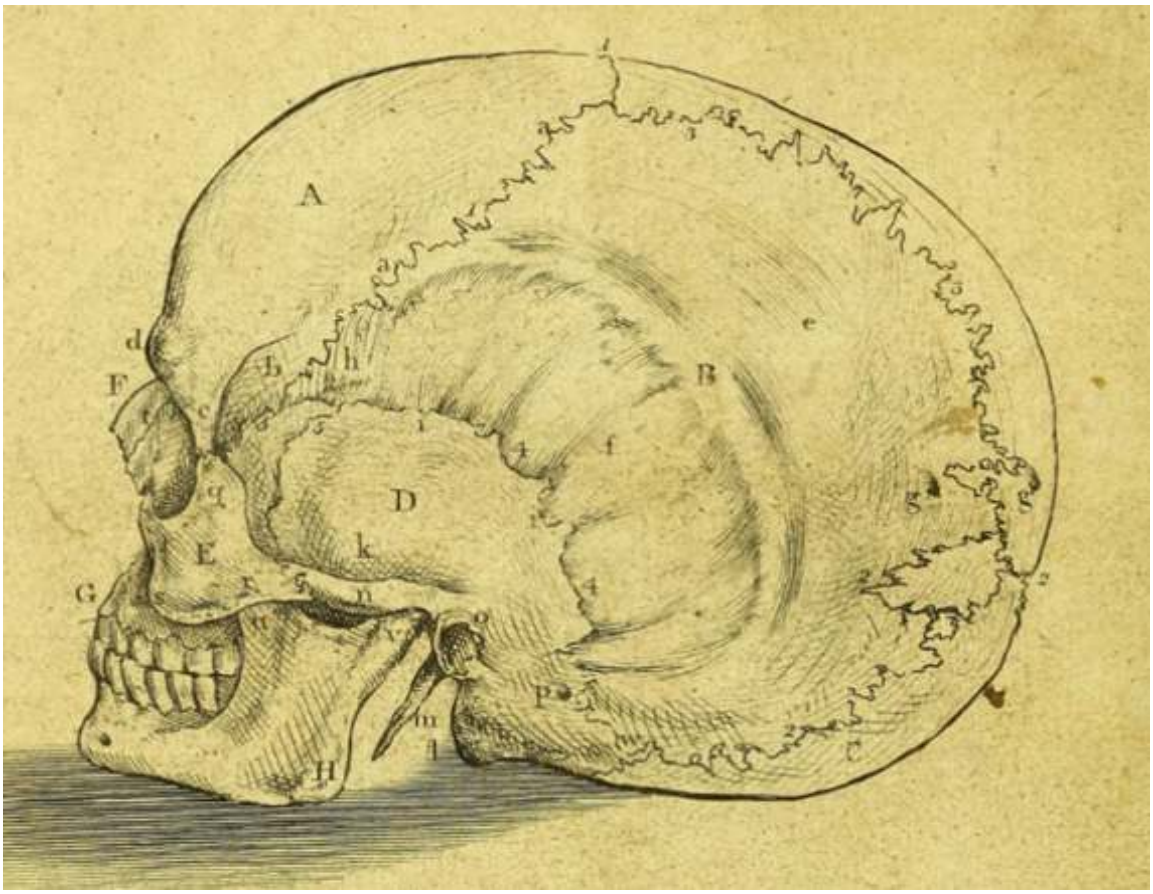

Figure 3. Another illustration of the skull highlighting the parietal foramina. This image is from "Anatomy of the Human Body," by John Bell, published in 1810. The illustration depicts bilateral and adequately located parietal emissary foramina.

References

1. Blits KC. Aristotle: Form, function, and comparative anatomy. Anat Rec. 1999 Apr 15;257(2):58–63. Doi:10.1002/(SICI)1097-0185(19990415)257:2<58::AID-AR6>3.0.CO;2-I
2. Ghosh SK. Evolution of illustrations in anatomy: A study from the classical period in Europe to modern times. Anat Sci Educ. 2015 Mar 22;8(2):175–88. Doi: 10.1002/ase.1479
3. Olry R. Medieval neuroanatomy: The text of Mondino Dei Luzzi and the plates of guido da Vigevano*. J Hist Neurosci. 1997 Aug;6(2):113–23. Doi: 10.1080/09647049709525696
4. Missinne SJ. The oldest anatomical handmade skull of the world c. 1508: 'The ugliness of growing old' attributed to Leonardo da Vinci. Wiener Medizinische Wochenschrift. 2014 Jun 23;164(11–12):205–12. Doi: 10.1007/s10354-014-0282-0
5. Hast MH, Garrison DH. Vesalius on the variability of the human skull: Book I Chapter V ofDe humani corporis fabrica. Clinical Anatomy. 2000;13(5):311–20. Doi: 10.1002/1098-2353(2000)13:5<311::AID-CA1>3.0.CO;2-X
6. Murlimanju B V., Saralaya V V., Somesh MS, Prabhu L V., Krishnamurthy A, Chettiar GK, et al. Morphology and topography of the parietal emissary foramina in South Indians: an anatomical study. Anat Cell Biol. 2015;48(4):292. Doi: 10.5115/acb.2015.48.4.292
7. de Souza Ferreira MR, Galvão APO, de Queiroz Lima PTMB, de Queiroz Lima AMB, Magalhães CP, Valença MM. The parietal foramen anatomy: studies using dry skulls, cadaver and in vivo MRI. Surgical and Radiologic Anatomy. 2021 Jul 5;43(7):1159–68. Doi: 10.1007/s00276-020-02650-0
8. Yoshioka N, Rhoton AL, Abe H. Scalp to Meningeal Arterial Anastomosis in the Parietal Foramen. Operative Neurosurgery. 2006 Feb 1;58(suppl_1):ONS-123-ONS-126. Doi: 10.1227/01.NEU.0000193516.46104.27
9. Currarino G. Normal variants and congenital anomalies in the region of the obelion. American Journal of Roentgenology. 1976 Sep 1;127(3):487–94. Doi: 10.2214/ajr.127.3.487
10. Wysocki J, Reymond J, Skarzyński H, Wróbel B. The size of selected human skull foramina in relation to skull capacity. Folia Morphol (Warsz). 2006 Nov;65(4):301–8.
11. Shmarhalov A, Vovk O, Ikramov V, Acharya Y, Vovk O. Anatomical variations of the parietal foramen and its relations to the calvarial landmarks: a cross-sectional cadaveric study. Wiadomości Lekarskie. 2022 Jul;75(7):1648–52. Doi: 10.36740/WLek202207106
12. Tsutsumi S, Nonaka S, Ono H, Yasumoto Y. The extracranial to intracranial anastomotic channel through the parietal foramen: delineation with magnetic resonance imaging. Surgical and Radiologic Anatomy. 2016 May 24;38(4):455–9. Doi: 10.1007/s00276-015-1579-4
13. Penteado C V, Santo Neto H. The number and location of the parietal foramen in human skulls. Anat Anz. 1985;158(1):39–41.
14. Naidoo J, Luckrajh JS, Lazarus L. Parietal foramen: incidence and topography. Folia Morphol (Warsz). 2021 Dec 2;80(4):980–4. Doi: 10.5603/FM.a2020.0140
15. Liu D, Yang H, Wu Jua, Li JH, Li YK. Anatomical observation and significance of the parietal foramen in Chinese adults. Folia Morphol (Warsz). 2022 Dec 8;81(4):998–1004. Doi: 10.5603/FM.a2021.0106
16. Kitazawa M. Parietal foramen in modern Japanese calvaria, its frequency and location. Journal of Nippon Medical School. 1987;54(3):229–43. Doi: 10.1272/jnms1923.54.229
17. Al-Shuaili A, Al-Ajmi E, Mogali SR, Al-Qasmi S, Al-Mufargi Y, Kariyattil R, et al. Computed-tomography evaluation of parietal foramen topography in adults: a retrospective analysis. Surgical and Radiologic Anatomy. 2024 Jan 27;46(3):263–70. Doi: 10.1007/s00276-023-03284-8
18. Bell J, Charles Bell. The anatomy and physiology of the human body. Containing the anatomy of the bones, muscles, and joints; and the heart and arteries. Vol. 3. New york: Collins & co; 1822. 1–394 p.
19. Falk D. Evolution of cranial blood drainage in hominids: Enlarged occipital/marginal sinuses and emissary foramina. Am J Phys Anthropol. 1986 Jul 7;70(3):311–24. Doi: 10.1002/ajpa.1330700306
20. Nawashiro H, Nawashiro T, Nawashiro A. Subcutaneous Extension of Parasagittal Atypical Meningioma Through Parietal Foramen. World Neurosurg. 2019 May;125:104–5. Doi: 10.1016/j.wneu.2019.01.185

Maria Rosana de Souza Ferreira
https://orcid.org/0000-0003-1166-5342
Carolina Peixoto Magalhães
https://orcid.org/0000-0003-3556-1011
Maria Carolina Martins de Lima
https://orcid.org/0000-0002-0197-3520
Marcelo Moraes Valença
https://orcid.org/0000-0003-0678-3782

Authors Contributions: MMV, MRSF, CPM: Acquisition, analysis, or interpretation of data for the work.

CM, MMV: Substantial contributions to the conception or design of the work reviewing it critically for important intellectual content, final approval of the version to be published.