Neurological Surgery and Anatomy 2024, 1(2): 67-71, e-ISSN: 2966-0696
DOI: 10.37085/nsa.2024.15

Original

A handy tool to teach microneurosurgical anatomy of uncus

Carolina Martins[1,2], Vicent Quilis Quesada[3], Antonio Cavalcanti de A. Martins[2], Marcelo Moraes Valença[1], Hung Tzu Wen[4]

[1]Department of Neuropsychiatry, Federal University of Pernambuco, Recife, Pernambuco, Brazil
[2]Department of Anatomy, Medical School of Pernambuco, Recife, Pernambuco, Brazil
[3]Department of Neurosurgery and Department of Human Anatomy and Embriology, University of Valencia, Valencia, Spain
[4]Department of Neurosurgery, University of Sao Paulo, Sao Paulo, Sao Paulo, Brazil

Background
Detailed anatomical knowledge of the parahippocampal gyrus and uncus is paramount to neurosurgeons. Mesial temporal and limbic anatomy are an integral part of the microneurosurgical anatomy curriculum for neurosurgical residents around the world. It is intricate, detailed anatomy and several tools have been used to ease the learning curve on this subject. This paper presents a simple, low-technological mnemonics and frame-model to help learn the microsurgical anatomy of the uncus.
Methods
Microsurgical anatomy of the uncus is presented using cadaveric specimens placed side-by-side to views of the right hand with fingers flexed and the wrist adducted.
Results
By holding the right hand with fingers and wrist flexed, a resemblance of the uncal morphology can be appreciated. The index and second fingers represent the two gyri on the anterior surface of the uncus. The index resembles the semilunar gyrus, the second finger stands for the ambient gyrus, while the space between them accounts for the semiannular sulcus (sulcus *semiannularis*). The three following fingers represent the uncal morphology seen once the parahippocampal lip is removed, by working through the uncal sulcus. The middle finger is the uncinated gyrus, the annular finger, represents the band of Giacomini and the pinky finger represents the intralimbic gyrus.
Conclusion
A "handy," portable reminder of the microsurgical anatomy of the uncus - a required milestone in neurosurgery – is presented.

Keywords
Continuing medical education, Parahippocampal gyrus, Hippocampus, Neuroanatomy, Neurosurgery

Edited by:
Juliana Ramos de Andrade

Carolina Martins
cmrecife@hotmail.com

Submited: October 7, 2024
Accepted: November 3, 2024
Published online: 29 August, 2024

© Copyright 2024

Introduction

Detailed anatomical knowledge of the parahippocampal gyrus and uncus is paramount to neurosurgeons. It allows for adequate analysis and interpretation of neuroimaging data and safe and accurate performance of neurosurgical resections in the mesial temporal area (1). It is a requirement for neurosurgeons to stay updated with the many advances concerning the limbic lobe and be able to communicate with other specialists in associated fields of knowledge.

Mesial temporal and limbic anatomy are an integral part of the microneurosurgical anatomy curriculum for neurosurgical residents and explored in theoretical as well as theoretical-practical courses using microsurgical dissections of cadaveric brains around the world. It is intricate, detailed anatomy and several tools have been used to ease the learning curve on this subject. In the educational realm, these range from sequential projection of 2D and 3D images depicting the stepwise dissection of this area in injected human cadaveric specimens, up to the actual performance of a guided dissection under the microsurgical microscope.

A two-stage learning process, based on a frame-model, is an accepted human learning strategy (2,3). Once information is grasped in this way it can be further detailed and exceptions applied. This paper presents a simple, low-technological mnemonics and frame-model to help learn the microsurgical anatomy of the uncus.

Methods

Microsurgical anatomy of the uncus is presented using cadaveric specimens placed side-by-side to views of the right hand with fingers flexed and the wrist adducted (Figure 1).

Results

By holding the right hand with fingers and wrist flexed, a resemblance of uncal morphology can be appreciated (Figure 1 A-D). The index and second fingers represent the two gyri on the anterior surface of the uncus. The index resembles the semilunar gyrus, the second finger stands for the ambient gyrus, while the space between them accounts for the semiannular sulcus (sulcus *semiannularis*). The three following fingers represent the uncal morphology seen once the parahippocampal lip is removed, by working through the uncal sulcus. The middle finger is the uncinated gyrus, the two phalanges standing for the squares this gyrus usually presents (also called external hippocampal digitations) (4). The annular finger, with its interphalangeal joint - standing out the most - represents the levelling that the band of Giacomini has with the largest lateral to medial diameter of the uncus, while its tip, pointing to the palmaris longus tendon, stands for its continuation with the dentate margin (*margo denticulatus*) of the dentate gyrus (the band of Giacomini is the tail of dentate gyrus). The pinky finger represents the intralimbic gyrus. The radial border of the flexed arm represents the fimbria of fornix, above which the choroidal fissure opens. The ulnar border of the arm, and the round aspect it assumes when the arm is flexed, stands for the subiculum of the parahippocampal gyrus.

Discussion

The sulci and gyri of the uncus are located over its anterior and posterior surfaces. While the ones located on the anterior surface of the uncus are related to the amygdala and readily seen when facing this region in an anatomical specimen, the posterior ones are partially covered by the inferior surface of the parahippocampal gyrus. This last set of gyri and sulci represent the external hippocampal digitations of the pes hippocampi and the angled tail of the dentate gyrus.

The anterior surface of the uncus presents superiorly the semilunar gyrus, bounded above by the entorhinal sulcus, and separated from the ambient gyrus by the semiannular sulcus (sulcus semiannularis). The semilunar gyrus covers the cortical nuclei of the amygdala (the earliest, phylogenetically), while the ambient gyrus is also named periamygdaloid cortex. The ambient gyrus is continuous with the entorhinal area, which roughly spans from the extension of the rhinal sulcus anteriorly to the collateral sulcus, laterally (and to Brodmann area 28). Sometimes, at the area of the apex of the uncus, an intrarhinal sulcus can be devised, helping differentiate the ambient gyrus and the entorhinal area (See double yellow asterisk at Figure 1A1). The entorhinal area is easily identified by its coarse gray-matter covering that clearly differs from the shiny, smooth gray-matter aspect at the posterior subiculum and parahippocampal gyrus. This coarse aspect is given by the clumping of neurons on the second - out of the three - cortical layers in this area. Once thought to represent *post-mortem* artifacts, these findings were named Retzius verrucae (5) or verrucae gyri hippocampi (4). Alois Alzheimer, in his initial description of the progressive memory disturbance that was later named after him, emphasized the loss of this morphology (5). Vries (5), signaled the selective presence of neurofibrillary tangles in those areas in patients with Alzheimer's disease. Recently, studies using 7T MRI have been able to confirm these findings ex vivo (6).

On the cisternal side, the anterior surface of the uncus is related to the supraclinoid carotid, its uncal branches and its bifurcation, as well as the anterior choroidal artery, which describes an ascending course along this surface - around the area of the semilunar sulcus (4), to reach the inferior choroidal point (7,8).

The posterior surface of the uncus is marked by the uncal sulcus that is usually related to the posterior cerebral artery. The uncal sulcus is formed by the folding of the anterior part of parahippocampal gyrus to form the uncus

and should not be confused with a hippocampal notch or marking, left in this area by the edge of the tentorium. Once the inferior lip of the parahippocampal gyrus is removed, this surface presents three sequential gyri (7,9). The uncinate gyrus is formed by two or three small, square-shaped parts, is mostly formed by CA1, and separates from the band of Giacomini by the superficial hippocampal sulcus. The band of Giacomini, also called tail of the dentate gyrus, is sinuous and slightly elevated when compared to the other adjacent gyri. This elevated aspect is produced by its two defining sulci. The anterior (rostral) limit of the band is the superficial hippocampal sulcus (See broken blue line at Figure 1D), while its posterior (dorsal) limit is called pre-limbic sulcus (See dotted green line at Figure 1D). Embryologically, the hippocampal sulcus, located between the dentate gyrus and the subiculum of the parahipocampal gyrus, is no other than the callosal sulcus, only buried by the development of the temporal lobe neocortex (10). The band of Giacomini is roughly aligned with the medially pointing apex of the uncus or its largest medio-lateral diameter and is the anterior continuation of the dentate gyrus. The

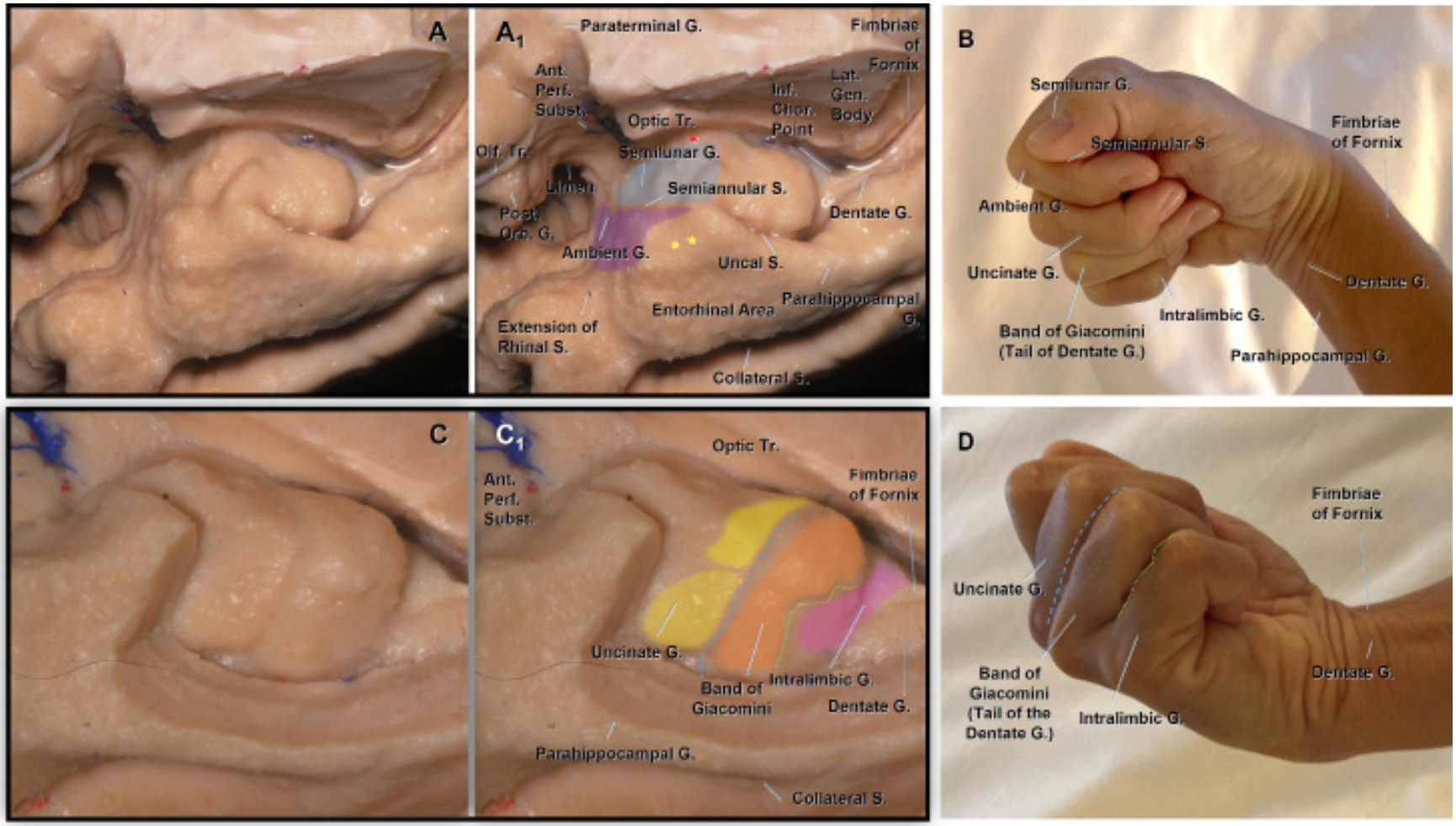

Figure 1. A and A1. Medial view of the right uncus. B. Right hand with fingers flexed and wrist adducted. The correlations with the anatomy of the uncus are presented. C and C1. Infero-medial view of the right posterior surface of the uncus, once the parahippocampal gyrus is resected. D. Corresponding adjustment of the hand-model and anatomical correlations are presented. *Ant.: Anterior; Chor.: Choroidal; G.: Gyrus, Gyri; Gen.: Geniculate; inf.: Inferior; Lat.: Lateral; Orb.: Orbital; Olf.: Olfactory; Perf.: Perforated; Post.: Posterior; S.: Sulcus, Sulci; Subst.: Substance; Tr.: Tract. Single Red Asterisk: Endorhinal Sulcus. Double Yellow Asterisk: Intrarhinal Sulcus. Broken blue line: superficial part of hippocampal sulcus. Dotted green line: pre-limbic sulcus.*

intralimbic gyrus is the most posterior one, closer to the subiculum and at angle with the fimbria. The intralimbic gyrus has also been called posterior apex and hippocampus inversus (4). This last name derives from the fact that as the fimbria does not cover this part of hippocampus, therefore CA3 and 4 areas are superficially exposed (this also happens at the hippocampal tail).

Therefore, the dentate gyrus closely follows the hippocampal gyrus at its entire length. This may not be noticed at first, because the dentate gyrus receives different names at its most anterior part (where it is the band of Giacomini) and its posterior part (where it is the fasciola cinerea). The dentate gyrus on its most external portion is called dentate margin (*margo denticulatus*) and presents 15-20 denticulations. The denticulations are best seen on the middle portion of the longitudinal extension of this gyrus. In fact, it is the dentate gyrus that bears the resemblance to the seahorse or silkworm (11), a fact clearly seen during dissection in the lab.

From a purely anatomical standpoint, together Amon's horn, pes hippocampi and dentate gyrus comprise the hippocampal formation or retrocommissural hippocampus, the part of the hippocampus most developed in humans. A more recent, functional understanding of the term "hippocampal formation" though comprises a single functional unit composed by structures linked by the polysynaptic pathway (4,11). This functional understanding therefore includes the entorhinal area, gyrus dentatus, cornu Ammonis and the subiculum.

Posteriorly, the dentate gyrus is continuous with the fasciola cinerea (and possibly the medial longitudinal striae). The fasciola cinerea should not be mistaken with the fasciolar gyrus, a whitish hippocampal band, composed by CA3 covered by alveus (hence the whitish aspect) that becomes exposed when once more (as in the hippocampal head) the fimbria detaches itself from the hippocampus (this time to follow its crus) (4). As its anterior counterpart (the intralimbic gyrus), this area is also called hippocampus inversus. The fasciola cinerea and the gyrus fasciolaris above it are separated by the dentatofasciolar sulcus, which is only present at the posterior third of the medial surface of the body and tail of the hippocampus. The fasciolar gyrus is prolonged posteriorly as the subesplenial gyrus and continues and indusium griseum along the dorsum of corpus callosum. The indusium griseum - in its turn - is continuous with the paraterminal gyrus, in the subcallosal area. While the paraterminal gyrus is called precommissural hippocampus, the indusium griseum and its longitudinal striae (medial and lateral) are the supracommissural hippocampus - these last two being more developed in macrosmatic mammals than in humans (5,9). Nor should the fasciola cinerea be confused with the gyri of Andrea Retzius. These gyri - when present - elevate the fasciola cinerea at the posterior part of the hippocampal formation and consist of the heavily folded CA1 layer showing up at the posterior surface of the parahipocampal gyrus (4).

Low-technological mnemonics have proved useful in teaching complex anatomy to surgical residents and medical students (12). During our practical courses in several continents, over the last 20 years, we have collaborated in gradually perfecting these mnemonics, aiming to ease the introduction of learners into the complex anatomy of the uncus. Because it consists of a tridimensional, portable model that can be consulted anytime – including the anatomical lab and into the operating theatre – we have seen a warm reception and an enthusiastic use of it, revealing the space a tool like that has in the neurosurgical field.

Conclusion

We have presented a "handy," portable reminder of the microsurgical anatomy of the uncus, a required milestone in neurosurgery. This tool has proved itself welcome, readily understood, and quickly grasped by trainees during our courses worldwide.

References

1. Bonilha L, Kobayashi E, Mattos JP V., Honorato DC, Li LM, Cendes F. Value of extent of hippocampal resection in the surgical treatment of temporal lobe epilepsy. Arq Neuropsiquiatr. 2004 Mar;62(1):15–20. Doi: 10.1590/S0004-282X2004000100003
2. Misselbrook D. Thinking About Medicine: An Introduction to the Philosophy of Healthcare. 1st ed. 2024. 1–336 p.
3. Dehaene S. How We Learn: The New Science of Education and the Brain. Penguin Books; 2021. 1–352 p.
4. Duvernoy HM, Cattin F, Risold PY. The Human Hippocampus. Berlin, Heidelberg: Springer Berlin Heidelberg; 2013. 1 p. Doi: 10.1007/978-3-642-33603-4
5. Vries H de. The hippocampal formation in normal aging and Alzheimer's disease: a morphometric study [Doctorate]. Radboud University; 1990.
6. Augustinack JC, Huber KE, Postelnicu GM, Kakunoori S, Wang R, van der Kouwe AJW, et al. Entorhinal verrucae geometry is coincident and correlates with Alzheimer's lesions: a combined neuropathology and high-resolution ex vivo MRI analysis. Acta Neuropathol. 2012 Jan 13;123(1):85–96. Doi: 10.1007/s00401-011-0929-5
7. Wen HT, Rhoton AL, de Oliveira E, Cardoso ACC, Tedeschi H, Baccanelli M, et al. Microsurgical Anatomy of the Temporal Lobe: Part 1: Mesial Temporal Lobe Anatomy and Its Vascular Relationships as Applied to Amygdalohippocampectomy. Neurosurgery. 1999 Sep;45(3):549–92. Doi: 10.1097/00006123-199909000-00028
8. Campero A, Tro´ccoli G, Martins C, Fernandez-Miranda JC, Yasuda A, Rhoton AL. Microsurgical Approaches to the Medial Temporal Region: An Anatomical Study. Operative Neurosurgery. 2006 Oct 1;59(suppl_4):ONS-279-ONS-308. Doi: 10.1227/01.NEU.0000223509.21474.2E
9. Ribas GC. The cerebral sulci and gyri. Neurosurg Focus. 2010 Feb;28(2):E2. Doi: 10.3171/2009.11.FOCUS09245
10. Kier EL, Fulbright RK, Bronen RA. Limbic lobe embryology and anatomy: dissection and MR of the medial surface of the fetal cerebral hemisphere. AJNR Am J Neuroradiol. 1995 Oct;16(9):1847–53.
11. El-Falougy H, Benuska J. History, anatomical nomenclature, comparative anatomy and functions of the hippocampal formation. Bratisl Lek Listy. 2006;107(4):103–6.
12. Pauli EM, Staveley-O'Carroll KF, Brock M V., Efron DT, Efron G. A Handy Tool to Teach Segmental Liver Anatomy to Surgical Trainees. Archives of Surgery. 2012 Aug 1;147(8):692. Doi: 10.1001/archsurg.2012.689

Carolina Martins
https://orcid.org/0000-0002-0197-3520
Vicent Quilis Quesada
https://orcid.org/0000-0001-8961-6896
Antonio Cavalcanti de A. Martins
https://orcid.org/0000-0002-1249-8622
Marcelo Moraes Valença
https://orcid.org/0000-0003-0678-3782
Hung Tzu Wen

Authors Contributions: CM, VQQ, HTW, acquisition, analysis, or interpretation of data for the work; CM, ACAM, MMV; substantial contributions to the conception or design of the work reviewing it critically for important intellectual content, final approval of the version to be published.
Funding: This research did not receive any specific grant from funding agencies in the public, commercial, or not-for-profit sectors.
Declarations of interest: none