Neurological Surgery and Anatomy 2024, 1(2): 56-66, e-ISSN: 2966-0696
DOI: 10.37085/nsa.2024.14

Original

# Problem based neuroanatomy of cranial nerves: case of nerve intermedius

Carolina Martins[1,2], João Gonçalves da Silva[2], Leíla Ferraz[2], Maysa Matos[2], Maria Clara S. Moreira[2], Antonio Cavalcanti de A. Martins[2,3]

[1]Federal University of Pernambuco, Recife, Pernambuco, Brazil
[2]Medical School of Pernambuco (FPS/IMIP), Recife, Pernambuco, Brazil
[3]Institute of Integral Medicine Prof. Fernando Figueira, Recife, Pernambuco, Brazil

**Introduction**
Neuroanatomy taught at Medical School needs to be clinically meaningful and guide future acquisition of knowledge helpful in diagnosing and treating patients. Problem-based anatomy has been used to help bridge the gap between knowledge acquired in the lab and the requirements needed for daily medical practice.
**Objective**
This study evaluates the inception of data from Anatomage© Table combined with microsurgical dissection of cadaveric human injected specimens, as auxiliary to acquisition of anatomical milestones required for the cranial nerves, for medical students.
**Methods**
The study was conducted at Medical School of Pernambuco, Brazil. The Anatomage© Table 10.0 was browsed for clinical cases, whose images would illustrate potential or overt pathological involvement of at least one segment of a cranial nerve. Each case was combined with microsurgical anatomy of the region to build an independent, question-lead, educational content, clarifying the anatomical milestones required to interpret, evaluate and treat similar patients.
**Results**
Seventeen illustrative clinical cases were selected for this purpose among 52 in-built cases at this version of the anatomical table. The inclusion of clinical cases brought a new appeal for the cranial nerve content, since it could be included both at graduation or post-graduate levels. Beyond signaling the continuous, individual process of learning anatomy, it also offers support beyond the lab walls, for the student on his/her individual learning journey.
**Conclusion**
This study displays the potential of technological tools, when combined with other resources, namely microsurgical dissections, to allow for creation of new and clinically significant learning resources.

**Keywords**
Cranial nerves, Medical schools, Neuroanatomy, Cadaver, Human, Students, Medical Students

**Edited by:**
Marcelo Moraes Valença

Carolina Martins
cmrecife@hotmail.com

Submited: October 1, 2024
Accepted: November 3, 2024
Published online: December 31, 2024

© Copyright 2024

# Introduction

Neuroanatomy taught at Medical School needs to be clinically meaningful and guide future acquisition of knowledge that is significant to diagnosing and treating patients.

Problem-based anatomy has been used to help bridge the gap between knowledge acquired in the anatomy lab and the requirements needed to daily medical practice.

This study evaluates the inception of data from an Anatomage© Table 10.0 combined with microsurgical dissection of cadaveric human injected specimens, acquired in 2D and 3D, as an auxiliary to the acquisition of the anatomical milestones required for the anatomy of the cranial nerves for graduation and post-graduation medical students.

# Methods

The study was registered and conducted at Medical School of Pernambuco, Brazil. It was approved at the IRB and Ethics Committee (CAAE 80187124.6.0000.5569).

The Anatomage© Table (Anatomage Inc., San Jose, CA is an international venture with collaboration with the Stanford Clinical Anatomy Department (1). Its 10.0 version houses acquired multiaxial imaging of the body of donors, together with corresponding imaginological and histological imaging. Its functionalities allow selection, enlargement, rotation, removal ("electronic dissection"), replacement, and multiplanar reconstruction of anatomical data. Besides the complete donor's image dataset (5 donor's datasets, in this version), the table also bears prossections of specific areas, and clinical cases. The Anatomage© Table, version 10.0, was browsed for clinical cases, whose images would illustrate potential or overt pathological involvement of at least one segment of a cranial nerve.

Each selected case was combined with 2D and 3D images of the microsurgical anatomy of the region. The microsurgical dissections of injected cadaveric specimens were performed using the magnification of the surgical microscope (Carl Zeiss Inc., Göttingen, Germany) and endoscope (Karl Storz, Tuttlingen, Germany ), according with the tradition perfected by Professor Albert Rhoton Jr, and his team (George Schrader Colter International Microsurgical Anatomy Laboratory, University of Florida, US), by the senior authors and are now part now a part of the extensive anatomical archive, The Rhoton Collection©, at the care of the American Association of Neurological Surgeons.

The resulting combination of clinical cases, Anatomage© data and corresponding microsurgical anatomy of injected human cadaveric specimens allowed for the creation of new, self-applied, question-lead, educational content, clarifying the anatomical milestones required to interpret, evaluate and treat similar patients.

Seventeen illustrative clinical cases were selected for this purpose among 52 in-built head cases at this version of the tridimensional anatomical table. One such case, requiring analysing of the anatomy of the temporal bone is presented. The temporal bone is a complex anatomical subject. Considering the cranial nerves, the temporal bone has features related to the anatomy of at least five of such nerves, namely the facial (VIIa), intermedius (VIIb), cochlear (VIIIc), superior and inferior vestibular nerves (VIIIvs and VIIIvi, respectively). It is also a hub for less known parts of the glossopharyngeal (IX) and vagus (X) nerves in the form of their contributions (Jacobsen's and Arnold's branches) to the tympanic plexus.

Clinically, temporal bone tomograms and its 3D reconstructions can be used to identify bone landmarks related to neural and vascular structures, inspect compartments such as the tympanic and epitympanic spaces, the mastoid air cells, the carotid canal and the facial hiatus, and/or check the integrity of the anatomical elements as the cochlea and semicircular canals. A temporal bone computed tomography (CT) has been included among the normal case examples of the 10.0 version of the Anatomage© Table. It has been chosen to help consolidate the temporal bone as an important hub on the trajectory of the different fibers composing the nervus intermedius (VIIb).

# Results

Didactical Aspects

It is inside the temporal bone that the autonomic parasympathetic efferent fibers (which arise at the superior and inferior salivatory nuclei at the brainstem and follow the VIII, to subsequently cruise with the VIIa) diverge to supply the lacrimal gland ("circuit of tears") and the submandibular and submaxillary salivary glands ("salivary circuit"), respectively. It is also inside the temporal bone that the dual general sensory input (arising from the choana/nasopharynx and auricle and cruising with the VIIb and IX, respectively) as well as the special sensory fibers (taste from 2/3 of the tongue, cruising through the lingual nerve of CNV3 and then with the chorda tympani nerve, through the petrotympanic fissure) eventually reach the nervus intermedius (CN VIIb), and through it, the trigeminocervical nuclear complex at the brainstem.

Three ganglia are therefore related to VIIb: a) pterygopalatine and b) submandibular ganglia for autonomic fibers to synapse and originate postganglionic short parasympathetic fibers, and c) geniculate ganglia for the sensory unipolar neurons to receive its peripheral extensions and dispatch its central connections. Embryologically, these ganglia have different origins. While the pterygopalatine and submandibular arise from the neural crest, the geniculate ganglion has its origins at the ectodermal placode (2).

Because this anatomy is seldom specifically approached - and when done it is usually mixed with the VIIa trajectory, we have chosen to exemplify particularly the portion related to the "circuit of tears", the

efferent parasympathetic segment of the nerve that veers away from the geniculate ganglion at or immediately below the anterior surface of the temporal bone, and whose autonomic fibers will eventually supply the lacrimal gland.

The "Circuit of Tears"

The autonomic or efferent parasympathetic fibers that reach the lacrimal glands and stimulate tear production, originate from the superior salivary nuclei, a third-tier nuclei in the basal or motor region of the brainstem (3), identified at the pontine level, along the floor of the IV ventricle, medial to the limiting sulcus and lateral to the facial colliculus (4,5) (Figure 1 A and B). From there the fibers cross the pons (intra-axial segment) and emerge at the pontomedullary sulcus, between the VIIa and the VIII nerves (Figure 1 C-D), therefore its name: intermedius (meaning "in between") (6).

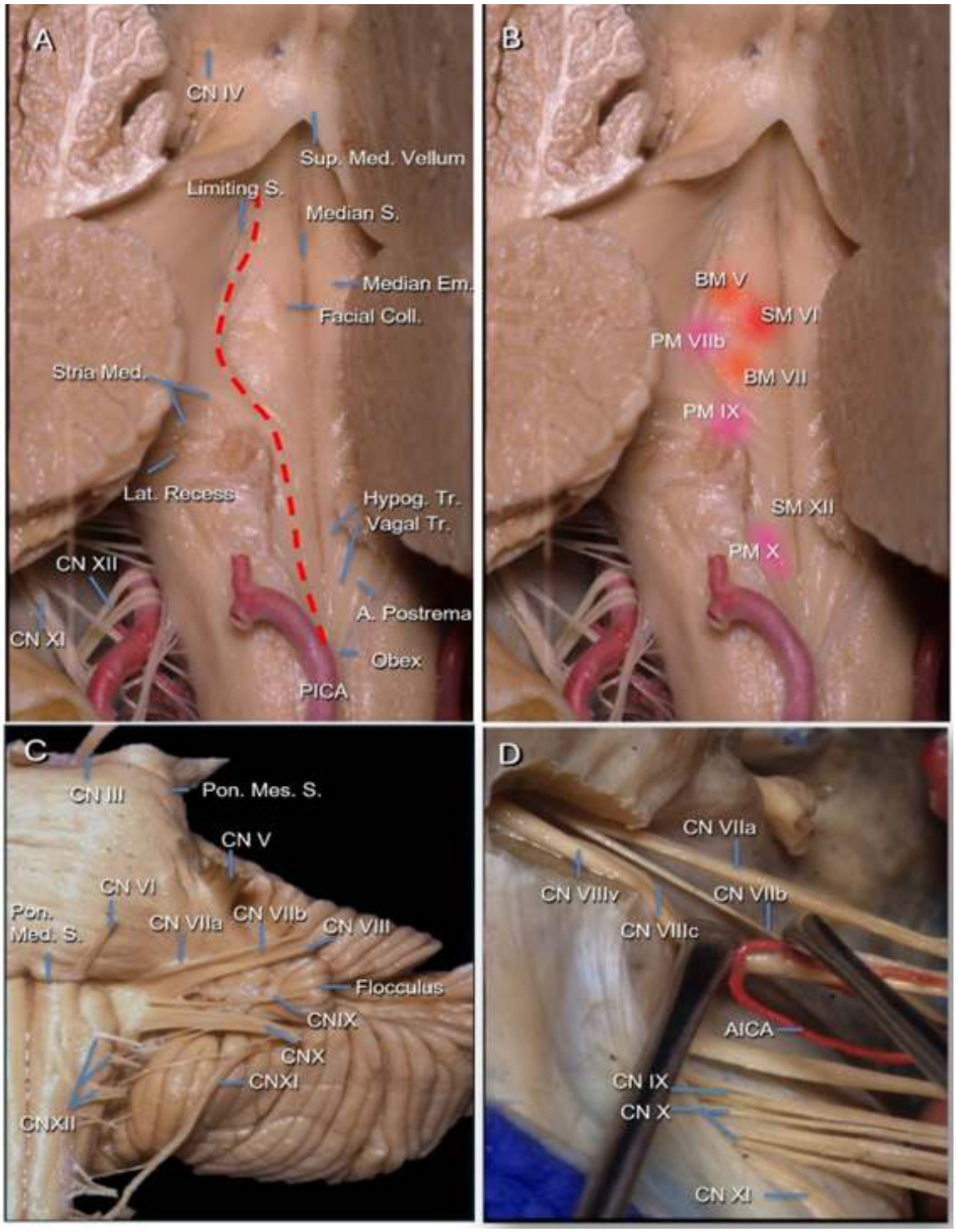

Figure. 1

A. The cerebellum has been split through the vermis to expose the floor of the IV ventricle, whose morphology retains close resemblance to the neural tube. In the neural tube, Wilhem His (1892-1893) first noticed the correlative topography of the notochord and named on its lateral wall, the basal and alar plates, separated by the limiting sulcus. Molecular biology has confirmed this dorsoventral pattern, which is determined by morphogens like bone morphogenetic proteins (BMPs) and sonic hedgehog (3). In the floor of the IV ventricle, the basal plate corresponds to the area medial to the limiting sulcus (whose entire course is highlighted with a red dotted line on the left side). At the pontine part of the floor, this area is called median eminence and bears an elevation - the facial colliculus - on each side, marking the internal bend of the facial nerve fibers (internal genu of the CN VII) around the abducens nuclei. B. The nuclei within each basal plate area are arranged into 3 columns: a) somatic motor, adjacent to the floor plate (median sulcus) and from cranial to caudal containing: the nuclei to nerves: (III and IV) (not shown), VI (facial colliculus) and XII (hypoglossal trigone); a second, slightly lateral column, formed by b) brachial motor nuclei of: V (masticatory nuclei), VII (facial expression muscles), IX, X and XI (nucleus ambiguous) (not shown); and a third, c) preganglionic parasympathetic column: containing the accessory nucleus of III nerve complex (not shown), VII (superior salivatory), IX (inferior salivatory), and the dorsal nucleus of vagus (X). This last column is the one closest to the basal-alar boundary (limiting sulcus). It is from this third-tier, parasympathetic preganglionic nuclei of the intermedius - the superior salivatory nucleus - that the fibers of the salivary circuit arise. This nuclear arrangement is a strong reason to understand the intermedius as a cranial nerve in its own right. C. Frontal view of the left cerebellopontine angle. Traversing the brainstem, the fibers from the superior salivary nucleus emerge at the lateral part of the pontomedullary sulcus, between the VIIa and VIII fibers, hence its name. Scarpa has described the nerve intermedius here as “running into a sulcus” formed by the components of the CN VIII, as “in a friendly embrace” (7) D. The left VII-VIII nerve complex is followed across the cerebellopontine cistern and is seen entering the internal acoustic meatus. As the posterior wall of the meatus has been drilled, and its dural outline opened, the nerves can be followed up to the meatal fundus. The VIIb will run with the VIII along its entire course within the cerebellopontine cistern, only to join VIIa at the final part of its cisternal segment (as in this case) or sometimes as distal as the fundus of the meatus. The cranial nerves IX, X, and XI are seen at the cerebello-medullary cistern, en route to the jugular foramen. *AICA: Anterior Inferior Cerebellar. A.: Area; BM V: Brachial motor nucleus of the trigeminal nerve (masticatory muscle); BMVII: Brachial motor nucleus of the facial (VIIa) nerve, CN: Cranial Nerve; Coll.: Colliculus, Colliculi; Em.: Eminence; Hypog.: Hypoglossal; Lat.: Lateral, Med.: Medulla, Medullary; PICA: Posterior Inferior Cerebellar Artery; PM VIIb: Parasympathetic motor nucleus of nerve intermedius or superior salivatory nucleus, PM IX: Parasympathetic motor nucleus of glossopharyngeal nerve or inferior salivatory nucleus. PM X: Parasympathetic motor nucleus of vagus nerve or dorsal nucleus of vagus; SM IV: Somatic motor nucleus of abducens nerve; SM XII: Somatic motor nucleus of hypoglossal nerve. S.: Sulcus, Sulci; Sup.: Superior; Tr. Triangle.*

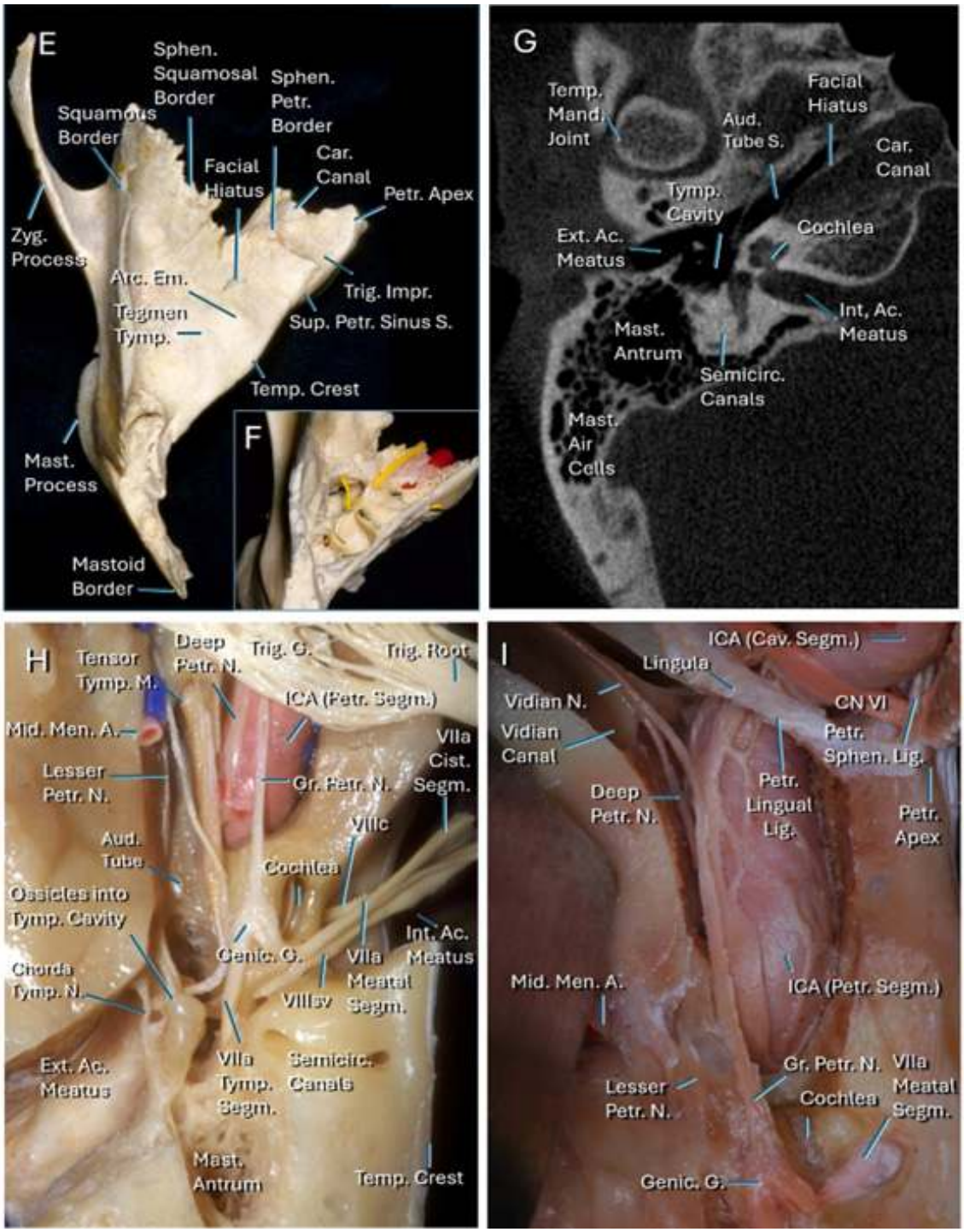
E
Sphen. Squamosal Border
Sphen. Petr. Border
Squamous Border
Facial Hiatus
Car. Canal
Petr. Apex
Zyg. Process
Arc. Em.
Tegmen Tymp.
Trig. Impr.
Sup. Petr. Sinus S.
Temp. Crest
Mast. Process
Mastoid Border
F
G
Temp. Mand. Joint
Aud. Tube S.
Facial Hiatus
Car. Canal
Tymp. Cavity
Cochlea
Ext. Ac. Meatus
Int, Ac. Meatus
Mast. Antrum
Semicirc. Canals
Mast. Air Cells
H
Tensor Tymp. M.
Deep Petr. N.
Trig. G.
Trig. Root
ICA (Petr. Segm.)
Mid. Men. A.
VIIa Cist. Segm.
Lesser Petr. N.
Gr. Petr. N.
VIIIc
Aud. Tube
Cochlea
Ossicles into Tymp. Cavity
Int. Ac. Meatus
Genic. G.
VIIa Meatal Segm.
Chorda Tymp. N.
VIIIsv
Ext. Ac. Meatus
VIIa Tymp. Segm.
Semicirc. Canals
Mast. Antrum
Temp. Crest
I
ICA (Cav. Segm.)
Lingula
Vidian N.
Vidian Canal
CN VI
Petr. Sphen. Lig.
Deep Petr. N.
Petr. Lingual Lig.
Petr. Apex
Mid. Men. A.
ICA (Petr. Segm.)
Gr. Petr. N.
VIIa Meatal Segm.
Lesser Petr. N.
Cochlea
Genic. G.

E. The anterior surface of the temporal bone extends from the sphenosquamosal and sphenopetrosal borders, anteriorly, to the temporal crest, posteriorly. By articulating with the greater sphenoidal wing, the anterior surface of the temporal bone completes the posterior part of the middle fossa. The temporal crest, giving attachment to the tent and bearing a sulcus for the superior petrosal sinus, separates the anterior from the posterior surfaces of the temporal bone. The posterior surface of the temporal bone in turn, forms the lateral part of the anterior wall of the posterior fossa and is pierced by the internal acoustic meatus. At the anterior surface of the adult temporal bone, four out of the five parts of this bone are exposed. These four parts can be easily seen by projecting posteriorly a line that starts at the facial hiatus, a marked groove, for the greater petrosal nerve. The arcuate eminence is crossed by this projecting line (8). Medial to the projection line is the petrosal part of the temporal bone - extending medially, up to the petrous apex. Laterally to the line are - from anterior to posterior - the squamosal, tympanic and mastoid parts of the temporal bone. F. Understanding the anterior surface of the temporal bone is helpful in mastering its internal architecture. In the lab, this has traditionally been taught by drilling the anterior surface of the temporal bone and substituting the inner structures by colored elements (8). The petrous carotid artery (horizontal segment) is represented in red. It runs into the carotid canal located in a level inferior to the floor of the middle fossa, in close relation to the trigeminal impression - a depression on the anterior surface, close to the petrous apex (E), were the trigeminal ganglion sits. The CN VII is represented in yellow. It can be seen a) entering the internal acoustic meatus at the posterior surface of the temporal bone, b) running along the facial hiatus - as the greater petrosal nerve; c) passing above the tympanic cavity - just under the tegmen tympani, as the chorda tympani nerve; and d) veering dowward, as the mastoid part of CNVII. The cochlea is located at the angle between the facial hiatus and the roof the internal acoustic canal (the cochlear part of the CN VIII has been represented in black), while the arcuate eminence signals the position of the superior semicircular canal within the temporal bone (the vestibular parts of the CN VIII have been represented in green). G. and H. Another form of integrating this anatomy is studying axial tomographic cuts (G) and dissecting the area in injected cadaveric heads (H). H. The anterior surface of the temporal bone on the left side of an injected specimen has been drilled to expose the inner structures of the temporal bone of interest to understand the circuit of tears and the CN VIIb. Once the roof of the internal acoustic meatus is removed the nerve intermedius can be seen leaving the CN VIII to join the CN VII. Notice that the internal acoustic meatus has an inclination, ascending from its porus, at the posterior surface of the temporal bone, towards the floor of the middle fossa and the anterior surface of the temporal bone. This inclination allows for the internal genu of the CN VII and the geniculate ganglion to lie just below the bony surface and being exposed just under the dura. From the geniculate ganglion the fibers arising from the superior salivatory nucleus veer anteriorly, coursing along the facial hiatus, passing parallel and slightly superior to the carotid canal and the horizontal petrous carotid. I. The area between the internal acoustic meatus and the petrous apex has been dissected in another specimen. The lateralmost part of the meatal dura has been exposed and the meatal segment of the CN VII is seen through it. The geniculate ganglion is naturally exposed at the floor of the middle fossa. The fibers forming the greater petrosal nerve are medial to the lesser petrosal nerve (from CN IX) and the grooves for the auditory tube and tensor tympani muscle. The parasympathetic fibers at the greater petrosal nerve join the deep petrosal nerve (from the sympathetic carotid plexus) to form the vidian nerve (or the nerve of the pterygoid canal), which runs into the sphenoid bone, passing through the pterygoid or vidian canal (unroofed here). The trigeminal ganglion and root have been removed from the trigeminal impression, exposing the petrous apex. From the petrous apex a series of ligaments arise. The petrolingual ligament extends from the petrous apex to the lingula of the sphenoid. This ligament marks the caudal limit of the cavernous sinus. Medial to it, the vertical part of the cavernous carotid and the CN VI are seen. The petrous apex also gives attachment to the petrosphenoidal ligament (not to be confused with the petroclinoid fold or anterior attachment of the tent, which is superficial in this area). The petrosphenoidal ligament, also called Gruber's ligament, forms the roof of Dorello's canal, through which the CN VI enters the posterior wall of the cavernous sinus. *A.: Artery; Ac.: Acoustic; Arc.: Arcuate; Aud.: Auditory; Cav.: Cavernous; Car.: Carotid; Cist.: Cistern, Cisternal; Em.: Eminence; Ext.: External; G.: Ganglion; Genic.: Geniculate; Gr.: Greater; ICA: Internal Carotid Artery; Imp.: Impression; Int.: Internal; Lig.: Ligament; M.: Muscle; Mand.: Mandibula, Mandibular; Mast.: Mastoid; Men.: Meningeal; Mid.: Middle; N.: Nerve; Petr.: Petrous, Petrosal; S.: Sulcus; Segm.: Segment; Semicir.: Semicircular; Sup.: Superior; Temp.: Temporal; Tymp.: Tympani, Tympanic; Trig.: Trigeminal; VIIIc: Vestibulocochlear nerve (Cochlear part); VIIIsc: Vestibulocochlear nerve (Superior vestibular part); Zyg.: Zygomatic*

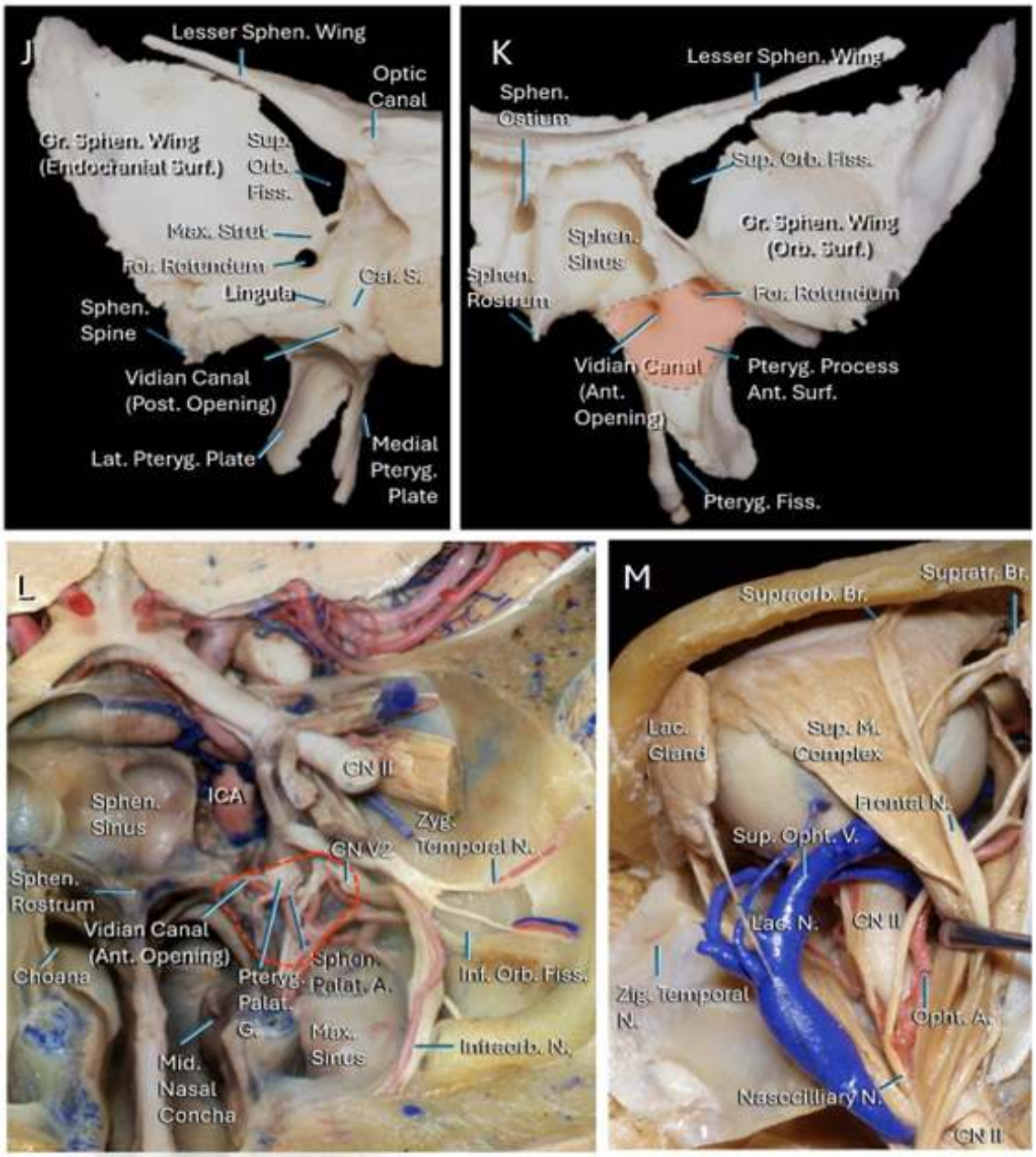
J
Lesser Sphen. Wing
Optic Canal
Gr. Sphen. Wing (Endocranial Surf.)
Sup. Orb. Fiss.
Max. Strut
For. Rotundum
Lingula
Cav. S.
Sphen. Spine
Vidian Canal (Post. Opening)
Lat. Pteryg. Plate
Medial Pteryg. Plate
K
Lesser Sphen. Wing
Sphen. Ostium
Sup. Orb. Fiss.
Sphen. Sinus
Gr. Sphen. Wing (Orb. Surf.)
Sphen. Rostrum
For. Rotundum
Vidian Canal (Ant. Opening)
Pteryg. Process Ant. Surf.
Pteryg. Fiss.
L
CN II
Sphen. Sinus
ICA
Zyg. Temporal N.
CN V2
Sphen. Rostrum
Vidian Canal (Ant. Opening)
Choana
Pteryg. Palat. G.
Sphen. Palat. A.
Inf. Orb. Fiss.
Max. Sinus
Infraorb. N.
Mid. Nasal Concha
M
Supratr. Br.
Supraorb. Br.
Lac. Gland
Sup. M. Complex
Frontal N.
Sup. Opht. V.
Lac. N.
CN II
Zyg. Temporal N.
Opht. A.
Nasociliary N.
CN II

J and K. The vidian (or petrosal) canal crosses the sphenoid bone at the region where the pterygoid process fuses with the body of the sphenoid, on each side. J. A posterior view of the left side of the sphenoid bone exposes the posterior opening of the vidian canal. In contrast to the foramen rotundum that opens at endocranial side of the bone, the posterior opening of the vidian canal opens at a lower level, below the lingula, at the base of the carotid sulcus (which runs along the lateral side of body of the sphenoid) and at the anterior lip (or sphenoidal contribution) to the foramen lacerum. K. Anterior surface of the left side of the sphenoid bone. The anterior opening of the vidian canal is located at the anterior surface of the pterygoid process of the sphenoid bone, just medial to the exocranial opening of foramen rotundum and just under the floor of the sphenoid sinus. The anterior surface of the pterygoid process forms the posterior wall of the pterygopalatine fossa (orange shaded area). L. The anterior fossa, the nasal cavity and sphenoid sinus, as well as the left orbit and maxillary sinus have been dissected to expose the left cavernous carotid, the vidian canal and the pterygopalatine fossa. The highlighted orange area corresponds to the area seen in J and marks the posterior wall of the pterygopalatine fossa. The vidian nerve is seen coursing along the unroofed vidian canal, on the floor of the sphenoid sinus, to open at the pterygopalatine fossa. The pterygopalatine ganglion is housed within this space. It receives the vidian nerve, whose parasympathetic fibers synapse here. Such fibers will then run with the zygomatic branch of the maxillary division of the trigeminal nerve (CN V2), that reaches the pterygopalatine fossa through the foramen rotundum. The zygomatic nerve arises lateral to the infraorbital nerve and while this one runs along the floor of the orbit, the zygomatic nerve runs along its lateral wall, where it divides into zygomaticotemporal and zygomaticofacial branches. The distalmost part of such nerves, which eventually leave the orbit, emerge at the temporal and malar areas to be responsible for collecting sensory supply from these regions. M. The left orbit has been unroofed and the periorbit reflected to expose the path of the zygomaticotemporal branches of the maxillary division. These branches carry the post ganglionic parasympathetic fibers to the lacrimal gland. Such fibers will join the lacrimal nerve of the ophthalmic division of the trigeminal nerve (CN V1) to pass into the lacrimal gland. A.: Artery; Ant.: Anterior; Br.: Branch; Car.: Carotid; CN: Cranial Nerve; Fiss.: Fissure; For.: Foramen; G.: Ganglion; Gr.: Greater; Inf.: Inferior; ICA: Internal Carotid Artery; Lac.: Lacrimal; Lat.: Lateral; M.: Muscle, Muscular; Max.: Maxilla, Maxillary; Mid.: Middle; N.: Nerve; Opht.: Ophthalmic; Orb.: Orbital; Palat.: Palatine; Post.: Posterior; Pteryg.: Pterygoid, Pterygoidal; S.: Sulcus; Sphen.: Spheno, Sphenoid, Sphenoidal; Sup.: Superior; Supratr.: Supratrochlear; Surf.: Surface; Temp.: Temporal; V.: Vein, Venous; Zyg.: Zygomatic

From this point, the fibers traverse the cerebellopontine cistern (cisternal segment) (Figure 1D), in most cases cruising with the VIII to reach the VIIa either along the cistern or into the meatal segment. Because in around 22% of specimens the VIIb will only reach the VIIa into the meatus (9) no nerve can be devised in the cistern. In the other cases, a complex arrangement of fibers ranging from one to more than four rootlets have been described (9–11).This feature is well-known for over 150 years (11), but has recently been demonstrated through MRI (12) and intraoperative stimulation (13) – attesting for the technological advances that have allowed specific study of the VIIb. On top of this is the recent demonstration of the intermedius' Obersteiner-Redlich zone (ORZ) or glial-Schwann cell junction. This area, which marks the transition between the central and peripheral myelin is a zone of susceptibility for neurovascular conflicts and implied in clinical findings for a long time (14). With these data, it appears that the nervus intermedius' ORZ is shorter and closer to the brain stem when compared with other cranial nerves(15) and may vary in location pending its point of detachment from the VIII, a fact that calls for further individualization of the understanding of the anatomical arrangement of this nerve.

At the internal meatal fundus, the VIIb passes with the VIIa to the geniculate ganglion or external knee (Figure 1 H-I) (to differentiate from the inner knee, which is the abrupt turn the VIIa fibers perform around the abducens nucleus into the brainstem, and which forms the prominent facial colliculus at the rhomboid fossa) (Figure 1 B). It is at the geniculate ganglion that the 'tear circuit" diverge from the "salivatory circuit" fibers. While the first ones veer anteriorly, as the greater petrosal nerve and follow the facial hiatus, on the anterior surface of the temporal bone (Figure 1 D-G); the last ones cruise with the VIIa for a while longer, using its labyrinthine, tympanic and (part of) its mastoid segments, to then veer anteriorly, course above the tympanic membrane, along the roof of the tympanic cavity and leave the temporal bone through its anterior border, passing medial to the condylar fossa, through the petrotympanic fissure, as part of the chorda tympani nerve (Figure 1 F and H).

The "tear circuit" fibers, which are in itself parasympathetic components, will join the sympathetic twigs, originated in the superior cervical ganglion, which clustered at the surface of the petrous carotid and are called deep petrosal nerve (Figure 1 H-I). This fusion will occur within the carotid canal or further anteriorly to form the vidian nerve or nerve of pterygoid canal (Figure 1 H-I). The vidian nerve thus formed, enters the posterior opening of the (pterygoid) vidian canal, located at the sphenoidal lip of the foramen lacerum, and below the endocranial surface of the skull (Figure 1 I-L). This canal, which transverses the base of the sphenoidal body, opens anteriorly at the junction of the sphenoidal body and its pterygoid part, in a region forming the posterior wall of the pterygopalatine fossa. The parasympathetic fibers of the 'tear circuit" will synapse at the pterygopalatine ganglion (Figure 1 K-L). From there, they will cruise with the zygomatic branch of CN V2, and using its zygomaticotemporal nerve, will pass along the lateral wall of the orbit, to finally reach the lacrimal gland (Figure L-M).

Therefore, a clinical case involving the VIIb is presented, and evaluation of the temporal bone anatomy is required as a surrogate marker for the intratemporal portions of the nerve intermedius. This evaluation is guided by questions that will require investigation, review and application of anatomical knowledge.

## Case

For the last six month, a 36-year-old male has been having serious episodes of head pain. These episodes come in bouts of 3 to 5 episodes of high intensity pain a day, usually accompanied by nasal congestion, redness of the eyes and lacrimation. The series of episodes are spaced by weeks or months, only to recur in a series of bouts again. In previous episodes, relief has been obtained using oxygen inhalation and the medical team proposed the possible diagnosis of cluster headache. To rule out other possibilities, the patient is requested to perform a few tests, including neuroimaging studies. Among those is a CT tomography.

1. What is cluster headache?

2. What is it possible physiopathology?

3. To which cranial nerve are the accompanying signs possibly related?

3. Who is responsible for vascular supply and lacrimal secretion?

4. Why is a temporal bone study performed?

5. Please write down the names of the anatomical landmarks numbered.

6. Which of those anatomical landmarks is/are helpful in the study of the nerve intermedius?

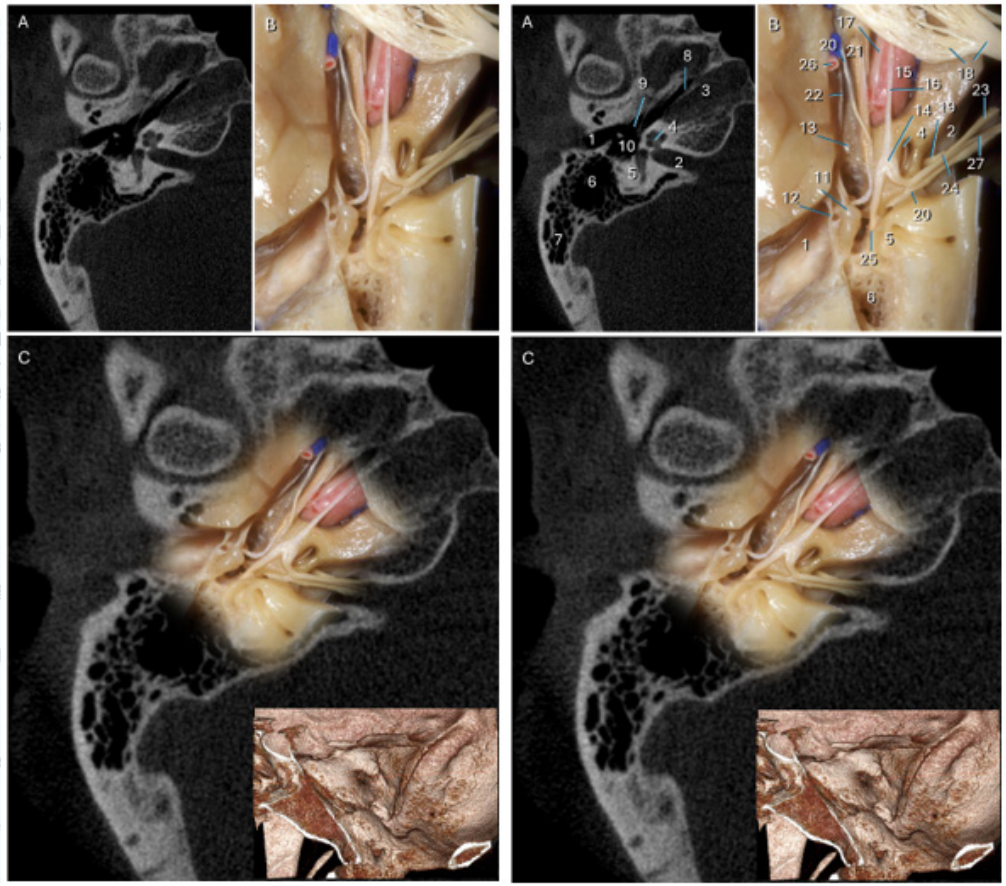


Figure 2. Blue box - illustrative clinical case. A. An axial CT tomogram of the temporal bone is presented. B. Temporal bone dissection in a vascular injected adult, cadaveric specimen, presenting the neural and vascular anatomy related to the temporal bone. C. A fusion has been made of the images previously presented, highlighting the surrogate role of the bone anatomy in locating and analysing the vascular and neural anatomy related to the temporal bone. Insert: the fine, red, axial line, displays the level of cut in the temporal bone. Labelled view figure 2. A. and B. Labelling help the participant/student to locate and identify the structures. C. After performing the exercise, a new degree of comprehension of the fused anatomy is likely to ensue. Didactically, this clinical case and the use of temporal bone anatomy as a surrogate marker for vascular and neural related structures neatly follows the flow of information facing students during the first and second semesters of the anatomical curriculum within the medical course. By working through this case students may reach yet another soft skill - establishing the ever-growing, gradually enriching character of anatomical knowledge. *1. External acoustic meatus, 2. Internal acoustic meatus, 3. Carotid canal, 4. Cochlea, 5. Semicircular canals, 6. Mastoid antrum, 7. Mastoid air cells, 8. Facial hiatus, 9. Sulcus for auditory tube, 10. Tympanic cavity, 11. Ossicles into tympanic cavity, 12. Chorda tympani nerve, 13. Auditory tube (unroofed), 14. Geniculate ganglion, 15. Petrous carotid (horizontal segment), 16. Greater petrosal nerve, 17. Deep petrosal nerve, 18. Trigeminal ganglion and root (lodged at the trigeminal impression on the anterior surface of the temporal bone), 19. Cochlear nerve (VIIIc), 20. Superior vestibular nerve (VIIIsv), 21. Tensor tympani muscle, 22. Lesser petrosal nerve (from tympani plexus to otic ganglion), 23. Cisternal segment of facial nerve (VIIa), 24. Meatal segment of facial nerve (VIIa), 25. Tympanic segment of facial nerve (VIIa), 26. Middle Meningeal Artery. 27. Nerve Intermedius (VIIb).*

## Discussion

This study exemplifies the concept of clinically significant neuroanatomy using one segment of the VIIb. Although authors since Wrisberg (6,7,16) and Sommering (3,17,18) have debated if the intermedius (VIIb) is in itself a cranial nerve (6,9) or simply the sensory root of the facial nerve (VIIa) (6,16), in practice, the risk of alienating students away from the effort to study and understand the anatomy and functions of these fibers – as they do to other cranial nerves – might impede or delay future professionals in their ability to identify symptoms associated with them and further refine diagnostic and therapeutic measures that may be of help to patients. This seems reason enough to justify our choice in dealing with the nerve intermedius. Beyond the controversy on a given – arbitrary - number of nerves, that have varied in time as our ability and technology allowed us to understand them as functional units (6), we favor a grouping of nerves that prioritizes them as didactical modules bearing clinical significance.

To fulfill the aim in reaching clinically significant neuroanatomy, technology has proved helpful: it is noteworthy that early exposure to radiological cross-section images during introductory anatomy and dissection courses increases students' understanding of both radiology and anatomy (19), one of the reasons being for avoiding long lapses of time between anatomical and radiological educations. Besides, the clinical case scenarios are undoubtedly triggers of learning and are well-recognized in building internal motivation and potentiate confidence for future encounters with that anatomy, because of teaching-in-context (20).

In the long range of the neuroanatomical curriculum that spans the basics (starting at the beginning of graduation) to the very complex anatomy of postgraduation level, a veritable spiral curriculum (20) must be created. In a spiral curriculum, every new interaction with a given topic should add for confidence in the knowledge already grasped and allow for deeper understanding. Multi-layered instructional material, as presented here, can provide for meaningful bridges facilitating further acquisition of knowledge as well as knowledge transfer.

## Conclusion

Integration approaches that generate multimodal, self-directed learning opportunities make sense and may pave a more consequential understanding of the cranial nerve anatomy.

## References

1. Alasmari WA. Medical Students' Feedback of Applying the Virtual Dissection Table (Anatomage) in Learning Anatomy: A Cross-sectional Descriptive Study. Adv Med Educ Pract. 2021 Nov;Volume 12:1303–7. Doi: 10.2147/AMEP.S324520
2. Gray H, Collins P. Gray's Anatomy: The Anatomical Basis of Clinical Practice. 39th ed. Standring S, Harold E, Berkovitz BKB, editors. Elsevier Churchill Livingstone; 2005. 1627 p.
3. Porras-Gallo MI, Peña-Meliáan Á, Viejo F, Hernáandez T, Puelles E, Echevarria D, et al. Overview of the History of the Cranial Nerves: From Galen to the 21st Century. Anat Rec. 2019 Mar 9;302(3):381–93. Doi: 10.1002/ar.23928
4. Martins C, Martins A, Monteiro C, Tenório D, Lima D. A Fábrica do Corpo: O Sulco Limitante. 2023. [Internet]. Spotify: FPS Podcast; 2023 Oct [cited 2024 May 29]. Available from: https://podcasters.spotify.com/pod/show/fps-podcast/episodes/A-Fbrica-do-Corpo-01--Sulco-Limitante-e2baj6u
5. Puelles L, Tvrdik P, Martínez-de-la-torre M. The Postmigratory Alar Topography of Visceral Cranial Nerve Efferents Challenges the Classical Model of Hindbrain Columns. Anat Rec. 2019 Mar 2;302(3):485–504. Doi: 10.1002/ar.23830
6. Alfieri A, Strauss C, Prell J, Peschke E. History of the nervus intermedius of Wrisberg. Annals of Anatomy - Anatomischer Anzeiger. 2010 May;192(3):139–44. Doi: 10.1016/j.aanat.2010.02.004
7. Alfieri A, Fleischhammer J, Prell J. The Functions of the Nervus Intermedius. American Journal of Neuroradiology. 2011 Aug;32(7):E144–E144. Doi: 10.3174/ajnr.A2624
8. Martins C, Campero Á, Yasuda A, Valença M, Rhoton Jr. AL. Eminência arqueada. Relações topográficas e importância cirúrgica. JornalBrasileirodeNeurocirurgia. 2004;15(1):11–6.
9. Rhoton AL, Kobayashi S, Hollinshead WH. Nervus Intermedius. J Neurosurg. 1968 Dec;29(6):609–18. Doi: 10.3171/jns.1968.29.6.0609
10. Sachs E. The Role of the Nervus Intermedius in Facial Neuralgia. J Neurosurg. 1968 Jan;28(1):54–60. Doi: 10.3171/jns.1968.28.1.0054
11. Bischoff EPE. Mikroskopische Analyse der Anastomosen der Kopfnerven [Internet]. Munchen; 1865 [cited 2024 Sep 1]. Available from: https://wellcomecollection.org/works/vftsqcxj
12. Burmeister HP, Baltzer PA, Dietzel M, Krumbein I, Bitter T, Schrott-Fischer A, et al. Identification of the Nervus Intermedius Using 3T MR Imaging. American Journal of Neuroradiology. 2011 Mar;32(3):460–4. Doi: 10.3174/ajnr.A2338
13. Scheller C, Rachinger J, Prell J, Kornhuber M, Strauss C. Schwannoma of the intermediate nerve. J Neurosurg. 2008 Jul;109(1):144–8. Doi: 10.3171/JNS/2008/109/7/0144
14. Møller A. Vascular compression of cranial nerves. I. History of the microvascular decompression operation. Neurol Res. 1998 Dec 20;20(8):727–31. Doi: 10.1080/01616412.1998.11740591
15. Alfieri A, Fleischhammer J, Strauss C, Peschke E. The central myelin–peripheral myelin transitional zone of the nervus intermedius and its implications for microsurgery in the cerebellopontine angle. Clinical Anatomy. 2012 Oct 20;25(7):882–8. Doi: 10.1002/ca.22025
16. Tubbs RS, Steck DT, Mortazavi MM, Cohen-Gadol AA. The Nervus Intermedius: A Review of Its Anatomy, Function, Pathology, and Role in Neurosurgery. World Neurosurg. 2013 May;79(5–6):763–7. Doi: 10.1016/j.wneu.2012.03.023
17. Storey CE. Then there were 12: The illustrated cranial nerves from Vesalius to Soemmerring. J Hist Neurosci. 2022 Jul 3;31(2–

3):262–78. Doi: 10.1080/0964704X.2022.2033077

18. Hildebrand R. Soemmerring's work on the nervous system: a view on brain structure and function from the late eighteenth century. Anat Embryol (Berl). 2005 Dec 5;210(5–6):337–42. Doi: 10.1007/s00429-005-0027-3
19. Bork F, Stratmann L, Enssle S, Eck U, Navab N, Waschke J, et al. The Benefits of an Augmented Reality Magic Mirror System for Integrated Radiology Teaching in Gross Anatomy. Anat Sci Educ. 2019 Nov 19;12(6):585–98. Doi: 10.1002/ase.1864
20. Bergman EM, de Bruin AB, Herrler A, Verheijen IW, Scherpbier AJ, van der Vleuten CP. Students' perceptions of anatomy across the undergraduate problem-based learning medical curriculum: a phenomenographical study. BMC Med Educ. 2013 Dec 19;13(1):152. Doi: 10.1186/1472-6920-13-152

Carolina Martins
https://orcid.org/0000-0002-0197-3520
João Gonçalves da Silva
https://orcid.org/0009-0008-2798-0471
Leíla Ferraz
https://orcid.org/0009-0009-6132-7297
Maysa Matos
https://orcid.org/0009-0002-7961-4226
Maria Clara S. Moreira
https://orcid.org/0009-0002-0692-5568
Antonio Cavalcanti de A. Martins
https://orcid.org/0000-0002-1249-8622

**Authors Contributions**: CM, JGS, LF, MM, MCSM, ACAM: Acquisition, analysis, or interpretation of data for the work. CM, ACAM: Substantial contributions to the conception or design of the work reviewing it critically for important intellectual content, final approval of the version to be published.

**Conflict of interest**: There is no conflict of interest.

**Funding**: There was no funding.