Neurological Surgery and Anatomy 2024, 1(2): 45-47, e-ISSN: 2966-0696
DOI: 10.37085/nsa.2024.11

A Technical Note

Longitudinal slit in the distal portion of the abdominal catheter: a technique to minimize obstructions or malfunction in ventriculoperitoneal shunts

Marcelo Moraes Valença[1], Marcelo Andrade Valença[2], Martina Falcão Valença[3], Alex Caetano de Barros[1]

[1]Federal University of Pernambuco, Recife, Pernambuco, Brazil
[2]Hospital da Restauração, Recife, Pernambuco, Brazil
[3]Städtisches Klinikum Dresden, Dresden, Germany

Introduction
One of the primary reasons for ventriculoperitoneal (VP) shunt failure related to the abdominal catheter is the formation of a pseudocyst due to intraperitoneal septations. Often, it is not merely a blockage but an encasement of the catheter's tip within a closed cavity that restricts the absorption of cerebrospinal fluid (CSF), leading to pseudocyst formation. Such accumulation increases pressure, potentially exceeding the valve's threshold and causing valve malfunction, which can result in the recurrence of hydrocephalus and neurological symptoms.
Objective
This paper revisits the historical development of a technique pioneered by neurosurgeon Alex Caetano de Barros, which aims to reduce failures in ventriculoperitoneal shunts.
Technique
The procedure involves making one or two longitudinal incisions of approximately 3 cm each on the abdominal catheter before insertion into the peritoneal cavity, positioned 15 cm and 10 cm from the catheter's distal end. Incisions are made on only one side of the catheter. Surgeons must be cautious when handling the catheter to avoid accidents with the scalpel.
Conclusion
This simple technique can enhance the performance of VP shunts by potentially preventing complications due to obstruction at the distal end of the catheter, thereby facilitating better CSF flow and reducing the risk of shunt failure.

Keywords
Ventriculoperitoneal shunt, Pseudocyst, Cerebrospinal fluid, Shunt failure, Neurosurgery, History of Medicine.

Edited by:
Carolina Martins

Marcelo Moraes Valença
mmvalenca@yahoo.com.br

Submitted: August 20, 2024
Accepted: August 27, 2024
Published online: 29 August, 2024

© Copyright 2024

Introduction

One of the leading causes of ventriculoperitoneal (VP) shunt failure due to problems with the abdominal catheter is the formation of a pseudocyst due to intraperitoneal septations (1-5). In fact, it is not always a blockage of the catheter, but rather an encasement of the catheter's tip in a closed cavity that does not allow sufficient absorption of the released cerebrospinal fluid (CSF), forming a pseudocyst. With the accumulation of CSF and lack of absorption in this pseudocyst, there is an increase in pressure to the point of exceeding the valve's opening pressure (6), causing valve malfunction, reemergence of hydrocephalus, and return of neurological signs.

Some VP shunt complications may be classified as "nonfunctional abdominal complications of the distal catheter" (5) because the VP shunt appears operational when the surgeon externalizes the abdominal catheter and observes spontaneous CSF discharge.

Insights into failures of peritoneal dialysis associated with peritoneal membrane damage have enhanced the understanding of abdominal issues linked to VP shunt (7). There is a marked resemblance between the peritoneal absorption failures seen in both peritoneal dialysis and VP shunt, which stem from the compromised structural and functional integrity of the peritoneum. Typically, this membrane's mesothelium, a single layer of cells originating from the mesoderm, is an initial barrier against pathogens and harmful chemicals. It also produces various growth factors and inflammatory agents that contribute to tissue repair and stability. Its ultrastructure, featuring microvilli, enlarges the surface area for absorption, achieving rates between 0.5 ml/min and 1.5 ml/min through the lymphatic system (7). The peritoneum also secretes glycocalyx, which lends it non-adhesive qualities that reduce damage from friction, aiding the mobility of internal organs and enhancing the durability of a distal VP shunt catheter with minimal reaction. However, the mesothelial cells can become damaged and shed during inflammation or infection, revealing the submesothelial layer and initiating an inflammatory response. This can impede the regeneration of healthy mesothelial cells and lead to catheter dysfunction through fibrotic tissue development. Such conditions also diminish fluid absorption capabilities and perpetuate inflammation due to the ongoing release of inflammatory agents from the submesothelial tissue (5, 7). Consequently, these dynamics are critical contributors to ongoing VP shunt failure, primarily when the inflammation leads to fibrosis within the peritoneal cavity (5, 7).

In the context of peritoneal dialysis, the percentage of absorption through blood and lymphatic pathways from the interstitium quickly stabilizes (8). The intraperitoneal pressure influences this rate. Computer simulations indicate that 20 to 40% of the fluid entering the tissue from the peritoneal cavity is absorbed by the lymphatics within the tissue. The blood capillaries absorb a more significant portion (60 to 80%) (8). The peritoneal cavity has an absorption capacity of approximately 1.44 to 2.88 liters per 24 hours (8). While silicone elastomer is deemed inert and intended for long-term bodily implantation, CSF absorption likely occurs via the same pathways as normal peritoneal fluid, utilizing specialized structures known as stomata (5). The peritoneal fluid absorption predominantly occurs via the diaphragmatic lymphatics, particularly in the subdiaphragmatic area. Here, open intracellular channels, often referred to as "stomata," facilitate this process. These channels lead to the mediastinal lymphatics, situated before the right lymphatic duct, eventually connecting to the right internal jugular and subclavian veins (5).

In brief, regarding CSF absorption in the peritoneal cavity, an important interaction may exist between the silicone tubes of a VP shunt system and the CSF contents—mainly glucose and proteins—as well as the reactivity of the peritoneal membrane. This membrane can produce well-known immune mediators involved in the peritoneum's inflammatory reactions associated with foreign body responses (5).

This report revisits the historical development of a technique pioneered by neurosurgeon Alex Caetano de Barros, which aims to lower failures in ventriculoperitoneal shunts.

Origins and Evolution of the Technique

Since 1987, when I (MMV) began working with Professor Alex Caetano de Barros at the Federal University of Pernambuco, Recife, Brazil, I have routinely performed a longitudinal incision on the distal part of the abdominal catheter located in the intraperitoneal cavity of a VP shunt. When assisting Dr. Alex or one of his disciples, Claudio Leimig and Alfredo Costa, I observed them performing this procedure, claiming that the intention was to create additional exit points for CSF in case the single, distal orifice of the abdominal catheter became obstructed.

One of Dr. Alex's mentors during his residency in neurosurgery was the renowned Professor Bennett M Stein (February 2, 1931 - July 10, 2022), USA. I recently asked Dr. Alex whether he had learned this technique from another neurosurgeon or if it was his own innovation. He replied, 'It was my idea, regarding the distal obstructions, so to avoid or at least minimize these obstructions, I thought of this solution. It doesn't prevent them, but it significantly reduces them.

The technique involves making one or two longitudinal incisions of approximately 3 cm each in the abdominal catheter before placing it inside the peritoneal cavity. These incisions are located 15 cm and 10 cm, respectively, from the distal opening of the catheter. The cut is made on only one side of the catheter. Surgeons must exercise caution when holding the catheter with one hand, as using a number 11 scalpel blade for the incision could result in an accident if the surgeon's hand is positioned below the blade in case of a slip. Generally, the outflow of CSF is not observed with the catheter incision because the circum-

ferential design of the catheter closely approximates the edges. Once the original distal orifice of the catheter becomes obstructed, the CSF can be seen exiting through the proximal openings.

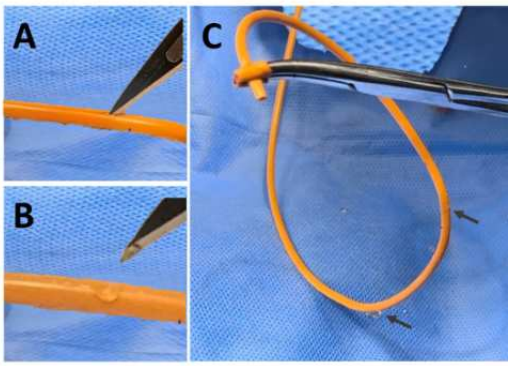

Figure 1. A and B: A longitudinal incision is made with a number 11 scalpel blade on a catheter already connected to a valve, which is also connected to a ventricular catheter. Note the spontaneous outflow of CSF from the opening made with the scalpel several centimeters before the final opening of the intraperitoneal catheter. C: With occlusion of the distal portion of the catheter to be implanted intraperitoneally, observe the spontaneous outflow of CSF from the two proximal openings in the catheter (arrows).

Comments

In 2021, Scollato and colleagues (9) described a similar technique. However, they performed 4-5 mm slits at every 4 cm of the abdominal catheter at multiple levels starting 6-8 cm from the insertion of the catheter into the peritoneum. They reported that in over 300 VP shunts, they found no cases of abdominal pseudocyst. Various factors that may predispose the formation of intrabdominal pseudocysts have been recognized, such as infection, numerous shunt revisions, previous abdominal surgeries, other than shunt revisions, and peritoneal reactions to foreign body rejection (6, 10). Yet, the fundamental pathophysiological mechanisms still need to be better understood (6).

The cyst is encased by a non-epithelial tissue wall, including elements like the intestinal serosa and peritoneum (6). Histological findings show inflamed serosal layers alongside fibrous tissue that hosts both acute and chronic inflammatory cells and granulomatous formations featuring fibroblasts, collagen, and inflammatory cells. It is theorized that the absence of an epithelial lining, combined with the presence of inflammatory cells, could impede the absorption of CSF (6).

The purpose of publishing this article is not only to disseminate the procedure to a broader audience of neurosurgeons but also to pay tribute to its creator, Professor Alex Caetano de Barros. I therefore refer to the procedure as the 'Alex Caetano longitudinal slit' when performed on the abdominal catheter in a VP shunt.

References

1. Shrestha N, Gautam N, Shrestha M. Abdominal pseudocyst complicating ventriculoperitoneal shunt: A rare indication for ventriculopleural shunt conversion. Clin Case Rep. 2023 Sep;11(9):e7902.
2. Yousaf MN, Naqvi HA, Kane S, Chaudhary FS, Hawksworth J, Nayar VV, et al. Cerebrospinal fluid liver pseudocyst: A bizarre long-term complication of ventriculoperitoneal shunt: A case report. World J Hepatol. 2023 May 27;15(5):715-24.
3. Achufusi TGO, Chebaya P, Rawlins S. Abdominal Cerebrospinal Fluid Pseudocyst as a Complication of Ventriculoperitoneal Shunt Placement. Cureus. 2020 Jul 23;12(7):e9363.
4. Habibi Z, Golpayegani M, Ashjaei B, Tayebi Meybodi K, Nejat F. Suprahepatic space as an alternative site for distal catheter insertion in pseudocyst-associated ventriculoperitoneal shunt malfunction. J Neurosurg Pediatr. 2020 May 15;26(3):247-54.
5. de Aquino HB, Carelli EF, Borges Neto AG, Pereira CU. Nonfunctional abdominal complications of the distal catheter on the treatment of hydrocephalus: an inflammatory hypothesis? Experience with six cases. Childs Nerv Syst. 2006 Oct;22(10):1225-30.
6. Hamid R, Baba AA, Bhat NA, Mufti G, Mir YA, Sajad W. Post ventriculoperitoneal shunt abdominal pseudocyst: Challenges posed in management. Asian J Neurosurg. 2017 Jan-Mar;12(1):13-6.
7. Ferreira Furtado LM, Da Costa Val Filho JA, Moreira Faleiro R, Lima Vieira JA, Dantas Dos Santos AK. Abdominal Complications Related to Ventriculoperitoneal Shunt Placement: A Comprehensive Review of Literature. Cureus. 2021 Feb 8;13(2):e13230.
8. Stachowska-Pietka J, Waniewski J, Flessner MF, Lindholm B. Distributed model of peritoneal fluid absorption. Am J Physiol Heart Circ Physiol. 2006 Oct;291(4):H1862-74.
9. Scollato A, Trungu S, Forcato S, Ricciardi L, Miscusi M, Gallina P, et al. Fenestration of Peritoneal Catheter to Avoid Abdominal Pseudocyst Formation after Ventriculoperitoneal Shunts: A Technical Note. J Neurol Surg A Cent Eur Neurosurg. 2021 Mar;82(2):166-8.
10. Mobley LW, 3rd, Doran SE, Hellbusch LC. Abdominal pseudocyst: predisposing factors and treatment algorithm. Pediatr Neurosurg. 2005 Mar-Apr;41(2):77-83.

Marcelo Moraes Valença
https://orcid.org/0000-0003-0678-3782
Marcelo Andrade Valença
https://orcid.org/0000-0002-0824-0928
Martina Falcão Valença
https://orcid.org/0000-0002-4085-3118

Contribution Authors: The same participation for all authors.
Conflict of interest: None
Funding: None