Neurological Surgery and Anatomy 2024, 1(2): 52-55, e-ISSN: 2966-0696
DOI: 10.37085/nsa.2024.13

Neurological Surgery and Anatomy

History of Medicine

Eponyms in Cerebrovascular Anatomy and Their Origins

Antonio Cavalcanti de Albuquerque Martins[1], Carolina Martins[1, 2], Florisvaldo J. M. Vasconcelos Jr[2], Gabriella R. D. Santos[2], Marcelo Moraes Valença[2]

[1]Medical School of Pernambuco, Recife, Pernambuco,Brazil
[2]Federal University of Pernambuco, Recife, Pernambuco, Brazil

Introdução
An anatomical eponym is a term generated from the name of the scientist who first discovered or described an anatomical structure. It is a way to bestow credit and give homage to the pioneer efforts which, from this point on, becomes engraved in Medical History.
Although the same structures have received alternative, more descriptive terms at the Anatomical Terminology1 - as a general, abiding rule to facilitate communication - eponyms are still widely used.
In vascular neuroanatomy there are four revered venous eponyms - all of them used daily in clinical practice - namely the veins of Galen, Rosenthal, Trolard and Labbé. To know these structures by their eponyms, as well as their corresponding names in the Anatomical Terminology, not only facilitates communication among health professionals but also preserves memory and keeps History alive.
This study presents the descriptive, microsurgical, and angiographic anatomy of four widely used venous eponyms in cerebrovascular anatomy, correlating each of them with its History and corresponding terms in Anatomical Terminology

Keywords
Anatomy, Eponyms, History of Medicine, Cerebral Veins

Edited by:
Juliana Ramos de Andrade

Antonio C de A Martins
antoniocavalcantideamartins@gmail.com

Submitted: May 28, 2024
Accepted: August 18, 2024
Published online: August 31, 2024

© Copyright 2024

Introduction

An anatomical eponym is a term generated from the name of the scientist who first discovered or described an anatomical structure. It is a way to bestow credit and give homage to the pioneer efforts which, from this point on, becomes engraved in Medical History.

Although the same structures have received alternative, more descriptive terms at the Anatomical Terminology1 - as a general, abiding rule to facilitate communication - eponyms are still widely used. In vascular neuroanatomy there are four revered venous eponyms, currently used in clinical practice. To know these structures by their eponyms, as well as their corresponding names in the Anatomical Terminology, not only facilitates communication among health professionals but also preserves memory and keeps history alive.

This study highlights a group of venous eponyms, used daily in vascular neurosurgery and neurointerventional radiology, and a little of the history behind each of them.

Objective

To present the descriptive, microsurgical, and angiographic anatomy of four widely used venous eponyms in cerebrovascular anatomy, correlating each of them with its history and corresponding terms in Anatomical Terminology.

Methodology

To achieve a concise but meaningful description of the four structures of interest, namely Veins of Galen, Trolard, Labbé and Rosenthal, corresponding silicone-injected cadaveric microneuroanatomical images(1,2) and selected angiographic images (with written permission from Banco de Imagens Clínicas(4) do Hospital Metropolitano Oeste Pelópidas Silveira IMIP/SES/SUS) were combined with a short description of these vessels (Figure 1).

A dedicated review of the literature was performed. Only articles dealing with historical details about those structure where included. Historical sources were used to complete or consolidate the data published in other areas of knowledge.

Results and Discussion

Figure on next page

Conclusion

The veins of Galen, Rosenthal, Trolard and Labbé are important anatomical structures in the deep and superficial venous systems.

The use of eponyms is a tradition that remains valid in the current days, particularly in the clinical setting.

Understanding the multiple, possible denominations as well as the microsurgical and angiographic anatomy of these four structures is paramount to young neurologists/neurosurgeons and researchers involved in this area and allows for effective communication within interdisciplinary teams.

Acknowledgement

The authors are grateful to Ms. Mariana Luiza de Acioly Rodrigues, RN, MSc, Head of the Clinical Images Databank at Hospital Metropolitano Oeste Pelópidas Silveira, for her guidance during the period of this study.

Anatomical Terminology	Microsurgical and Angiographic Anatomy	Descriptive Anatomy	History
Great Cerebral Vein Vein of Galen *Vena Magna Cerebri*	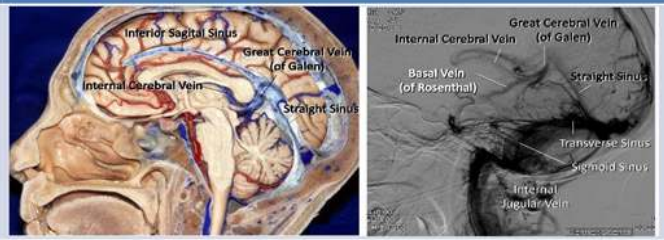	The deep venous system drains to the great cerebral vein, formed within the quadrigeminal cistern by the fusion of the internal cerebral and basal veins. The great cerebral vein opens into the straight sinus. This morphology is easily recognized on a profile, venous phase, cerebral angiography	Claudius Galenus (129-c.210) was born in Pergamon (Bergama, Turkey)[5]. Treating gladiators and soldiers from Emperor Marcus Aurelius' army, it was the patronage of roman elites that allowed for his studies[6]. His views on human anatomy were upheld by Hebrews, Christians and Muslims, up to the period when human anatomical dissections became a common practice.
Basal Vein Vein of Rosenthal *Vena Basalis*	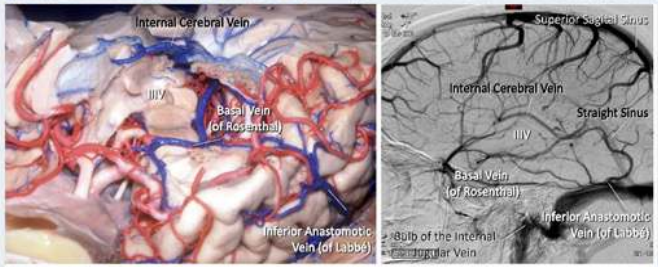	The basal vein arises at the anterior perforated substance by the union of the anterior cerebral and the deep middle cerebral vein. Contouring the brainstem along the cisterns within the incisural space, it initially veers posteriorly, towards the crural cistern, in the space between the uncus and the crus cerebri, just below the optic tract, to pass within the ambiens and quadrigeminal cisterns and open into the great cerebral vein.	Friedrich-Christian Rosenthal (1780-1829) was a German anatomist and e surgeon, born in Greifswald[7]. His registered anatomical contributions started in 1820, with the description of the cochlear modiolus. The basal vein description dates 1824 (*De intimis cerebri venis et de venae magnae Galeni rami*). After his death, unfinished treatises on cerebral anatomy and the cranial nerves were found[8].
Superior Anastomotic Vein Vein of Trolard *Vena Anastomotica Superior*	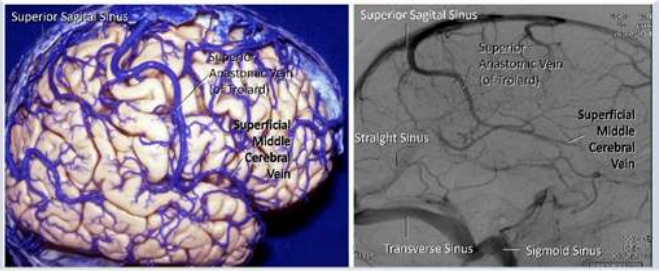	The superior anastomotic vein is the term reserved for the main channel connecting the superficial middle cerebral vein and the superior sagittal sinus. It is part of the superficial cerebral venous system at the lateral surface of the brain and usually the dominant anastomotic vein on the right hemispheres	Jean Baptiste Paulin Trolard (1842-1910) was a physician, professor, humanitarian, environmentalist, and French nationalist born in Sedan. He studied Medicine at Algiers Preparatory College of Medicine[9] and, in 1868 he defended his doctoral thesis in Paris, entitled "Research on the Anatomy of the Venous System of the Encephalon and Skull "[10]
Inferior Anastomotic Vein Vein of Labbé *Vena Anastomotica Inferior*	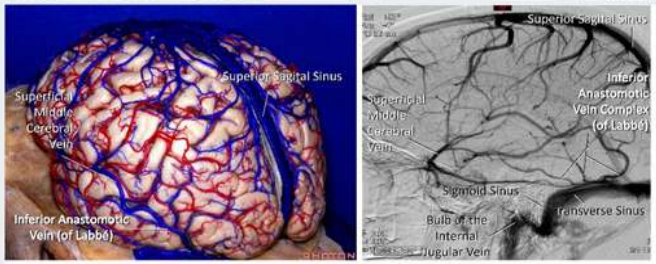	The inferior anastomotic vein is the term reserved for the main channel connecting the superficial middle cerebral vein and the transverse sinus. The inferior anastomotic vein can be comprised of a venous complex that opens at the transverse sinus at the level of the temporo-occipital notch (pre occipital incisura).	Charles Labbé (1851-89) was a French doctor, born in Normandy. He attended the *Université de Paris* from 1871-82[11]. In his original venous description, part of an article published in 1879, he described a greater and a small posterior anastomotic veins. The greater connected the superior sagittal to transverse sinus and the small, from superficial middle cerebral vein to transverse sinus. His early death cut short his writings and contributions.

Neurological Surgery and Anatomy

References

1. Federative Committee on Anatomical Terminology. Terminologia Anatomica Internacional. Ed. Manole, São Paulo. 2001.
2. Rhoton Collection - https://www.aans.org/education/The-Rhoton-Collection. Access Mar/2019
3. Rhoton Jr. AL. Cranial Anatomy and Surgical Approaches. Lippincott Williams and Wilkins. Schaumburg, Illinois. 2003
4. Banco de Imagens Clínicas – Hospital Metropolitano Oeste Pelópidas Silveira http://www1.hps.imip.org.br/cms/opencms/hps/pt/dep/0010.html. Access Mar/2019.
5. Bynum WF, Bynum H. Dictionary of Medical Biography. Vol I-V. Greenwood Press, London. 2007
6. Garrison FH. An Introduction to The History of Medicine. 4th Ed. WB Saunders Company, London. 1929.
7. Schmidt JE. Medical Discoveries. Who and when. Charles C Thomas Publisher. Springfield, Illinois. 1959.
8. Binder, Clusmann, Schaller. Friedrich-Christian Rosenthal: Surgeon and Anatomist. Neurosurgery, 2006. 59(6): 1328–1333. http://dx.doi.org/10.1227/01.NEU.0000245624.47474.C3
9. Loukas, Shea, Shea, Lutter-Hoppenheim, Zand, Tubbs, Cohen-Gadol. Jean Baptiste Paulin Trolard (1842–1910): His Life and Contributions to Neuroanatomy. Journal of Neurosurgery, 2010. 112(6), 1192–1196. https://doi.org/10.3171/2009.8.JNS09818
10. Tubbs RS, Shoja MM, Loukas M, Agutter P. History of Anatomy. An International Perspective. Willey Blackwell. 2019
11. Bartels, Overbeeke. Charles Labbé (1851-1889). Journal of Neurosurgery, 1997. 87: 477-480. 10.3171/jns.1997.87.3.0477

Antonio Cavalcanti de Albuquerque Martins
https://orcid.org/0000-0002-1249-8622
Carolina Martins
https://orcid.org/0000-0002-0197-3520
Marcelo Moraes Valença
https://orcid.org/0000-0003-0678-3782

Authors Contribution: ACAM, CM, GRDS: Data collection, organization of preliminary results. ACAM, CM, MMV: Substantial contributions to the conception of the work; reviewing it critically for important intellectual content, final approval of the version to be published, agreement to be accountable for all aspects of the work in ensuring that questions related to the accuracy or integrity of any part of the work are appropriately investigated and resolved.
Conflict of interest: There are no conflict of interest.
Funding: There was no funding.