Neurological Surgery and Anatomy 2024, 1(1): 15-21, e-ISSN: 2966-0696
DOI: 10.37085/nsa.2024.5

Original

Exploring the third ventricular floor anatomy: clinical insights for endoscopic third ventriculostomy

Carolina Martins[1], Luis Felipe Pohlmann Tabarelli[1], Alvaro Campero[2], Luiz Felipe Alencastro[3], Marcelo Moraes Valença[1], Hung Tzu Wen[4], Albert Rhoton[5†]

[1]Federal University of Pernambuco, Recife, Brazil
[2]Facultad de Medicina de la Universidad Nacional de Tucumán- Hospital Padilla, Tucuman, Argentina.
[3]Hospital Mãe de Deus, Porto Alegre, Brazil
[4]São Paulo University, São Paulo, Brazil
[5]Department of Neurosurgery, University of Florida, Gainesville
† *in memoriam*

Introduction
For the successful execution of an endoscopic third ventriculocisternostomy, a surgeon's reliance on the anatomical landmarks of the third ventricle's floor and the surrounding cisterns is paramount.
Objective
Our study explored the interrelationships among these critical structures to establish an anatomical classification for this region, aiming to enhance surgical precision and patient safety.
Methods
Sixty, silicone-injected, cadaveric heads were used. Measurements were taken at the level of third ventricular floor (Level 1) and at the cistern, at the level of the tentorial edge (Level 2), to classify the following: 1) the size of the pre-mammillary area, suitable for third ventriculostomy, into small, medium and large, 2) to determine whether the midbrain and optic chiasm are pre, normo or postfixed and 3) to classify the size of the angle between the third nerves in the cistern. Quartile analysis was used and correlation between structures was searched for.
Results
The size of the pre-mammillary area was small, (12.5%), medium (62.5%) and large (25%). Eight midbrains (19%) were prefixed, 24 (57.1%), midrange and 10 (23.8%) were considered postfixed. Eight chiasms were prefixed (20%), 26 (65%), normofixed and 6 (15%) postfixed. There was a tendency for an inverted correlation between the distance of the chiasm and tuberculum and the size of the pre-mamillary area: r=0.30 (p =0,276). An inverted relationship was found between the distance of the midbrain and dorsum and the size of the angle between the third nerves at the peduncle, r=-0.53 (p=0.001). As the distance between the dorsum and midbrain increased, the distance between the following: a) dorsum and basilar artery, r=0.79 (p<0.001), b) basilar artery-midbrain, r=0.64 (p<0,001), c) the size of the pre-mammillary area, r=0.65 (p=0.01) also increased. As the width of the tentorial edge increased, so did the distance between the third nerves, r=0.4 (p<0.05).
Conclusion
The position of the midbrain within the incisural space is the major determinant of the size of the area available for a safe third ventriculocisternostomy, at both, ventricular and cisternal levels. A large area should be expected if a) the chiasm is prefixed, b) the midbrain is postfixed. If a paramedian opening of the ventricular floor is anticipated, the position of the midbrain and the width of the tentorial notch determine the size of the available lateral safety zone. In performing a third ventriculocisternostomy, the pre-operative evaluation of these relationships may prove beneficial.

Keywords
Third ventricle, Basal cisterns, Third ventriculocisternostomy, Neuroendoscopy, Surgical anatomy

Edited by:
Juliana Ramos de Andrade

Carolina Martins
maria.cmlima@ufpe.br

Submitted: March 29, 2024
Accepted: April 23, 2024
Published Online: April 30, 2024

© Copyright 2024

Introduction

Third ventriculocisternostomy is one of the most widely used endoscopic procedures in neurosurgery. When appropriately indicated, this procedure effectively addresses hydrocephalus by facilitating an alternate pathway for cerebrospinal fluid circulation. This approach mitigates the necessity for extracranial diversion, reducing the risk of related complications.

A third ventriculocisternostomy's safe and successful performance depends on having well-distinguishable landmarks along the floor of the third ventricle and adjacent cisterns.

This study focuses on the relationships between the structures in the anterior incisural space that are involved in the performance of third ventriculostomy and in building a surgical classification of the anatomical variants, which might be useful in understanding the pathological changes imposed by disease.

Methods

In this study, we utilized sixty adult cadaveric heads, each fixed in formalin and injected with silicone. A Vernier caliper (±0.05 mm) and a goniometer (±5°) were used to conducted sixteen distinct sets of measurements, across two specific anatomical levels. In these specimens, as illustrated in Figure 1, Level 1 corresponds to the floor of the third ventricle, while Level 2 is defined by a plane intersecting the dorsum sellae, the third cranial nerves, and the posterior perforated substance (see Figure 1A for reference). The measurement points were systematically arranged to comprehensively scan both these levels, moving from anterior to posterior and laterally across each specimen. The number of specimens where each measurement was taken is stated.

At the ventricular level, the anteroposterior measurements extended along an axis starting at the tuberculum sellae, extending to the intermammillary sulcus. This measurement included the distances between a) the tuberculum sellae and the anterior edge of the optic chiasm, b) the optic chiasm and the anterior edge of the infundibular recess, c) the anteroposterior diameter of the infundibular recess itself, d) the posterior edge of the infundibular recess and a line marking the anterior limit of the mamillary bodies, and e) the anteroposterior diameter of the mamillary bodies themselves, as detailed in Figure 1B.

The cisternal measurements extended along the midline from the tuberculum sellae to the superior foramen cecum of the midbrain located at the midpoint of the pontomesencephalic sulcus. The distance along this line was divided into two parts: a) the distance between the dorsum sellae and the anterior surface of the basilar artery and b) the distance between the anterior surface of basilar artery and the midbrain (Fig. 1C).

The measurements taken at the cisternal level included the width of incisura in front of the basilar artery and the distance between the third nerves (in front of the basilar artery, at the midpoint of the distance between the dorsum and the basilar artery and at the dorsum sellae). The position of the third nerve was further characterized by measuring the angle between the medial surfaces of the third nerves at the superior foramen cecum and at the level of the aqueduct (Fig. 1D).

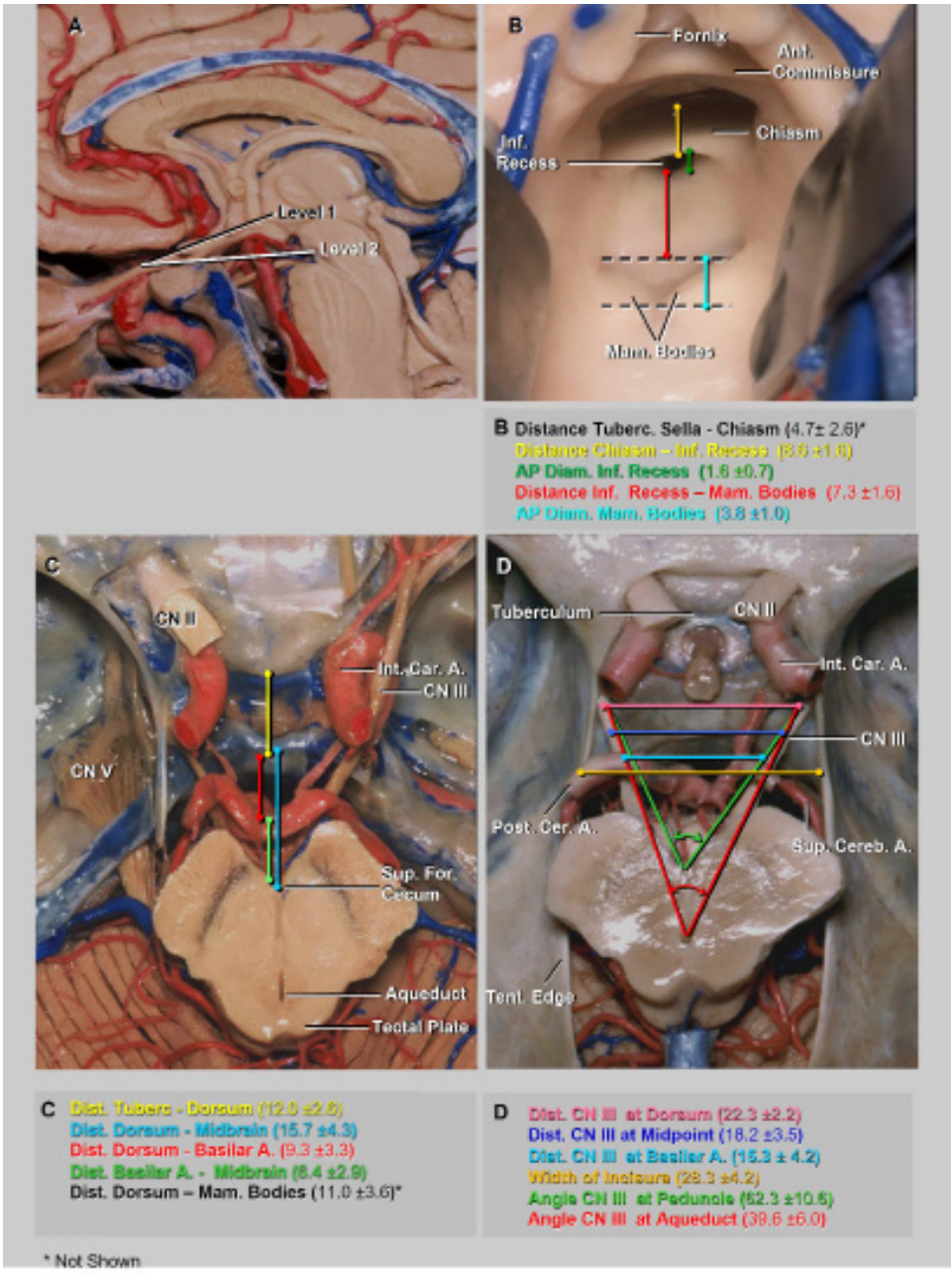

Figure 1. A. Sagittal view. Level 1 was coincident with the floor of the third ventricle. From anterior to posterior, it included the space between the tuberculum sellae and the intermammillary sulcus on the floor of the third ventricle. The third ventriculostomy area was defined on Level 1 as the rectangular-shaped area comprised between the lateral wall of the third ventricle and limited anteriorly by the posterior edge of the infundibular recess and posteriorly by a line connecting the anterior limits of the mamillary bodies. Level 2 was coincident with the anterior incisural space just below the floor of the third ventricle. On Level 2, the third ventriculostomy area approached the shape of a trapezoid figure. The sides were limited by the medial surfaces of the third nerves. The anterior limit was the dorsum/clivus and the posterior limit was the anterior surface of the basilar artery. The caudal limit of this area is the closest point between the basilar and clivus. B. Superior view along the floor of the third ventricle. The antero-posterior measurements were distributed along an axis that started on the tuberculum sellae at the anterior skull base and reached the intermammillary sulcus. It included the distance between the tuberculum sellae and the anterior border of the chiasm (not shown), the distance between the chiasm to the anterior border of the infundibular recess (yellow line), the antero-posterior diameter of the infundibular recess (green line), the distance from the posterior lip of the infundibular recess to a line connecting the anterior limit of the mamillary bodies (red line) and the antero-posterior diameter of the mamillary bodies (blue line). C. Superior view along the anterior incisural space, depicting the structures evaluated on Level 2. The anterior tentorial attachment has been preserved on the left. At Level 2, the characteristics analyzed included the distance between the tuberculum and dorsum sellae (yellow line) and the distance from the dorsum to the superior foramen cecum of midbrain (light blue line). The distance between dorsum sellae and midbrain was further subdivided according to the position of the basilar artery at this level into two segments: the distance between the dorsum sellae and anterior surface of basilar artery (red line) and distance between the anterior surface of basilar artery and midbrain (green line). These measurements helped construct a midline positioned, antero-posterior axis that extended from the tuberculum sellae to the superior foramen cecum of midbrain. D. Superior view along the anterior incisural space in another specimen. Latero-laterally the measurements taken at Level 2 included the width of the incisura in front of the basilar artery (yellow line), which was further subdivided according to the position of the midpoint of basilar artery tip into right and left halves and the distance between the third nerves, in front of the basilar artery (light blue line), at the midpoint of the distance between the dorsum and the basilar artery (dark blue line) and at the dorsum sellae (light pink line). The position of the third nerve was further characterized by measuring the angle between the medial surfaces of the third nerve at the superior foramen cecum (green angle) and at the level of the aqueduct (red angle). A third category of measurements related structures of interest on both levels and included the measurement of the distance between the posterior lip of the infundibular recess and a vertical plane projected from dorsum sellae and from this plane to the intermammillary sulcus.

A.: Artery; *Ant*.: Anterior; *AP*: Antero-Posterior; *Car*.: Carotid; *Cereb*.: Cerebellar; *CN*: Cranial Nerve; *Diam*.: Diameter; *Dist*.: Distance; *For*.: Foramen; *Inf*.: Infundibular; *Int*.: Internal; *Mam*.: Mammillary; *Sup*.: Superior; *Tent*.: Tentorial; *Tuberc*.: Tuberculum.

A third category of measurements included the distance between the posterior edge of the infundibular recess and a vertical plane projected from the dorsum sellae and from this plane to the intermammillary sulcus.

The area for the third ventriculostomy at the ventricular level may be delineated as a rectangular region based on its morphology. This area is bounded by the posterior edge of the infundibular recess, the mammillary bodies' anterior limit, and the third ventricle's lateral walls. At the cisternal level, the third ventriculostomy area had a trapezoid shape formed by the medial surfaces of the third nerves laterally, the dorsum/clivus anteriorly and the anterior surface of the basilar artery posteriorly. The caudal limit of this area is the closest point between the basilar and clivus.

A classification was conducted based on the distance between the tuberculum sellae and the anterior edge of the chiasm. Utilizing quartile analysis, the chiasm was categorized into prefixed (<3.0 mm), normofixed (3.0-7.0 mm), and postfixed (>7.0 mm) types. Also utilizing quartile analysis, the area corresponding to the pre-mammillary region was classified into three categories: short (<6.0 mm), midrange (6.0-8.74 mm), and long (>8.75 mm). Employing quartile analysis, we classified the clival-midbrain distance, indicative of the midbrain's position along the tentorial incisura, into three categories: prefixed (<12.0 mm), midrange (12.0-17.0 mm), and postfixed (>17.0 mm), as detailed in Table 1. The distance between a vertical plane projected from dorsum sellae and the intermammillary sulcus was classified into short (<8.0), midrange (8.0 -14), and long (>14), using the quartile analysis.

Table 1. Summary Data for Measurements along the Third Ventricular Floor and Anterior Tentorial Incisura

Value	Distance Tuberculum Chiasm (mm)	Distance Chiasm Infundibular Recess (mm)	AP Inf. Recess (mm)	Distance Infundibular Recess to Mammillary Bodies (mm)	AP Mammillary Bodies (mm)	Distance Tuberculum Dorsum Sellae (mm)	Distance Dorsum Midbrain (mm)	Distance Dorsum Basilar Artery (mm)	Distance Basilar Artery Midbrain (mm)	Width Incisura (mm)
n	40/60	28/60	25/60	16/60	19/60	53/60	42/60	41/60	42/60	37/60
Minimum	0	6.0	1.0	5.0	1.0	8.0	10.0	4.0	3.0	14.0
1st Quartile	3.0	7.0	1.0	6.0	3.0	10.0	12.0	7.0	4.7	27.0
Mean ± SD	4.7± 2.6	8.6 ±1.6	1.6 ±0.7	7.3 ±1.6	3.8 ±1.0	12.0 ±2.6	15.7 ±4.3	9.3 ±3.3	6.4 ±2.9	28.3 ±4.2
Median	4.0	9.0	1.0	7.0	4.0	12.0	15.0	9.0	6.0	28.0
3rd Quartile	7.0	9.7	2.0	8.7	4.0	14.0	17.2	11.0	8.0	31.0
Maximum	12.0	12.0	3.0	10.0	6.0	19.0	30.0	18.0	15.0	35.0

The statistical processing was made using Minitab 14 and Stata 9.2. Correlation was considered when values greater than 0.4 and less than -0.4 where present. Data are expressed as mean ± standard deviation. Statistical significance was considered at $p<0.05$.

Results

Ventricular Level (Tuberculum to Mammillary Bodies)

All measurements are listed on Tables 1-6

Table 2. Summary Data for Measurements along the Third Ventricular Floor and Anterior Tentorial Incisura

Value	Distance III CN at Basilar A. (mm)	Distance III CN at Midpoint (mm)	Distance III CN at Dorsum (mm)	Angle III CN at Peduncle (°)	Angle III CN Aqueduct (°)	Distance Dorsum Intermammillary Sulcus (mm)
n	28/60	27/60	44/60	37/60	37/60	14/60
Minimum	7.0	11.0	18.0	40.0	25.0	5.0
1st Quartile	12.2	16.0	21.0	55.0	35.0	8.0
Mean ± SD	15.3 ± 4.2	18.2 ± 3.5	22.3 ± 2.2	62.3 ± 10.6	39.6 ± 6.0	11.0 ± 3.6
Median	15.5	18.0	22.5	65.0	38.0	11.0
3rd Quartile	19.0	21.0	23.7	67.0	45.0	14.2
Maximum	25.0	27.0	27.0	85.0	50.0	17.0

Table 3. Classification According to Quartile Analysis

	Midbrain (Distance Dorsum-Midbrain) %	Chiasm (Distance Tuberculum-Chiasm) %
Short	19.0	20.0
Midrange	57.1	65
Long	23.8	15

Table 4. Classification According to Quartile Analysis

	Cisternal Area of Third Ventriculocisternostomy (Distance Dorsum-Basilar) %	Ventricular Area of Third Ventriculocisternostomy (Distance Infundibular Recess-Mammillary Bodies) %
Short	17.0	12.5
Midrange	58.5	62.5
Long	24.5	25.0

Table 5. Correlation between Structures on III Ventricular Floor and Anterior Incisural Space

Measurements	Distance Infundibular Recess-Mammillary Bodies	Distance Between III CN	Angle Between III CN (Peduncle)
Distance Tuberculum-Chiasm	-0.30 ($p<0.3$)	-	-
Distance Dorsum-Basilar	0.65 ($p<0.01$)	-	-
Notch Width	-	0.40 ($p<0.05$)	-
Angle III CN (Aqueduct)	-	0.42 ($p<0.05$)	0.60 ($p<0.001$)
Distance Dorsum-Midbrain	-	-	-0.53 ($p<0.001$)

Table 6. Classification of the Anatomical Variants Along the Anterior Incisural Space and III Ventricular Floor (%)

MIDBRAIN				
CHIASM	%	Prefixed	Normo positioned	Postfixed
	Prefixed	3.8	11.4	4.8
	Normofixed	12.9	36.3	15.4
	Postfixed	2.0	9.4	3.6

The distance between the tuberculum sellae and the anterior edge of the chiasm (n=40) ranged from 0 to 12 mm, average 4.7 ± 2.6 mm. Using the quartile analysis, the chiasm was classified into prefixed (< 3.0), normofixed (3.0-7.0) and postfixed (> 7.0) categories. Of these 40 studied, eight chiasms (20%) were prefixed, 26 (65%) were normofixed, and 6 (15%) were postfixed, as detailed in Tables 1 to 3.

In 16 specimens, we measured the distance from the posterior lip of the infundibular recess to a line connecting the anterior limit of the mammillary bodies. This distance ranged from 5 to 10 mm, with an average of 7.3 ± 1.6 mm. Utilizing quartile analysis, the pre-mammillary region was classified into three categories: 2/16 (12.5%) short, 10/16 (62.5%) midrange, and 4/16 (25%) long (Table 4). There was no statistical difference between the distance from the tuberculum to the chiasm and the distance from the infundibular recess to the mamillary bodies (r=0.301, p =0.276; Table 5).

Cisternal Level (Tuberculum to Midbrain)

The distance between the tuberculum and dorsum sellae was measured in 53 specimens, ranging from 8 to 19 mm, with an average of 12 ± 2.6 mm, as detailed in Table 1. Additionally, a correlation was observed between the distance from the tuberculum to the chiasm and the anteroposterior diameter of the sellae (r=0.58, p=0.001).

The distance from the dorsum to the superior foramen cecum of

the midbrain was determined in 42 specimens, ranging from 10 to 30 mm, with an average of 15.7 ± 4.3 mm. Of the 42 midbrains analyzed, eight (19%) were classified as prefixed, 24 (57.1%) as midrange, and 10 (23.8%) as postfixed, as detailed in Table 3. An inverted relationship was observed between the distance between the dorsum and the midbrain and the angle between the third nerves at the peduncle (r= -0.53, p=0.001; Table 5).

The distance between the dorsum sellae and the anterior surface of the basilar artery was determined in 41 specimens, ranging from 4.0 to 18.0 mm, with an average of 9.3 ± 3.3 mm. The distance between the anterior surface of the basilar artery and the midbrain was determined in 42 specimens, ranging from 3 to 15 mm, with an average of 6.4 ± 2.9 mm (Table 1).

There was a significant linear correlation between the distance from the dorsum to the midbrain and the distances from the dorsum-basilar artery (r=0.79, p<0.001) and basilar artery-midbrain (r=0.64, p<0.001). There was also a statistically significant, linear relationship between the dorsum-basilar artery distance and the length of the pre-mammillary area (r=0.65, p=0.010; Table 5).

The width of the tentorial incisura in front of the basilar artery (n=37) ranged from 14 to 35 mm, average 28.3 ± 4.2 mm (Table 1). This distance was further subdivided by measuring the distance between the midpoint at basilar tip to either side of the notch (n=33, left; n=36, right), characterizing the position of the basilar artery along incisura. The basilar tip ranged from 0 to 30 mm, average 13.9 ± 5.1 mm, from the notch on the left, and from 0 to 21 mm, average 14.1 ± 4.6 mm, on the right.

The distance between the third nerves in front of the basilar artery (n=28) ranged from 7 to 25 mm, average 15.3 ± 4.2 mm. At the midpoint between the dorsum and the basilar artery (n=27), this distance ranged from 11 to 27 mm, average 18.2 ± 3.5 mm; and at the dorsum sellae, the distance between the third nerves (n=44) ranged from 18 to 27 mm, average 22.3 ± 2.2 mm (Table 2).

There was a linear correlation between the width of the tentorial incisura in front of the basilar artery and the distance between the third nerves (r=0.4, p<0.05; Table 5).

The angle between the medial surfaces of the third nerve at the superior foramen cecum (n=37), ranged from 40 to 85°, average 62.3 ± 10.6°. At the level of the aqueduct, this angle (n=37), ranged from 25 to 50°, average 39.6 ± 6.0° (Table 2). These two measurements were related (r=0.6, p<0.001). We found an inverted correlation between the angle of the third nerves at the peduncle and the distance between the dorsum and midbrain (r= -0.5, p<0.01), as well as between the third nerves at aqueduct and the dorsum-mammillary bodies distance (r= 0.67, p=0.030).

The distance between a vertical plane projected from dorsum sellae and the intermammillary sulcus (n=14) ranged from 5 to 17 mm, average 11.0 ± 3.6 mm (Table 2). Using the quartile analysis, two (14.2%) were considered short, 9/14 (64.2%) were on midrange and 3/14 (21.4%) specimens were classified as long.

Discussion

The many dynamic factors involved in disease in the living patient limit the transposition of anatomical cadaveric study findings to the selection of the site for the third ventriculocisternostomy in clinical cases. However, relationships between anatomical structures, when identified, aid in predicting subgroups of patients in whom complications are likely. At the ventricular level, hydrocephalus may result in major changes in the distance between the infundibular recess and the pre-mammillary sulcus because this area is relatively unsupported and pliable, when compared to the fixed portions of the floor of the third ventricle: the chiasm, in front of the infundibular recess and above midbrain, behind the mammillary bodies (1,2,3).

It becomes important to understand preoperatively the anatomical features of this area, because the influence of hydrocephalus will be proportional to the size of the pre-mammillary area and the position of the fixed portions at the level of the chiasm and midbrain.

Comparative anatomical studies have indicated that the size and location of the optic chiasm are the major determinants of the size and location of the optic and infundibular recesses (4).

Rhoton's group(5,6) classified the chiasm into prefixed, normopositioned and postfixed. Our findings point towards a tendency for an inverted correlation between the size of the area between the chiasm and the tuberculum and the size of the pre-mammillary area. This relationship was such, that a prefixed chiasm would be the most favorable situation for a third ventriculocisternostomy, followed by the normopositioned and the postfixed chiasms. However, the number of observations was small and statistical significance could not be demonstrated.

Our findings also suggest that the antero-posterior size of the ventriculostomy area, both at the ventricular and cisternal levels seems to be directly dictated by distance between the dorsum/clivus and the upper brainstem and by the distance between the dorsum and the basilar artery. A strong, statistically significant, linear relationship between the dorsum-basilar artery distance and the length of the pre-mammillary area could be verified.

The width of the ventriculostomy area at cisternal level is determined by the distance between the third nerves, which depends on the width of the tentorial incisura in front of the basilar artery and is smaller the largest the distance between midbrain and dorsum. In this study, the distance between the third nerves in front of the basilar artery was as small as 7 mm, allowing for only a narrow zone for a paramedian ventricular floor opening. Based on our findings, if a paramedian opening is to be performed, a more anterior location along the pre-mamillary area should be chosen to avoid third nerve injury.

A compromise between the antero-posterior and latero-lateral diameters of the ventriculostomy area at cisternal level seem to exist, as an inverted relationship was found between the position of the midbrain and the angle between the third nerves at the peduncle. This finding is supported by the study of Adler et al. (7),

which analyzed the tentorial notch in one hundred human autopsy cases. These authors divided the position of the brainstem within the tentorial notch into prefixed (28%), postfixed (36%) and midpositioned (36%).

As previously stated, the correct placement of the fenestration in the floor of the third ventricle is of utmost importance in avoiding vascular and neural damage (8). A patient harboring a postfixed brainstem would have the largest antero-posterior ventriculostomy area, while the opposite would be true if the midbrain were prefixed. On the other hand, the postfixed midbrain patient would be at the greatest risk of neural and vascular damage by a paramedian opening of the floor of the third ventricle, while it would probably be safer if the midbrain was prefixed.

Patients having a postfixed chiasm and a prefixed midbrain would present the smallest areas for third ventriculocisternostomy at both the ventricular and the cisternal levels. In our sample, this configuration was seen in 2% of specimens (Table 6). On the other end of the spectrum, a patient having a postfixed brainstem and a prefixed chiasm would present the largest areas both on the floor of the third ventricle and inside the interpeduncular cistern, for the procedure. In our sample, this configuration was seen in 4.8% of specimens (Table 6).

Both the distance between the dorsum and the midbrain and the tuberculum sellae and chiasm can be measured on axial and sagittal magnetic resonance imaging, and this may help preview the individual configuration in a given surgical patient.

The knowledge of the anatomy involved in performing an endoscopic third ventriculostomy involves not only the capacity to recognize anatomical landmarks at the floor of the third ventricle but also the recognition of the topographical relationships of the ventricles and the skull, the anatomy of the lateral ventricles and area of foramen Monro, an understanding on the cavity of the third ventricle, the topography and variability of the vessels in the area, the embryological and phylogenetical steps that may alter the anatomical appearance of this area and the possible changes caused by disease.

Conclusion

The distances between the midbrain and dorsum sellae, at the level of the interpeduncular cistern and the tuberculum sellae and the chiasm, at the level of the floor of the third ventricle, are important in determining the size of the area for third ventriculocisternostomy.The position of the midbrain in the incisural space is the major determinant of the size of the area for the ventriculostomy, both on ventricular and cisternal levels. If a paramedian opening of the ventricular floor is anticipated, the position of the midbrain and the width of the tentorial notch help predict the available lateral safety zone.

Further studies confirming this relationship and the possible influential roles of neurosurgical lesions over these configurations are desirable.

References

1. Corrales M, Torrealba G. The third ventricle. Normal anatomy and changes in some pathological conditions. Neuroradiology. 1976;11(5):271-7.Doi 10.1007/bf00328385
2. Huber P, Rivoir R. The influence of intraventricular pressure on the size and shape of the anterior part of the third ventricle. Neuroradiology. 1973;5(1):33-6.Doi 10.1007/bf02464627
3. Rovira A, Capellades J, Grivé E, Poca MA, Pedraza S, Sahuquillo J, et al. Spontaneous ventriculostomy: report of three cases revealed by flow-sensitive phase-contrast cine MR imaging. AJNR Am J Neuroradiol. 1999;20(9):1647-52.
4. Kier EL, Kalra VB, Conlogue GJ, Filippi CG, Saluja S. Comparative anatomy of dissected optic lobes, optic ventricles, midbrain tectum, collicular ventricles, and aqueduct: evolutionary modifications as potential explanation for non-tumoral aqueductal anomalies in humans. Child's Nervous System. 2021;38(2):287-94.Doi 10.1007/s00381-021-05408-0
5. Rhoton AL, Jr. The sellar region. Neurosurgery. 2002;51(4 Suppl):S335-74.
6. Rhoton AL, Jr. The lateral and third ventricles. Neurosurgery. 2002;51(4 Suppl):S207-71.
7. Adler DE, Milhorat TH. The tentorial notch: anatomical variation, morphometric analysis, and classification in 100 human autopsy cases. Journal of Neurosurgery. 2002;96(6):1103-12.Doi 10.3171/jns.2002.96.6.1103
8. Schroeder HWS, Niendorf W-R, Gaab MR. Complications of 'endoscopic third ventriculostomy. Journal of Neurosurgery. 2002;96(6):1032-40.Doi 10.3171/jns.2002.96.6.1032

Carolina Martins
https://orcid.org/0000-0002-0197-3520
Luis Felipe Pohlmann Tabarelli
Alvaro Campero
https://orcid.org/0000-0001-5184-5052
Luiz Felipe Alencastro
https://orcid.org/0000-0002-1115-0157
Marcelo Moraes Valença
https://orcid.org/0000-0003-0678-3782
Albert Rhoton Jr.

Authors Contributions: CM, AC, LFA, LFPT: Acquisition, analysis, or interpretation of data for the work. CM, HTW, MV: Substantial contributions to the conception or design of the work. AC, HTW, MV: reviewing it critically for important intellectual content. CM, MV: Final approval of the version to be published.

Conflict of interest: The authors declare no conflict of interest

Funding: This research received no specific grant from any funding agency in the public, commercial, or not-for-profit sectors.